

Case Report



A 26-Year-Old Man With A Mediastinal Mass

Mahbub ahsan¹, Md Lutfar Rahman²,
A.S.M. Shariful Islam³, Prokash Chandra Munshi⁴.

Abstract

Mediastinal tumors are slow growing tumors of rare entity. They usually affect middle aged people ranging from 30-50 years. When they grow, may compress surrounding structures and produce symptoms such as cough, chest pain, chest tightness and respiratory distress. The most common anterior mediastinal masses are thymoma and lymphoma. Posterior mediastinal tumors are mainly neuroendocrine tumors. Diagnosis depends upon proper clinical history, X-ray chest, CT scan and if necessary CT guided FNAC. Sometimes hormonal tests such as -hCG and AFP may be needed for Germ cell tumors. Treatment is usually by wide surgical excision and biopsy followed by chemo or radiotherapy. Hodgkin's and Non-Hodgkin's Lymphoma are usually treated by chemotherapy. For proper management, widespread suspicion and diagnostic facilities should be available before the start of treatment.

Key words: FNAC, Thymic Carcinoma, Mediastinal Tumors.

Date of received: 03.04.2020.

KYAMC Journal.2020;11(3): 161-163.

Date of acceptance: 20.08.2020.

DOI: <https://doi.org/10.3329/kyamej.v11i3.49877>

Introduction

Mediastinal tumors are rare tumors. The most frequently affected people range from 30-50 years. In children, the posterior mediastinal masses are common such as ganglion cell neoplasm and paraganglion cell neoplasm. But there may be lymphadenopathy, neuroenteric cyst, vascular neoplasm and paravertebral abnormalities. In adults, most mediastinal tumors involve anterior mediastinum such as thymoma, lymphoma, and germ cell tumor. The tumors of the middle mediastinum are mainly pericardial cysts.

Case Report

A 26-year-old man admitted with the complaints of cough, chest pain and anorexia for 3 months. On examination, breath sound was diminished over the left side of the chest, trachea shifted to the right side. Chest X-ray revealed dense homogeneous opacity occupying whole left side of the chest

with shifting of the mediastinum to the right side (Figure 1).

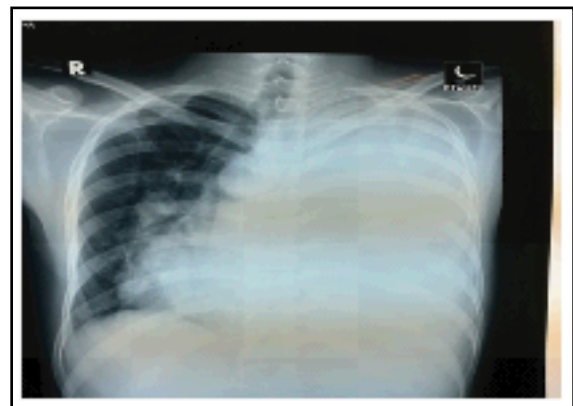

Figure 1: X-ray chest of the patient.

1. Assistant Professor, Department of Cardiovascular And Thoracic Surgery, Khwaja Yunus Ali Medical College & Hospital, Enayetpur, Sirajganj, Bangladesh.
2. Professor & HOD Of Cardiovascular & Thoracic Surgery, Khwaja Yunus Ali Medical College & Hospital, Enayetpur, Sirajganj, Bangladesh.
3. Assistant Professor, Cardiovascular & Thoracic Surgery, Khwaja Yunus Ali Medical College & Hospital, Enayetpur, Sirajganj, Bangladesh.
4. Senior Register, Cardiovascular & Thoracic Surgery, Khwaja Yunus Ali Medical College & Hospital, Enayetpur, Sirajganj, Bangladesh.

Correspondence: Dr. Mahbub Ahsan, Assistant Professor, Department Of Cardiovascular And Thoracic Surgery, Khwaja Yunus Ali Medical College And Hospital, Enayetpur, Sirajganj, Bangladesh. Mobile: +8801711174424, E-mail: mahbub.ahsan8@gmail.com.

CT scan of the chest revealed massive left sided pleural effusion with underlying mass measuring 16×14×10 cm (Figure 2).

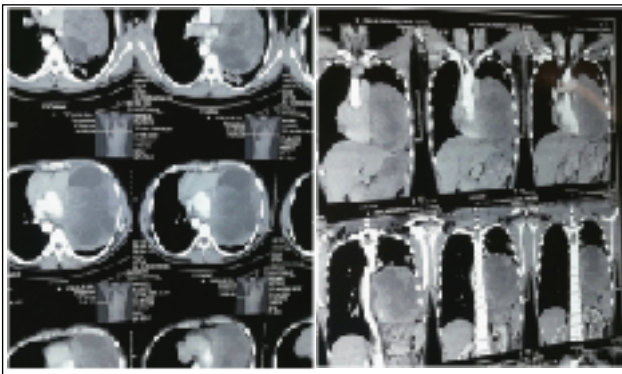


Figure 2: CT chest of the patient.

CT guided FNAC showed mediastinal mass which may be spindle cell thymoma, neurogenic tumor or fibrosarcoma.

The patient underwent left-sided posterolateral thoracotomy through 6th rib bed. There was a huge soft tissue spongy mass with entrapped fluid, lung was compressed and pushed upwards and to the left side. The mass was removed piece by piece, the adherent capsule was excised, the adherent pleura was cut and the lung was re-expanded. The tumor was adherent to the lung, pericardium and underlying diaphragm (Figure 3 and 4).

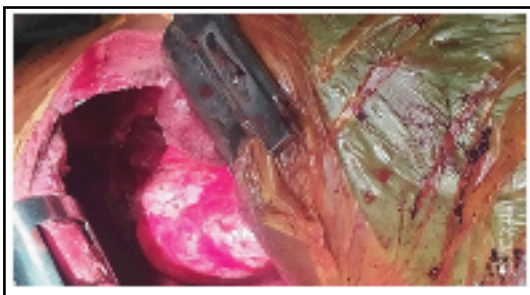


Figure 3: Per-operative picture.

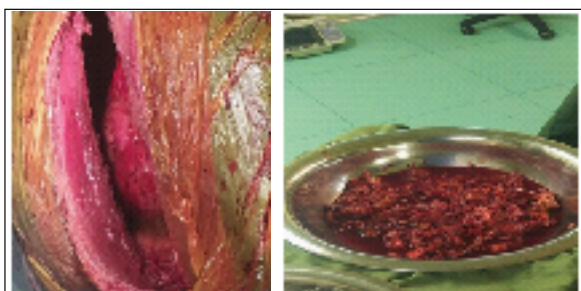


Figure 4: Per-operative picture and resected specimen.

The subsequent postoperative period of this patient was satisfactory (Figure 5). The patient was discharged on 10th postoperative day with stable condition.

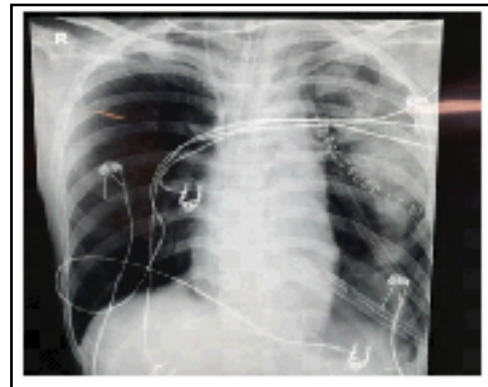

Figure 5: postoperative Chest X-ray.

Postoperative histopathology reported that the huge mass was thymic carcinoma. The patient was referred to oncology department for further management.

Discussion

Mediastinal tumors are rare entity. They are usually slow growing tumors. When they compress surrounding structures it may produce symptoms such as cough, heaviness, pain. The most common mediastinal tumors are thymoma, thymic carcinoma, Hodgkin's lymphoma, Non Hodgkin's lymphoma and germ cell tumors. Pericardial cysts, bronchogenic cysts, parathyroid and oesophageal tumors are middle mediastinal mass. The neurogenic tumors and thymic neuroendocrine tumors are posterior mediastinal tumors.

Thymic carcinomas are aggressive epithelial tumors associated with high incidence of local invasion and distant metastases. Symptoms may be cough, chest pain, shortness of breath. They may be of low or high grade variety. Thymic carcinoma comprises 1% of thymic malignancies. They typically occur in middle aged men. Carcinoma showing thymus like differentiation (CASTLE) are rare neoplasm.¹ They usually occur in neck and thyroid gland. There are various subtypes. They are usually diagnosed by CT scan and CT guided FNAC. Metastases are common in pleura, pericardium. In some cases, pleural and pericardial effusions occur differentiating them from thymoma. Thymoma is a slow growing thymic tumor, completely encapsulated. But 34% invade through capsule and may extend to surrounding structures including pleura, pericardium and lung. The majorities of patients are asymptomatic but may present as chest pain, cough, dyspnoea and some may present features of paraneoplastic syndrome such as myasthenia gravis (30-50% cases).

Hodgkin's lymphoma represents 50-70% of mediastinal lymphoma with an incidence of 2-4 cases per 100,000 people per year. Approximately 20-30% of this patient may present the B symptoms (fevers, night sweats and weight loss) and patients with mediastinal involvement may develop chest pain, cough and dyspnoea.

Non Hodgkin's lymphoma (NHL) represents 15-25% of mediastinal lymphoma. Two variants of NHL, lymphoblastic lymphoma and large B cell lymphomas are usually found in anterior mediastinum. Some of these may involve bone marrow.

Germ cell tumors typically derived from ectoderm, endoderm and mesodermal germ cells.²⁻⁴ Mature cystic teratomas are most common mediastinal germ cell tumors (GCT) representing 60-70% of all mediastinal GCT.⁵ About 30-59% are asymptomatic.⁶ Common symptoms are back pain, cough and respiratory distress. Seminomas appear bulky, homogeneous anterior mediastinal mass and calcification is rare. A testicular examination and scrotal ultrasound is recommended when a mediastinal mass is found in a male patient. For diagnoses, -HCG, AFP and CT scan is needed.

Management of mediastinal tumors includes diagnoses by X-ray chest, CT scan and CT guided FNAC, tumor markers, ultrasonogram in some cases. Treatment includes wide excision followed by chemotherapy and/or radiotherapy. But in case of lymphoma, chemotherapy with or without radiotherapy is the treatment of choice.

Conclusion

Although mediastinal tumors are rare tumors extensive medical history and investigations will give the clue to make a diagnoses. Wide excision and biopsy is usually necessary in almost every case.

Acknowledgement

We are grateful to all the doctors, sisters, OT and ICU staff for their support and encouragement.

References

1. Chan LP, Chiang FY, Lee KW, Kuo WR. Carcinoma showing thymus-like differentiation (CASTLE) of thyroid: a case report and literature review. *The Kaohsiung Journal of Medical Sciences*. 2008; 24(11):591-597.
2. Raoufi M, Herrak L, Benali A, Achaachi L, El Ftouh M, Bellarbi S, Tilfine C, Taouarsa F. Mediastinal mature teratoma revealed by empyema. *Case reports in pulmonology*. 2016; 2016.
3. Adebonojo SA, Nicola ML. Teratoid tumors of the mediastinum. *The American Surgeon*. 1976 May 1;42(5):361-365.
4. Sasaka K, Kurihara Y, Nakajima Y, Seto Y, Endo I, Ishikawa T, Takagi M. Spontaneous rupture: a complication of benign mature teratomas of the mediastinum. *AJR. American journal of roentgenology*. 1998 ;170(2):323-328.
5. Kumar A, Persuad P, Shiwalkar N. Intraoperative Catastrophe during Benign Mediastinal Tumor Mass Excision: A Case Report. *Cureus*. 2019 Jun;11(6).
6. Nichols CR. Mediastinal germ cell tumors. *Histopathology*. Chest. 1991;99:472-479.