

Original Article



Role of Ultrasonography in The Differentiation of Solid Breast Mass

Fatama Sharmin¹, Nazif Sultana², Nazneen Akter³,
S. M. Mazharul Islam⁴, Farhana Zaman⁵.

Abstract

Background: Breast cancer is the major cause of cancer death in women. Breast ultrasound is of a great value in differentiating malignant from benign masses. **Objective:** To distinguish benign from malignant solid breast lesions by Ultrasonography (USG). **Materials and Methods:** This cross sectional study was performed in Radiology and Imaging department of Dhaka Community Medical College Hospital (DCMCH) in collaboration with the department of Pathology and Surgery, DCMCH from January 2017 to December 2017. The benign and malignant solid breast mass were differentiated by using USG and correlated these with histopathological findings. **Results:** Total 60 female with breast mass, aged 20 to 60 years, were studied. Out of 60 cases, 34 cases were solid breast mass on USG. Eleven cases were diagnosed as malignant and 23 cases as benign. Among the USG diagnosed 11 cases, 10 cases found truly malignant (true +ve) and 1 (one) case was benign (false+ve) whereas out of the 23 benign cases, 21 were benign (true -ve) and 2 (two) were found malignant(false-ve), and all were confirmed by histopathology. The sensitivity of USG for malignant breast mass was found 83.33% and specificity was 95.45%. The positive and negative predictive values of USG were 90.91% and 91.3% respectively. The diagnostic accuracy of USG in differentiating breast mass into malignant and benign was 91.318%. **Conclusion:** The USG is a very good diagnostic modality for differentiating benign and malignant breast mass.

Key words: Breast cancer, USG, Benign, Malignant.

Date of received: 05.10.2020.

KYAMC Journal.2021;11(4):204-207.

Date of acceptance: 25.11.2020.

DOI: <https://doi.org/10.3329/kyamcj.v11i4.51998>

Introduction

Breast cancer is the most common cause of cancer death in women.¹ Now a days, it is the most common cause of cancer death, coming fifth after lung, stomach, liver and colon cancer. In female most of the breast disease present as palpable lump, inflammatory lesion, nipple discharge or mammographic abnormalities. Inflammatory (acute or chronic mastitis), traumatic (haematoma, fat necrosis), cystic (simple cyst, abscess), neoplastic (benign and malignant) are the common causes of lump in breast. Among these the common causes of solid breast masses are fibroadenoma and carcinoma.²

Fibroadenoma is the most common benign solid mass of female breast, frequently occurring in younger women with a peak incidence in the third decade. Clinically they are presented as smooth, well-circumscribed, mobile palpable lump.

Solid malignant breast lesion is carcinoma breast, which may present with hard mass with or without nipple retraction, nipple discharge.

It is widely accepted that breast lesion should be assessed by the triple test involving clinical examination, imaging and needle biopsy. A number of studies have confirmed that triple assessment is both sensitive and specific.^{3,4}

Definitive diagnosis can be obtained preoperatively by imaging and histopathological examination. So the management of patients with carcinoma breast is improved. Early detection of breast malignancy offers an important prospect of improving the outcome of the disease.

Ultrasonography (USG) is generally accepted as the method of choice for the differentiation of cystic from solid masses,

1. Assistant Professor, Department of Radiology and Imaging, Dhaka Community Medical College, Dhaka, Bangladesh.
2. Consultant Sonologist, Department of Radiology and Imaging, Dhaka Community Medical College Hospital, Dhaka, Bangladesh.
3. Assistant Professor, Department of Radiology and Imaging, Cumilla Medical College, Cumilla, Bangladesh.
4. Assistant Professor, Department of Physical Medicine and Rehabilitation, Dhaka Medical College, Dhaka, Bangladesh.
5. Registrar, Department of Medicine, Dhaka Community Medical College Hospital, Dhaka, Bangladesh.

Correspondence: Dr. Fatama Sharmin, Assistant Professor, Department of Radiology and Imaging, Dhaka Community Medical College, Dhaka, Bangladesh. Phone: 01768464544, Email: fatamasharmindr@gmail.com

for preoperative assessment of size, characteristics and extend of disease, for guidance of interventional procedures and provide a base line post treatment surveillance. It is highly accurate modality for confirming the presence of a breast cyst that is suspected from a physical examination or from mammography.⁵⁻⁹ With the improved Ultrasound technology, breast Ultrasound is of a great value in differentiating malignant from benign masses.⁴ It is inexpensive, quick, reliable, non-invasive, real time imaging and has no radiation hazards. So it is the initial investigation of choice in young patients. It is also valuable in mammographically dense breast. It can also be used to localize impalpable breast lumps.¹⁰ Several studies have shown that USG can detect lesions that are mammographically occult, particularly in dense breasts. The potential benefits of vigorous USG of both breast and axillae, provide accurate assessment of size and demonstration of single or multiple tumour foci, characteristics of soft tissue masses (indicating invasion) and abnormal lymph node. Thus breast USG has a role not only in diagnosis but also in the staging of local and regional disease.¹¹

Although the sonographic patterns of benign and malignant solid lesions may overlaps, the improved spatial and contrast resolution of modern high frequency transducer allow better differentiation of these lesions.

Though MRI is more sensitive, USG is a reliable investigation in the diagnosis of invasive lobular carcinoma of breast. The sensitivity of USG in these tumor has been raised from 25% to 93%, possibly due to the use of higher frequency probes (7MHz upto 13 MHz) together with meticulous examination of the area corresponding to the mammographic abnormality.¹²

The present work has been carried out to assess the diagnostic accuracy of breast USG to evaluate solid mass lesion.

Materials and Methods

This crosssectional observational study was carried out in the department of Radiology and Imaging, Dhaka Community Medical College Hospital (DCMCH), Dhaka, from January 2017 to December 2017. Total 60 female patients suspected with breast mass were referred to Radiology and Imaging department of DCMCH for Ultrasonographic diagnosis.

The age range of the patients was 20-60 years. After taking history, clinical examination of both breasts and axilla was performed. The patients were then evaluated by USG. 7 MHz linear array transducer was used to perform USG of breast. Each lesion was assigned to one of the following categories based on overall ultrasound features; normal, benign and malignant. Sonographic features of malignant lesions are inhomogeneity of internal echo pattern, ill defined or speculated margins, low level or marked hypoechogenicity, distal attenuation, ill defined echogenic halo, variable shape, the mass being taller than wide, calcifications and intraductal extension. Benign features are well defined smooth margins with 2-3 gentle lobulations, homogeneity of the internal echo pattern, variable to intense hyper echogenicity, oval or elliptical shape, wider than deep, aligned to tissue planes, posterior enhancement.

These patients who were diagnosed as benign and malignant breast mass by USG were then evaluated by histopathology to see the accuracy of USG diagnosis.

Those patients who were diagnosed as benign and malignant breast mass was undergone for histopathological examination. All clinical information, USG and histopathological findings were collected in a preformed structure collection sheet and statistical significance were assessed using the Chi-square and Fisher's exact test.

Results

A total of 60 clinically suspected cases of breast mass were subjected to USG diagnosis. Out of 60 cases, 34 cases were diagnosed as solid breast mass by USG. The USG diagnosed 11 cases as malignant and 23 cases as benign (Table-I).

Table I: Association between US findings and US diagnosis

US findings	US diagnosis		p-Value
	Malignant (n = 11)	Benign (n = 23)	
Margins			
Irregular	9(81.81)	3(13.05)	<0.001
Regular	2(18.19)	20(86.95)	
Echogenicity			
Hypoechoic	10(90.91)	19(82.61)	0.387
Isoechoic	1(9.09)	3(13.04)	
Hyperechoic	0.0	1(4.34)	
Posterior shadowing			
Present	7(63.63)	4(17.39)	0.884
Absent	4(36.37)	19(82.61)	
Lateral shadowing			
Present	5(45.45)	8(34.79)	0.083
Absent	6(54.55)	15(65.21)	
Posterior enhancement			
Present	3(27.27)	6(26.09)	0.121

All of the cases of solid breast mass, were underwent FNAC and excisional biopsy. Among the malignant solid lesions, 10 cases were truly malignant (true +ve) and 1 case was found benign (false +ve) as confirmed by histopathology. While out of 23 benign solid mass (USG diagnosis), 21 were found benign (true -ve) and 2 were found malignant (false -ve). So finally 12 cases were diagnosed malignant and 22 cases were benign solid masses (Table-II).

Table II: Validity of USG differentiation solid breast mass is as follows-

Sonographic diagnosis	Histopathological Diagnosis		Total
	Malignant	Benign	
Malignant	10(TP)	01(FP)	11
Benign	2(FN)	21(TN)	23
Total	12	22	34

Age 40 years or more are more prone to develop malignancies than age less than 40 years (22.7%) ($p < 0.001$). USG findings of solid breast masses in 60 patients showed that presence of irregular speculated margins was higher in malignant forms of tumours (80%) compared to that in benign forms (11.4%) ($p < 0.001$). Malignant lesions are more hypoechoic than that of benign solid mass. (Figure-1, Figure-2 and Figure-3) No significant association was found between microcalcification and malignancy, although proportion of microcalcification is higher in malignant group. Posterior shadowing was evident in malignant cases. Lateral shadowing and posterior enhancement was observed to be significantly associated with USG diagnosis ($p = 0.083$ and $p = 0.121$ respectively).

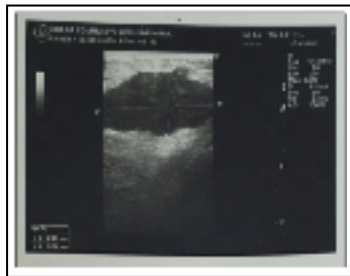


Figure 1: Breast carcinoma

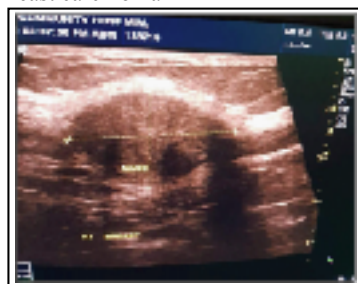

Figure 2: Fibroadenoma of breast

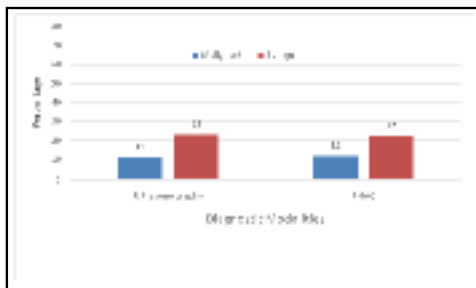


Figure 3: Comparison between two diagnostic modalities

Figures in the parentheses denote corresponding %. Data were analyzed using Chi-square (χ^2) Test and level of significance was 0.05.

In the present study, using the formula for compiling different components of accuracy test. It was found sensitivity of US who had malignant breast mass was 83.3% and specificity was 95.45%. The positive and negative predictive values of US were 90.9% and 91.3% respectively. The diagnostic accuracy of US in differentiating breast mass into malignant and benign was 91.3%.

Discussion

Breast lump is one of the most common surgical problem of female population in the world as well as in Bangladesh. The mortality rate of breast carcinoma has remained unchanged for last 60 years. Significant reduction of mortality could be achieved by early detection & treatment. USG of breast and axilla playing a pivotal role in this regard and successfully help distinguishing many benign from malignant solid nodule and thus many unnecessary biopsy could be avoided.

In this study the mean age of the subjects was 36.5 ± 10.5 years and the range was between 20 to 60 years.

Patients age 40 years or more are more prone to develop malignancies than those whose age less than 40 years (22.7%) ($p < 0.001$).¹⁰ In the present study, size of the tumours were 0.5cm to 8cm of which 55% had 3 or >3cm in size and 45% >3cm in size. The size of the tumours were 0.5 to 8.0cm which was statistically insignificant.

In this study, US findings 32.8% of tumors had irregular margins 81.3% were hypoechoic, 7.8% isoechoic and only 4.7% hyperechoic; 14% exhibited posterior shadowing, and 29.7% lateral shadowing; 21.9% demonstrated posterior enhancement and 17.2% had evidence of microcalcification. In the study of Ciatto et al 28% had irregular margins, 69% hypoechoic 3% isoechoic, 2.3% hyperechoic and 8.4% exhibiting posterior shadowing and 28.5% lateral shadowing 24.7% demonstrated posterior enhancement.¹³

In the present study, based on US findings 31% were diagnosed as malignant and 69% were benign masses. In comparison 33% were detected as malignant and 67% were diagnosed as benign masses in histopathology. In the study of Stavros et al 83% were histopathologically benign and 17% were malignant masses.⁷ Which is significantly less than the present study regarding malignancy.

The above results indicate that US is highly specific and sensitive in the differentiation of malignant and benign breast masses.

Conclusion

Ultrasonography is one of the useful method in the differentiation between benign and malignant breast masses. Moreover Ultrasonography is cost effective, available, less time consuming and it gives real time image. It is a good modality to see multiplicity of mass, architectural distortion, morphological characterization, lobulation, encapsulation, intramammary and axillary lymphadenopathy and thereby it may help surgeon for operative plan and may decrease patient's morbidity and mortality.

Acknowledgement

We sincerely acknowledge the department of Pathology and department of Surgery of DCMCH for their tremendous support in the study period. A heartfelt gratitude to Dr. S.M. Mazharul Islam, Assistant Professor, department of Physical Medicine and Rehabilitation, Dhaka Medical College for his intellectual cooperation.

References

1. World Health Organization. Cancer, 2006 Feb; Fact sheet No.297.
2. Cotran RS., Kumar V., Robbins SL. The breast.in:stephen F, managing editor.Robbin's Pathological Basis of Disease 6th ed.Philadelphia: W.B. Saunders;1999.1093-1114.
3. Howlett DC Marchbank NDP Allan SM. Sonographic assessment of symptomatic breast - a pictorial review. J Diagnostic Radiography and Imaging 2003;5:3-12.
4. Lister D Evans AJ Burrell HC Blamcy RW Wilson ARM., Pinder SE.,et al. The accuracy of breast ultrasound in the evaluation of clinically benign discrete, Symptomatic breast lump. Clinical Radiology 1998;53:490-492.
5. Rizzato G, Chersevani R, Giuseppetti GM, Baldassarre S, Bonifacino A, Ranieri E. et al. In: Gandolfi L, Ed. Breast Ultrasound. Bologna, Editorial Grosso;1993:15-80.
6. Roche NA., Given-Wilson RM., Thomas VA., Sacks NP. Assessment of a scoring system for breast imaging. Brj surg 1998;85:669-672.
7. Stavros AT, Thickman D, Rapp CL, Dennis MA, Parker SH, Sisney GA. Solid breast nodules: use of sonography to distinguish benign and malignant lesions. Radiology 1995; 196:123-134.
8. Wilkinson LS., Given-Wilson R Hall T Potts H Sharma AK., Smith E. Increasing the diagnosis of multifocal primary breast cancer by the use of bilateral whole breast ultrasound. Clinical Radiology 2005;60:573-578.
9. Teixidor HS. The use of ultrasonography in the management of masses of the breast. Surg gynecol obstet 1980;150:490-492.
10. Kolb TM, Lichyj., Newhouse JH. Occult cancer in women with dense breast : detection with screening US-diagnostic yield and tumour characteristics. Radiology 1998;207:191-108.
11. Wilkinson LS Given-Wilson R Hall T Potts H Sharma AK Smith E. Increasing the diagnosis of multifocal primary breast cancer by the use of bilateral whole breast ultrasound. Clinical Radiology 2005;60:573-578.
12. Buchberger W, Niehoff A, Obrist P, Dckoekkoek Doll P, Dunser M. Clinically and mammographically occult breast lesions: detection and classification with high resolution sonography. Semin ultrasound CT MR 2000; 2: 325-336.
13. Ciatto S Turco MRD Catarzi S Morrone D. The contribution of ultrasonography to the differential diagnosis of breast cancer. Neoplasia, 1994; 41:341-345.