

## Case Report



# Pneumatosis Cystoides Intestinalis: A rare cause of intestinal obstruction

Sayed Bin Sharif<sup>1</sup>, Halima Khatun<sup>2</sup>, Shakila Jannat<sup>3</sup>, Kazi Shaila Naznin<sup>4</sup>, ASM Akramul Islam<sup>5</sup>

### Abstract

There are many well-known causes of acute or sub-acute intestinal obstruction. But *Pneumatosis cystoides intestinalis* (PCI) is a rare cause and can easily be misdiagnosed. PCI refers to presence of air within the wall of small or large intestine. This benign disease having both idiopathic and secondary causes with different contributing pathogenic factors that confuses many doctors. In most of the time it is asymptomatic, but clinical signs and imaging impression may mimic true abdominal visceral perforation or soft tissue stranding leads to mechanical obstruction. PCI sometimes incidentally found during radiological evaluation, endoscopic procedure or laparotomy. Surgery is not recommended for PCI if there was no intestinal obstruction, because of high operative risk. So correct diagnosis is imperative as treatment of PCI is generally conservative. We are presenting a case of intestinal obstruction who underwent to laparotomy followed by histopathological diagnosis as a case of PCI.

**Keywords:** Hyperbaric oxygen therapy, Intestinal obstruction, *Pneumatosis cystoides intestinalis* (PCI).

**Date received:** 14.07.2022

**Date accepted:** 03.09.2022

**DOI:** <https://doi.org/10.3329/kyamcj.v13i3.63275>

**KYAMC Journal. 2022; 13(03): 177-180.**

### Introduction

Pneumatosis cystoides intestinalis (PCI) is a rare condition where air or gas filled cyst found within mucosa, submucosa or subserosa of small intestine or colon. Sometimes it may also affect the stomach where the condition known as gastric pneumatosis. It was first described by De Verno in 1730.<sup>1</sup> In most of the cases it is asymptomatic, so the prevalence of PCI is difficult to determine. Many previous studies reported an incidence rate of 0.03% in the general population, typically developing in the fifth to eighth decade of life.<sup>2</sup> In 2013 Wu et al, reported a review of literatures analyzed 239 patients with PCI, where the peak age of onset was  $45.3 \pm 15.6$  years (ranged 2–81 years), the male to female ratio was 2.4:1.<sup>3</sup> PCI developed as a primary (idiopathic) form in 15% of cases and as a secondary form in 85% of cases, manifesting a wide variety of gastrointestinal (e.g., Pyloric stenosis, sigmoid volvulus, ulcerative colitis and ischemic bowel) and non-gastrointestinal (e.g., chronic obstructive pulmonary disease, depression and systemic sclerosis) disease.<sup>4</sup> Patient taking alpha-glucosidase inhibitors for type II diabetes mellitus also reported having PCI.

PCI lesions are mainly located in the colon (46%), small intestine (27%), combined large and small intestine (7%) and stomach (5%).<sup>1,5</sup>

The clinical presentation of PCI may vary as majority of the patients remain asymptomatic. Those having symptoms are relatively vague like - abdominal pain and distension, vomiting, diarrhea, hematochezia with flatulence, loss of appetite and tenesmus. The clinical presentation may associate with chronic intestinal pseudo-obstruction with a mortality rate may reach up-to 75%.<sup>6</sup> A report of complications of PCI developed about 3% of the patients including pneumoperitoneum, volvulus, intestinal obstruction, and intestinal ischemia.<sup>1</sup>

The confirmation of PCI using imaging is not straightforward. On plain X-ray abdomen PCI only visible in two-thirds of the patient. CT scan shows a thickened bowel wall containing gas or appearing as grape-like clusters or honeycomb-shape shadows along the wall of intestine. Furthermore, there are reports in CT findings of the following observations : Three patterns of pneumatosis have been described; a bubble-like or cystoid pattern characterized by separate bubbles of gas with a cystic appearance, a linear pattern in which the gas has a curvilinear or a crescent shape and a circular or circumferential form in the bowel wall; in some cases all these patterns may be seen at the same time.<sup>2</sup> On endoscopy, observed as polypoid, with the overlying mucosa displaying a blue hue. During biopsy partial or collapsed cyst may be diagnostic. However, the puncture of

1. Associate professor of Surgery, Khwaja Yunus Ali Medical College and Hospital, Enayetpur, Sirajganj, Bangladesh.
2. Assistant professor of Pathology, Khwaja Yunus Ali Medical College and Hospital, Enayetpur, Sirajganj, Bangladesh.
3. Assistant professor of Pathology, Khwaja Yunus Ali Medical College and Hospital, Enayetpur, Sirajganj, Bangladesh.
4. Indoor medical officer of Gynae & Obs., Mugda Medical College and Hospital, Mugda, Dhaka, Bangladesh.
5. Professor of Pathology, Khwaja Yunus Ali Medical College and Hospital, Enayetpur, Sirajganj, Bangladesh.

**Corresponding author:** Sayeed Bin Sharif, Associate professor of Surgery, Khwaja Yunus Ali Medical College and Hospital, Enayetpur, Sirajganj, Bangladesh. **Cell Phone:** 01716235357, **Email:** sayeed616@yahoo.com

mucosal or submucosal cysts itself can be a cause of PCI.

### Case presentation

A 86 years old normotensive, non-diabetic, non-icteric male admitted into the surgery department with the complaint of sudden severe abdominal pain for 6 hours associated with vomiting. The pain was dull aching started in epigastric area and spreading to the whole abdomen. The pain was not related on taking meal. He had same type of attack 1 year back. His bowel and bladder habit were normal. He was non-asthmatic, having a right sided reducible inguinal hernia for the last 5 years. The patient had no history of fever, weight loss or any per rectal bleeding. On examination, the abdomen was tender in epigastric, right hypochondriac and umbilical area. The bowel sound was sluggish. Plain X-ray abdomen reported as sub-acute intestinal obstruction. On CT scan of abdomen, there was a circumferential irregular thickening of segmental wall in the 2<sup>nd</sup> part of duodenum, bilateral renal cortical cyst and bilateral inguinal hernia. On laboratory findings he had hyponatremia, which was corrected accordingly and the other parameters including

coagulation profile were found normal. His vomiting did not completely subside even after having conservative treatment. Then he was planned for gastro-jejunostomy according to clinical state and CT scan findings. Gastro-jejunostomy was performed using linear cutter stapler. On the 2<sup>nd</sup> postoperative day he got blood loss through NG tube. He also developed fever with increased WBC count. Then antibiotic was changed, blood transfusion and cold normal saline wash was given through NG tube. The sepsis was improved but blood loss through NG tube did not improve till the 5<sup>th</sup> postoperative day. Then planning was taken for re-laparotomy. During 2<sup>nd</sup> laparotomy there was no apparent external bleeding at anastomotic site rather seems to be internal bleeding inside the stomach. Then distal gastrectomy including the previous anastomosis site was done. A roux-en-Y gastro-jejunostomy was performed. The post-operative period was un-eventful. Histo-pathology of distal stomach and gastro-jejunostomy site was reported as pneumatosis cystoides intestinalis (PCI) with parietal cell hyperplasia of the stomach.

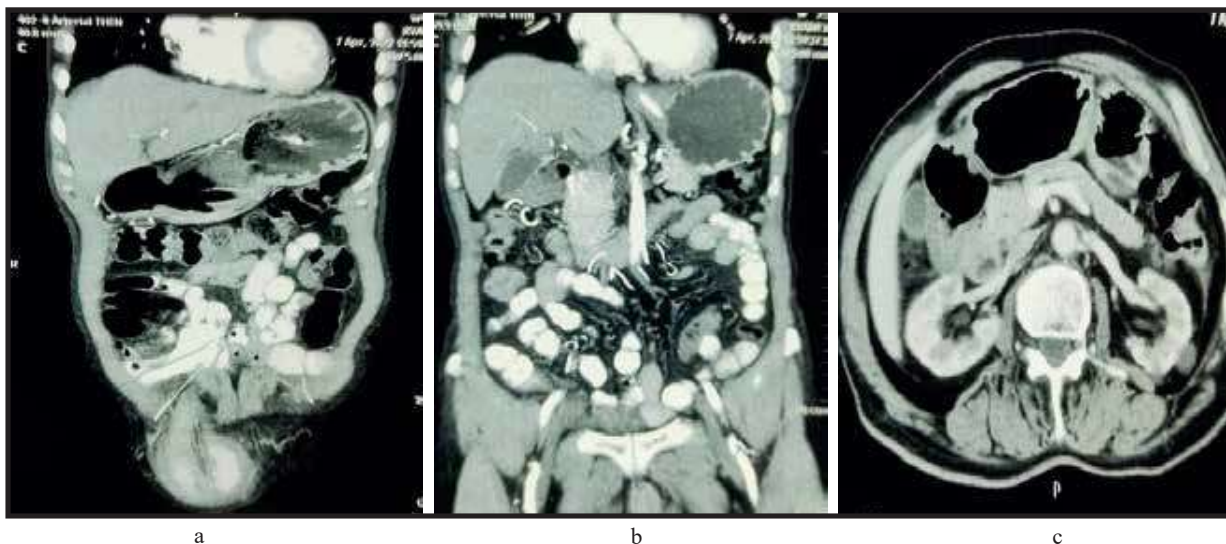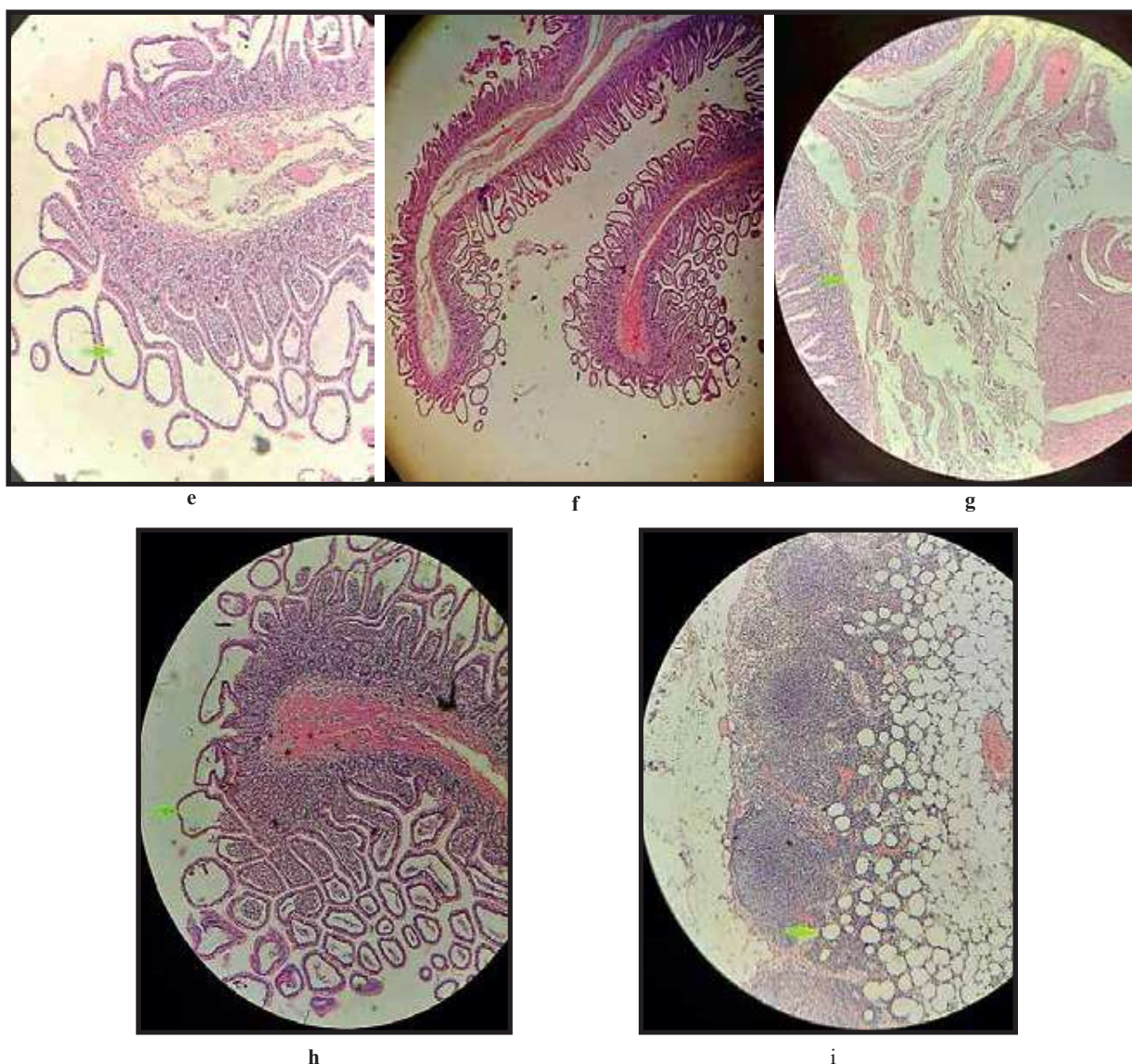


Figure - a,b,c shows abdominal CT scan with soft tissue thickening in arrow mark.

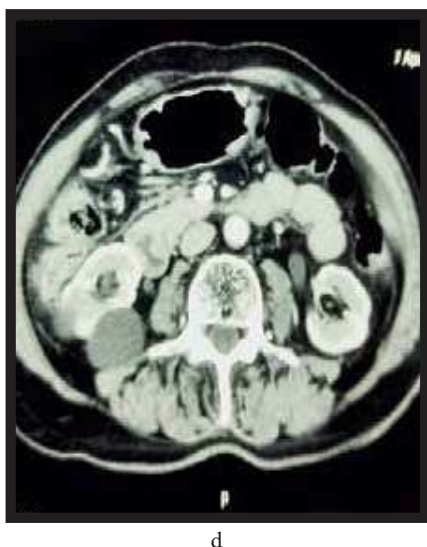

Figure - 'd' shows cross section of abdominal CT where arrow-mark shows sub-serosal gas/air.





**Figure - e,f,g & h** shows histopathological slides where arrow mark shows air in mucosal and sub-mucosal area.

**Figure - 'I'** shows histological picture of lymph node where arrow shows air in the cortical area.

### Discussion

Pneumatosis cystoides intestinalis may present with acute or sub-acute clinical presentation. The disease may be caused by a combination of diseases exerting elevated intraluminal pressure followed by inflicting mucosal damage; that leads to enter of gas forming micro-organism to the intestinal wall, thus forming cysts. There are three hypotheses of PCI pathogenesis: (1) mechanical theory: involving an increase in intraluminal pressure that causes mechanical damage and mucosal rupture of the intestinal wall, leading to the migration of gas from the gastrointestinal cavity to the intestinal wall;<sup>1,7</sup> (2) pulmonary theory: chronic lung diseases such as chronic obstructive pulmonary disease, asthma, and interstitial pneumonia lead to alveolar rupture, causing mediastinal emphysema and release of gas along the aorta and mesenteric blood vessels into the intestinal wall;<sup>1,8</sup> and (3) Bacterial theory: aerogenic bacteria

penetrate the intestinal mucosal barrier, ferment in the intestinal wall, and produce gas.<sup>1,9</sup> Patient taking alfa-glucosidase inhibitor for DM, which involve intestinal gas (Carbon dioxide, hydrogen, methane) production through fermentation of carbohydrates by the intestinal flora, where absorption is inhibited by alpha-glucosidase inhibitors.

PCI was found associated with chemotherapy, hormonal therapy and agent used for targeted therapy.<sup>2,10</sup> Mucosal break down from steroids and other immunosuppressive agents cause Peyer's patches in the bowel wall to shrink, leading to an alteration of mucosal integrity and the potential for air dissection.

PCI can also develop in course of systemic sclerosis;<sup>2,11</sup> where combined pathology such as microangiopathy, intestinal

atrophy and fibrosis, impaired intestinal motility, bacterial overgrowth, elevated intraluminal pressure and increased permeability of intestinal wall may predispose to PCI.<sup>11</sup>

PCI are also similar to those of other diseases, such as inflammatory bowel disease, intestinal neoplasms, and intestinal polyps. Additionally, PCI has been associated with Crohn's disease and both can coexist in the same patient.<sup>1,12,13</sup>

Symptomatic PCI often response with conservative treatment like hyperbaric oxygen therapy, administration of antibiotic, discontinuation of alpha glucosidase inhibitor. Failure in recognition and treatment of underlining disease of PCI may result in high recurrence rate (50-78%).<sup>4,14</sup>

In our case, the patient was 84 years old having CT scan reported as pathology in 2<sup>nd</sup> part of duodenum with symptoms of pain and vomiting. As the inguinal hernia was reducible and no tenderness at inguino-scrotal area; so, decision was taken for gastric bypass surgery. But the decision might be changed if we got any clue for PCI. Upper GIT endoscopy we planned but not done due to refusal of patient.

Surgical treatment is a second line therapy for PCI due to post-operative complication and high mortality rate (75%).<sup>15</sup> Surgery should be avoided unless there are signs of severe inflammation, sepsis, metabolic acidosis or portal venous gas. Clinical decision should not rely on the radiological picture, but should be coupled to the clinical symptoms.

## Conclusion

As PCI is a rare condition, where clinician and radiologist should be aware of the possibility of PCI in order to manage the patient. Unnecessary surgery can be avoided if the knowledge of primary pathology of PCI upto the level. Surgical resection of involved bowel, with its attendant morbidity and mortality has been complicated by recurrence of the disease. Normobaric oxygen treatment lasting six to ten days, has the advantage of being noninvasive, but does expose the patient to pulmonary oxygen toxicity. Recurrence following treatment is positive. Hyperbaric oxygen therapy at 2.5 ATA has the advantage of requiring only two to three treatments. It is also noninvasive, and does not cause pulmonary oxygen toxicity. The incidence of clinically significantly pulmonary or CNS oxygen toxicity is very low, and has proven reversible on discontinuation of therapy.

## Acknowledgment

We are grateful to department of pathology KYAMCH for there hard work to notify the disease. We also thankful to Dr. ABM Moniuddin, Professor of Surgery, KYAMCH and Dr. Zulfikar Ali, Professor of Medicine, KYAMCH for making correction and success of this paper.

## Reference

1. Ling et al. Pneumatosis cystoides intestinalis: a case report and literature review. *BMC Gastroenterology*, 2019; 19: 176.

2. Sugihara Y et al. Pneumatosis cystoides intestinalis. *J Lung Health Dis*, 2018; 2(1): 24-27.
3. Wu LL, Yang YS, Dou Y, et al. A systematic analysis of pneumatosis cystoides intestinalis. *World J Gastroenterol*. 2013; 19(30): 4973-4978.
4. Chien-Jen T et al. Pneumatosis cystoides intestinalis. *Formosan Journal of Surgery*, 2011; 44 (5): 192-195.
5. Morris MS et al. Management and outcome of pneumatosis intestinalis. *Am J Surg*. 2008; 195(5): 679-682.
6. Azzaroli F et al. Pneumatosis cystoides intestinalis. *World J Gastroenterol*, 2011; 17(44): 4932-4936.
7. Khail PN et al. Natural history, clinical pattern, and surgical consideration of pneumatosis intestinalis. *Eur J Med Res*. 2009;14(6): 231-239.
8. Keyting WS, McCarver RR, Kovarik JL, Daywitt AL. Pneumatosis intestinalis: a new concept. *Radiology*, 1961; 76:733-741.
9. Gillon J, Tadesse K, Logan RF, Holt S, Sircus W. Breath hydrogen in pneumatosis cystoides intestinalis. *Gut*. 1979; 20: 1008-1011.
10. Groninger E, et al. Free air intraperitoneally during chemotherapy for acute lymphoblastic leukemia: consider pneumatosis cystoides intestinalis. *J Pediatr Hematol Oncol*. 2010; 32(2): 141-143.
11. Puneet Devgun and Hal Hassan. Pneumatosis cystoides intestinalis: A rare benign cause of pneumoperitoneum. *Hindawi publication. Case Reports in Radiology*, vol. (2013), Article ID 353245, <https://doi.org/10.1155/2013/353245>.
12. Ponz de Leon M et al. A case of pneumatosis cystoides intestinalis mimicking familial adenomatous polyposis. *Familial Cancer*, 2013; 12(3): 573-576.
13. Liu, Tingting et al. Gastrointestinal malignant neoplasms disguised as pneumatosis cystoids intestinalis, *Medicine* (Dec 2017) 96(51) - p e9410 doi: 10.1097/MD.00000000000009410
14. Gagliardi G. et al. Pneumatosis coli: a proposed pathogenesis based on study of 25 cases and review of the literature. *Int J Colorectal Dis*. (1996) 11:111e118.
15. Francesco Azzaroli et al. Pneumatosis cystoides intestinalis. *World J Gastroenterol*, 2011; 17(44): 4932-4936.