

Review Article



Granular Cell Tumors

ABM Moniruddin¹, Halima Khatun Doly², Shakila Jannat³, Tanvirul Hasan⁴, MA Rouf⁵

Abstract

GCTs (Granular Cell Tumors) are rare uncommon STTs (Soft Tissue tumors) that may develop at any location in the human body. Though the initial one was identified first as a non-capsulated granular cell myoblastoma of the tongue, they are now identified immunohistochemically as principally of neural Schwann cell origin (S-100 marker positive). Still more rarely non-neural GCTs are also described that are probably of mesenchymal origin (as evidenced by S-100 marker negativity and vimentin positivity). Though they are more common in females and black people in the third to sixth decades of life, no sex, no race, and no age group are immune to this disease. They are mostly benign and very rarely malignant. Exact history taking, physical examination and laboratory investigations including histopathological, histochemical, and immunohistochemical examinations are essential to arrive at a concrete diagnosis, as many other tumors (e.g., malignant melanoma, small cell lung cancer, etc.) in the body resemble GCTs both histologically (granularity) and by biological behavior (benign, malignancy, recurrency at primary and metastatic sites). Benign variants have clinical features depending on location and are universally cured by wide surgical excision. The malignant variant carries a worse prognosis. These rare GCTs are to be kept in mind always in the differential diagnosis of soft tissue swellings anywhere in the body. Their biological and pathological features, differential diagnosis, and therapeutic implications are discussed here, with a brief review of the available literature.

Keywords: Abrikosoff tumor, Neural Granular cell Schwannoma, Non-neural granular cell tumor.

Date of received: 14.09.2022

Date of acceptance: 15.05.2023

DOI: <https://doi.org/10.3329/kyamcj.v14i02.68561>

KYAMC Journal. 2023; 14(02): 96-101.

Introduction

Apart from normal physiological such granular cells as neutrophils, eosinophils, and basophils, definite pathological granular cells are found in different disease processes. Pathological “granular cell Tumors” fall into this spectrum of varied pathological processes. GCTs (Granular cell tumors, also called Abrikosoff tumors), are rare soft-tissue tumors, now thought to be originated mainly from Schwann cells (of neural crest ectodermal derivative) of the peripheral nervous system. 98% or slightly more than that, they are stated to be benign, although a few may be locally aggressive.¹⁻³ Some 2% or slightly less than that, they are malignant, carrying a worse prognosis. They can develop virtually at site in the body. They are mainly found in the skin, the subcutaneous tissue of the head, neck, and the submucosa or deep soft tissue or internal organs, especially of the upper aerodigestive tract, the tongue, the oral cavity, the muscles, the rest parts of the alimentary tract, the limbs, the trunk and even the central nervous system. However, they most commonly occur in the upper parts of the body. Several non-neural GCTs have also been reported.⁴⁻⁶

History

In 1926, the Russian pathologist Alexei Ivanovich Abrikosoff first described the GCT (Granular Cell Tumour) in the tongue. It is also called Abrikosoff's tumor or granular cell myoblastoma of the tongue. Later, by immunohistochemistry, the origin of this GCT was identified to be Schwann cells of the peripheral nervous system. Thence, it may also be called granular cell Schwannoma (Quite different from classical Schwannoma), or occasionally granular cell neurofibroma.^{2,7,8} Another variant of GCT is PNNGCT (Primitive non-neural granular cell tumor), which was first described by LeBoit et al in 1991. Because of its primitive polypoid phenotype, it had also been given the term primitive polypoid granular-cell tumor.^{1,9}

Epidemiology

GCTs, both as solitary as well as multiple lesions are found to be

1. Professor & HOD, Department of Surgery, Khwaja Yunus Ali Medical College Hospital, Sirajgonj, Bangladesh
2. Assistant Professor, Department of Pathology, Khwaja Yunus Ali Medical College Hospital, Sirajgonj, Bangladesh
3. Assistant Professor, Department of Pathology, Khwaja Yunus Ali Medical College Hospital, Sirajgonj, Bangladesh
4. Medical Officer, Institute of Nuclear Medicine & Allied Sciences, Bangladesh Atomic Energy, Bangladesh
5. Associate Professor, Department of General Surgery, Khwaja Yunus Ali Medical College Hospital, Sirajgonj, Bangladesh

Corresponding author: ABM Moniruddin, Professor & HOD, Department of Surgery, Khwaja Yunus Ali Medical College Hospital, Sirajgonj, Bangladesh. Cell Phone: +8801795078217, E-mail: abmmu@yahoo.com

more common in Black people. They are more common in females. The male-female ratio is said to be 2:3 to 1:2. GCTs can occur in children, including neonates to people of any advanced age. But its incidence commonly peaks between the third and the sixth decades of life. Its occurrence before 20 years of age is still rarer. No age group and no ethnic group are immune. They are often described as uncommon tumors with a rough prevalence from 0.019% to 0.03% of all human tumors. They account for an incidence of 0.5% amongst all STTs.^{1,10,11}

Pathology

The granularity of GCTs is due to the aggregation of secondary lysosomes in their cytoplasm. This cytoplasmic granularity is not specific to GCTs only. This type of cytoplasmic granularity is also seen in many non-neural tumors, inclusive of those developing from such sources as smooth muscles, connective tissues, neuroglial cells, endothelial cells, and epithelial cells, etc.^{9,12,13}

Clinically, GCTs may appear as firm, skin-colored, or brownish-red nodules. These tumors are commonly small ranging from 5 mm to 2 cm or more and are usually slow growing. GCTs often present as asymptomatic, benign, solitary lesions but may be multi-focal or malignant. The still rarer is their malignant counterpart. These neoplasms are sometimes arbitrarily graded as 0: benign; 1 - 2: atypical; ≥ 3 : malignant. As a universally acceptable recommended staging system for GCT has not yet been formulated, the generally recommended staging system of the AJCC (American Joint Committee on Cancer) that is being used for other STTs (soft tissue tumors) is followed by many centers.^{7,14,15}

These tumors are featured by non-capsulated nests or cords, lobules, trabeculae, or irregular sheets amongst varied amounts of stroma. The tumor cells are large polygonal/polyhedral or round to oval or occasionally bipolar spindle type with abundant eosinophilic and finely or coarsely granular (PAS-positive) cytoplasm, and small or large, pale-staining or vesicular or hyperchromatic or pyknotic nuclei centrally or eccentrically placed in cells. These large eosinophilic granules with clear halos are called Milian's Pustulo-ovoid bodies. Mitoses are rarely seen (Fig 1). The overlying epithelium may show acanthosis or prominent pseudo-epitheliomatous hyperplasia, simulating a carcinoma (Figs 2 & 3).^{11,16,17}

Ultrastructural and immunohistochemical examinations confirm it to be of Schwann cell origin in case of neural GCT. The neural neoplastic cells are positive for S-100, CD68, protein gene product 9.5, and inhibin-alpha, etc. Their typical expression of S100, CD68 (KP-1), CD68 (KP-1) is due to their cytoplasmic lysosome content. But in case of non-neural GCT, they exhibit S-100 negativity (Fig 4) and strong vimentin positivity (Figs 5 & 6).¹⁸⁻²⁰

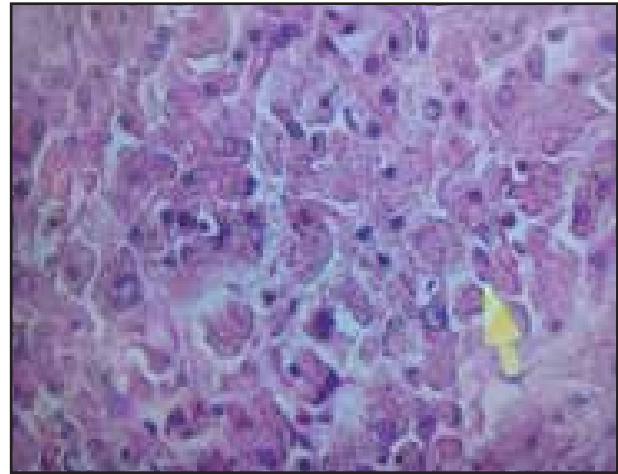


Figure 1: H & E stain of non-neural granular cell tumor in the rectum (Source: Author ownself).

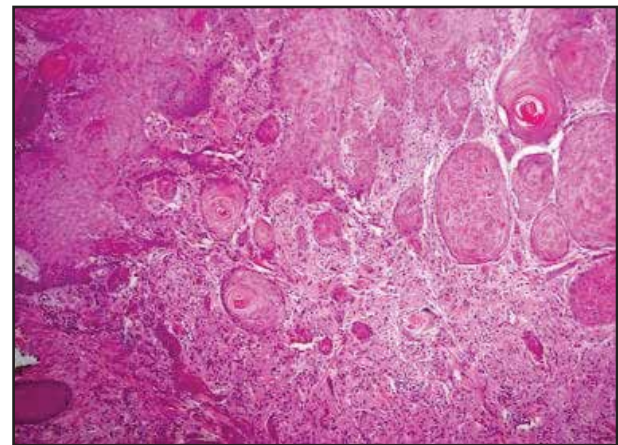


Figure 2: Granular cell tumor simulating squamous cell carcinoma. (Courtesy: Medscape)

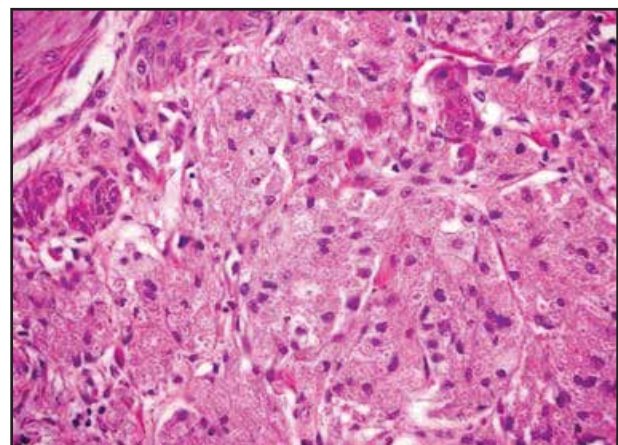


Figure 3: Granular cell tumor beneath the squamous epithelium. (Courtesy: Medscape)

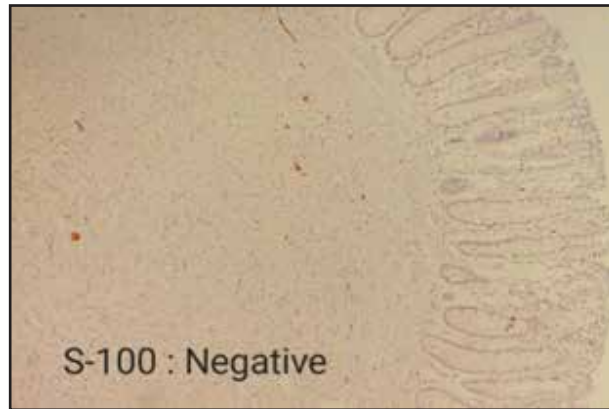


Figure 4: IHC (Immunohistochemistry) where the neoplastic cells showed immunophenotype: S-100: Negative, with non-neural granular cell tumor. (Source: Author ownself).

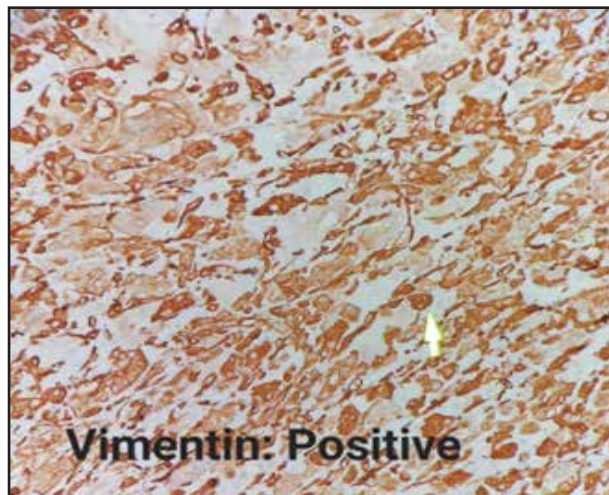


Figure 5: IHC (Immunohistochemistry) where the neoplastic cells showed Vimentin: Strongly positive (+++), thus immune-morphologically is consistent with non-neural granular cell tumor. (Source: Author ownself).



Figure 6: S-100 immunohistochemical stain, (Courtesy: Medscape)

Differential Diagnoses

All soft tissue swellings including schwannomas and neurofibromas, rhabdomyomas, hibernomas, steatomas/lipomas, intracranial glial tumors, granular cell variants of basal cell carcinoma, melanoma, leiomyoma, leiomyosarcoma, dermatofibrosarcoma, angiosarcoma, fibrous histiocytoma, ameloblastoma, mucosal polyps, adenomas, fibroma, hamartoma, choriastoma, granulomas, teratoma, carcinomas, enlarged lymph nodes, liposarcomas, neurolipoma, fibrolipoma, dermatofibroma, lymphatic or vascular malformations, ASPS (Alveolar Soft Part Sarcoma), desmoids, granulomatous and nodular fasciitis, congenital granular cell lesion (CGCL, also known as congenital granular cell epulis or congenital granular cell tumor), etc.^{21,22} A panel of immunohistochemical stains is essential to arrive at a specific concrete diagnosis. Neural granular cell tumors are essentially positive for S-100 protein marker, and negative for epithelial, melanocytic, smooth muscle, dendritic cell, and endothelial markers, etc. Malignant granular cell tumors occasionally simulate alveolar soft part sarcoma or other malignant tumors. Ultrastructural diagnostic lattice patterned rhomboid crystalloids found in alveolar soft part sarcoma are classically absent in GCTs.^{12,23,24}

Complications

Complications include local mechanical effects in accordance to their sites of development, recurrence despite apparent adequate removal, and other common complications of malignant diseases if malignant GCT (generalized complications, local complications, and complications at metastatic sites).^{8,25,26}

Diagnosis

Diagnosis is to be made by classical history taking, physical examination and laboratory aids. Benign GCTs most commonly present as nonulcerated, painless, insidious, slow-growing swellings. They are occasionally larger than 3 cm in size and may have commonly been presented within 6 months of onset. Laboratory investigations may be required to evaluate the functions of affected organs. But, GCTs per se are to be diagnosed solely by taking biopsy specimens analyzed by histological, histochemical, and immunohistochemical methods.^{27,28}

Submicroscopic features of granular cell tumors are classically unique, regardless of the location of the tumor. Nearly 50% of all benign-looking granular cell tumors may have poorly defined or infiltrative margins. A network type of fibrillary framework may occasionally be seen surrounding discrete tumor cells or small cellular aggregates. GCTs may have occasionally been seen widely collagenized. Some of these granules may get extruded out of the cells and may then get phagocytosed by histiocytes (when these are called angulate bodies). The granules can also be stained with Sudan black B, and are colored magenta in trichrome preparations. Multinucleation, plenty of mitotic figures, nuclear pleomorphism, and prominent nucleoli are uncommon features in benign GCTs. Because of their uncertain origin and histogenesis, all available immunohistochemical and ultrastructural examinations should be done. Ultrastructurally highly characteristic pleomorphic secondary lysosomes are seen in the cytoplasm. Characteristic

features suggestive of the neural origin of GCTs (e.g., arrays of neuritic processes, myelin residues, long-spacing collagen amongst tumor cells) may be seen.

GGCTs (Gingival Granular Cell Tumors) of newborns are extremely rare variants seen as polypoid swellings located exclusively over the lateral alveolar ridge, particularly of the maxilla. These may be reactive and not neoplastic.^{9,15,29}

The PPGCT (Primitive Polypoid Granular Cell Tumor) is an additional unusual subset, which presents as an exophytic polypoid cutaneous lesion at any location of any or person of any age. They are featured by nuclear pleomorphism, frequent mitoses, and poor immunohistochemical positivity. They are not aggressive in behavior. They may be taken as a variant of the nonimmunoreactive phenotype of GCT.^{1,19}

Histopathologic features of most malignant GCTs are unique, causing no diagnostic difficulty. But some malignant GCTs are similar to their benign counterparts (i.e., small size, no local destruction, no infiltrative activity, bland innocent cytology), as later on, they can exhibit their malignant characters causing infiltration and metastases.¹³

The GCTs greater than 3 cm in size may be considered malignant considering the following features:^{1,16,23}

*Local destructive features (e.g., ulceration, necrosis, bleeding),

*Infiltrative nature at the edges and bases,

*Frequent or many mitoses,

*Large vesicular nuclei with prominent nucleoli.

AS GCTs react very much positively for nuclear and cytoplasmic S100 protein, like some invasive carcinomas and the majority of melanomas (that also reacting positively for S100 protein), a panel of immune-histo-chemical markers should be employed to confirm the diagnosis.

Treatment

Curative treatment for benign GCT is complete surgical excision/resection. But, local recurrence may occur even with histopathologic clear cut margins. Surgery should be deliberately performed by site-specific specialist surgeons. Extensive radical en bloc excision is to be performed for malignant GCTs. RT (Radiotherapy) and CT (Chemotherapy) are not required for benign GCTs, and are not much beneficial in treating many malignant GCTs. However, there are positive responsive reports to use of pazopanib in cases with metastatic GCTs. Thus, the spectrum of treatment for benign GCTs includes expectant and observation, excision or wide local resection. Recurrent GCTs may very occasionally be found sensitive to adjuvant radiotherapy. Metastatic lesions from GCTs are to be managed by attempted chemotherapy and adjunct supportive therapy when needed. The patients of apparent benign GCTs are to be kept on a follow-up schedule at least annually for several years or at least for two years, while the patients of malignant GCTs are to be kept on follow-up more frequently.^{1,8,12,16}

Discussion

GCTs occur most commonly in the skin and the subcutaneous tissue in about 30–40% of cases. Nearly 50% of all GCTs are detected in the head and neck, with about 25% in the oral cavity, principally in the tongue. They may develop at any skin and mucosal sites, even internal organs. Many other reported sites

of detection of GCTs include the breast, the GIT (Gastrointestinal tract), the respiratory tract, the thyroid gland, the urinary bladder, the CNS (central nervous system), the female genitalia, the skeletal muscle, etc. That is to say that no tissue is immune to development of GCT. In the GIT, the GCT is most frequently found in the esophagus, followed by the duodenum and the large intestine. GCTs occurring in the GIT must be differentiated from other submucosal swellings, e.g., steatoma (lipoma), leiomyoma, neuroma and GIST. The GCT in the GIT is described as a very hard, smooth-surfaced submucosal tumor appearing as a yellow or yellowish-white hemispherical swelling beneath the thin mucous membrane, and is sometimes called "molar tooth" or "sweet corn." It is occasional for clinicians to observe the ulcerous lesions or recesses on the mucosal surface. Granular cell tumors in the esophagus may present as a non-pedunculated esophageal SMT (SubMucosal tumor) with a smooth surface and pale-yellow color. GCT of the breast may be misdiagnosed as invasive ductal cell Ca on imaging. Mammography and ultrasonography can't differentiate an invasive GCT in the breast from an invasive breast cancer.^{1,26,27}

GCT may occasionally be associated with multiple lentiginos, neurofibromatosis, Noonan syndrome, Leopard syndrome, etc. Familial multiple GCTs have also been detected. The most common sites of metastasis from malignant GCTs are the lymph nodes, followed by the lungs. Incomplete tumor resection if followed by local recurrence, it has a propensity to both lymphogenous and hematogenous spread.^{1,29}

The histopathological, histochemical, and immunohistochemical origin of GCT has been a great debate for a long time amongst different authors, as there are enormous arguments as to their origin from fibroblasts, myoblasts, undifferentiated mesenchymal cells, Schwann cells, histiocytes, neural cells, etc. Accordingly, different such names have been given to this disease entity as myoblastoma, granular cell neurofibroma, granular cell schwannoma, etc. Its neuroectodermal origin is now well accepted due to its reactivity for neural markers, though some researchers consider that it could be regarded as an expression of local metabolic or reactive changes, rather than as a real tumorigenesis, which is reflected by its wide spectrum of patterns and architectural features, as well as by its most common benign behavior. There is still an unsolved dispute regarding its immunohistochemical reactivity to broad panels, including antibodies directed against different tissues. And as such, according to some researchers, it is yet to confirm any particular origin and differentiation. However, most researchers now point to its Schwann cell origin on the basis of immunohistochemical and electron microscopic ultrastructural findings, and as such it is better designated as granular cell schwannoma. There are differences between schwannoma and GCT in their ultrastructural features and some expressed immunohistochemical markers.^{1,20,26}

Many other researchers claim that GCT is not a separate specific entity, but a degenerative change in Schwann cells and a variety of other normal and tumorous cells. Until and unless more definite information is available from their cytogenetic studies, this GCT is to be considered as a separate entity, and the descriptive designative term 'granular cell tumor' is claimed to be appropriate.^{1,17}

Regarding familial GCT, the experimental findings are noteworthy. Many researchers detected loss-of-function mutations in ATP6AP1 or ATP6AP2 in about 72% of neural granular cell tumors. Silencing of these genes experimentally in vitro resulted in distorted vesicle acidification, redistribution of endosomal components, and aggregation of cytoplasmic secondary lysosomal granules (the main phenotypic feature of GCTs. After whole-exome sequencing, RNA sequencing, and targeted sequencing of many, many researchers detected loss-of-function mutations in 7 (seven) additional genes encoding vacuolar H⁺-ATPase (V-ATPase) fractions. That is to say that loss-of-function mutations in multiple genes encoding vacuolar H⁺-ATPase (V-ATPase) fractions can explain in some way the pathogenesis of GCTs.^{9,14}

Six histopathologic criteria for malignancy include 1. necrosis, 2. spindle cells, 3. vacuolar enlarged nucleus with an enlarged nucleolar body, 4. increased nuclear division (e.g., at least two mitoses/10HPF), 5. increased nucleo-cytoplasmic ratio, and 6. polymorphism. If none of these six diagnostic criteria are found, the tumor is to be regarded as benign. If one or two criteria are detected, it is regarded as atypical, and if three or more criteria are positive, it is diagnosed as malignant GCT. Malignant GCTs may be grouped into two: 1. malignant both histopathologically and clinically, and, 2. benign histopathologically, but clinically malignant.^{1,19,29}

Prognosis

In case of benign GCTs, recurrences are roughly 2 to 8%, even if resected cut margins are found free of tumor cells, and are about 20% if the cut margins are found positive for neoplastic cells. Malignant GCTs are often aggressive, and very difficult to be eradicated even with radical surgery. Local recurrence rates may be as high as 32% and hematogenous or lymphogenous metastases may be detected in half of these patients, commonly within two years. About 39% of patients with malignant GCTs usually die within three years of diagnosis of the primary neoplasm.^{1,14}

Conclusion

Despite its low prevalence, GCT is to be thought in the differential diagnosis of any soft tissue swelling anywhere in the body. The very differential diagnosis between GCT and several other benign and malignant soft tissue tumors (that show granular cell features) as smooth muscle, vascular, fibro-histiocytic, true histiocytic, and melanocytic tumors, is of utmost importance as it is very much required for appropriate treatment and prognosis. That is to say that every suspicious soft tissue lesion of unknown nature should be thoroughly investigated by taking a complete clinical history, performing all physical examinations, and doing all relevant investigations including imaging to detect the real nature and extension of the disease. And then, if feasible, should be surgically excised with a wide margin adequately in toto to have an oncological radical cure, if it comes into question, keeping in mind the probability of its recurrence. And accurate histological, histochemical, and immunohistochemical examinations are always the definite ways to predict biological behavior. Some GCTs recur locally and some recur at metastatic sites, even after several years of

resection/excision of the primary tumor. Thence, these GCTs essentially need a long-term follow-up schedule, at least annually for at least two years to detect and treat any relapse.^{1,22}

Acknowledgment

We are very much grateful and thankful to Prof Md. Zulfikar Ali and Prof ASM Akramul Islam for their continuous and active inspiration in preparing and publishing this review article entitled “Granular Cell Tumors”.

References

1. Matthew Stemm, MD, David Suster, MD, et al, Typical and Atypical Granular Cell Tumors of Soft Tissue: A Clinicopathologic Study of 50 Patients, *American Journal of Clinical Pathology*, August 2017,148(2):161–166.
2. Abrikosoff A: Uber Myome, ausgehend von der quergestreifenwillkuerlichenmuskulatur. *Virchows Arch Pathol Anat.* 1926, 260: 215-233.
3. Fisher ER, Wechsler H. Granular cell myoblastoma as misnomer. EM and histochemical evidence concerning its Schwann cell derivation and nature (granular cell schwannoma) *Cancer.* 1962;15: 936–936.
4. Cohen J, LeBoit P. Granular cell tumor. *PathologyOutlines.com website.* <https://www.pathologyoutlines.com/topic/skintumornonmelanocyticgct.html>. Accessed August 7th, 2023.
5. Hemant Kumar Singh, ArpithaAnantharaju, Sarath Chandra Sistla. Granular Cell Tumour. *J CutanAesthet Surg.* 2015 Jul-Sep; 8(3): 181–183.
6. Wei L, Liu S, Conroy J, Wang J, Papanicolau-Sengos A, et al. Whole-genome sequencing of a malignant granular cell tumor with metabolic response to pazopanib. *Cold Spring Harb Mol Case Stud.* 2015 Oct. 1 (1):a000380.
7. Mirza FN, Tuggle CT, Zogg CK, Mirza HN, Narayan D. Epidemiology of malignant cutaneous granular cell tumors: A US population-based cohort analysis using the Surveillance, Epidemiology, and End Results (SEER) database. *J Am Acad Dermatol.* 2018 Mar. 78 (3):490-497.
8. Pareja F, Brandes AH, Basili T, Selenica P, Geyer FC, et al. Loss-of-function mutations in ATP6AP1 and ATP6AP2 in granular cell tumors. *Nat Commun.* 2018 Aug 30. 9 (1):3533.
9. Barrantes PC, Zhou P, MacDonald SM, Ioakeim-Ioannidou M, Lee NG. Granular Cell Tumor of the Orbit: Review of the Literature and a Proposed Treatment Modality. *Ophthalmic PlastReconstr Surg.* 2022 Mar-Apr 01. 38 (2):122-131.

10. Park J, Cho KJ, Lee J. Retinal granular cell tumor: a case report. *BMC Ophthalmol.* 2021 Dec 27. 21 (1):453.
11. Davis R, Deak K, Glass CH. Pulmonary Granular Cell Tumors: A Study of 4 Cases Including a Malignant Phenotype. *Am J Surg Pathol.* 2019 Oct. 43 (10):1397-1402.
12. Li P, Yang Z, Wang Z, Zhou Q, Li S, Wang X, et al. Granular cell tumors in the central nervous system: a report on eight cases and a literature review. *Br J Neurosurg.* 2016 May 18. 1-8.
13. Aragüés IH, Domínguez MC, Blanco VP, Zubicaray BE, Fernández RS. LEOPARD syndrome and multiple granular cell tumors: An underreported association?. *Indian J Dermatol Venereol Leprol.* 2016 Jan-Feb. 82 (1):77-9.
14. Dauder Gallego C, Ruiz Zafra J, Stanescu RI, Trujillo Coronado M, Mena Rosón MA, Fahandezh-Saddi Díaz H. Granular Cell Tumor of the Hand: Unusual Malignancy of a Previous Benign Lesion: A Case Report. *JBJS Case Connect.* 2021 Aug 4. 11 (3).
15. Caroppo D, Salerno G, Merolla F, Meselella M, Ilardi G, Pagliuca F, et al. Coexistent Squamous Cell Carcinoma and Granular Cell Tumor of Head and Neck Region: Report of Two Very Rare Cases and Review of the Literature. *Int J Surg Pathol.* 2017 Aug 1. 1066896917724513.
16. Mete, O., Lopes, M.B. Overview of the 2017 WHO Classification of Pituitary Tumors. *Endocr Pathol* 28, 228–243 (2017). <https://doi.org/10.1007/s12022-017-9498-z>
17. Sekimizu M, Yoshida A, Mitani S, et al. Frequent mutations of genes encoding vacuolar H⁺-ATPase components in granular cell tumors. *Genes Chromosomes Cancer.* 2019 Jun. 58 (6):373-380.
18. Kobara H, Mori H, Rafiq K, et al. Evaluation of gastric submucosal tumors using endoscopically visualized features with submucosal endoscopy. *Oncol Lett.* 2014 Jul;8(1):161-168.
19. Loncar B, Marjanović K, Pauzar B, Staklenac B. Granular cell tumor — clinically presented as lymphadenopathy. *Coll Antropol.* 2010;34: 261–3.
20. Leyva AM, Husein-Elahmed H, Aneiros-Fernandez J, Almodovar-Real A, Ruiz-Carrascosa JC. Case for diagnosis. *An Bras Dermatol.* 2014;89: 523–4.
21. Rao S, Rajendiran S, Surendran P, Venkata SP, Prathiba D. Granular cell tumor in inguinal region: A case of mistaken identity on cytology. *J Cytol.* 2012;29: 60–2.
22. Kanat O, Yalcinkaya U, Akbunar T, Kurt E, Evrensel T, Manavoglu O. Gemcitabine plus paclitaxel may be a promising chemotherapy regimen for metastatic granular cell tumour. *Clin Oncol (R Coll Radiol)* 2008;20:93–6.
23. Aoyama, K., Kamio, T., Hirano, A. et al. Granular cell tumors: a report of six cases. *World J Surg Onc* 10, 204 (2012). (Published online: <https://doi.org/10.1186/1477-7819-10-204>)
24. Rejas RA, Campos MS, Cortes AR, Pinto DD, de Sousa SC. The neural histogenetic origin of the oral granular cell tumor: an immunohistochemical evidence. *Med Oral Patol Oral Cir Bucal.* 2011 Jan 1. 16(1):e6-10.
25. Richmond AM, La Rosa FG, Said S. Granular cell tumor presenting in the scrotum of a pediatric patient: a case report and review of the literature. *J Med Case Rep.* 2016 Jun 4. 10 (1):161.
26. Yilmaz AD, Unlu RE, Orbay H, et al. Recurrent granular cell tumor: how to treat. *J Craniofac Surg.* 2007 Sep. 18(5):1187-9
27. Habeeb AA, Salama S. Primitive nonneural granular cell tumor (so-called atypical polypoid granular cell tumor). Report of 2 cases with immunohistochemical and ultrastructural correlation. *Am J Dermatopathol.* 2008 Apr. 30(2):156-9.
28. Sidwell RU, Rouse P, Owen RA, et al. Granular cell tumor of the scrotum in a child with Noonan syndrome. *Pediatr Dermatol.* 2008;25:341–343.
29. An JS, Han SH, Hwang SB, et al. Granular cell tumors of the abdominal wall. *Yonsei Med J.* 2007; 48:727–730.