

## Original Article



# Acute Acalculous Cholecystitis in Dengue Fever with Raised Transaminase

Kazi Shihab Uddin<sup>1</sup>, Syed Minhaj Uddin Ahmed<sup>2</sup>, Sabera Sultana<sup>3</sup>,  
Habiba Akter<sup>4</sup>, Marufa Rehnuma Azad<sup>5</sup>, Rakibul Hasan<sup>6</sup>.

### Abstract

**Background:** Dengue fever is a viral fever classically characterized by high-grade temperature, headache, ocular pain, sternal pain, muscle & joint pain, nausea, vomiting and sometimes rash. Apart from above stated clinical features, there may be hepatitis, ascites, cholecystitis, pleural effusion, etc. which are confirmed by investigations.

**Objective:** To establish the fact that acute acalculous cholecystitis is not uncommon in dengue fever. Raised transaminases are good indicators for further investigation and to find out the prognosis and management of acute acalculous cholecystitis in dengue fever.

**Materials and Methods:** A total of 100 patients with confirmed dengue fever who were admitted to Khwaja Yunus Ali Medical College Hospital, were selected randomly for one month. Among them, 44 patients had undergone for ultrasound of the whole abdomen because of nausea, vomiting, abdominal pain and raised transaminases.

**Results:** Acute acalculous cholecystitis was detected in 20 patients (20%) with confirmed dengue fever. These patients with acute acalculous cholecystitis were treated conservatively and they recovered completely without any surgical intervention.

**Conclusion:** In dengue fever unlike acute pancreatitis or encephalitis, acute acalculous cholecystitis is not uncommon and it is self-limiting and resolved by conservative management.

**Key words:** Dengue Fever (DF), Acute Acalculous Cholecystitis (AAC), Dengue Hemorrhagic Fever (DHF), Dengue Shock Syndrome (DSS), Expanded Dengue Syndrome (EDS).

**Date of received:** 24.07.2023

**Date of acceptance:** 15.11.2023

**DOI:** <https://doi.org/10.3329/kyamcj.v14i04.70193>

**KYAMC Journal. 2024; 14(04): 190-193.**

## Introduction

Dengue fever (DF) has become one of the commonest mosquito borne disease in Bangladesh. Bangladesh has been experiencing worst dengue outbreak in 2023 since the last two decades.<sup>1-3</sup> As of 28 November 2023, the Directorate General of Health Services (DGHS) has reported 310046 hospitalizations and 1,610 deaths occurred in this year.<sup>4</sup> DF is caused by Arbovirus which has got 4 serotypes. Different serotypes have been causing of sudden increase in dengue fever patient specially throughout the monsoon season. This year people are getting affected with the DENV-2 and DENV-3 variants, causing highest rates of infections and death reported by institute of Epidemiology, Disease Control and Research (IEDCR).<sup>5</sup> In our country the period of time from July to October is the ideal climate for Aedes mosquito to breed.

DF like other viral fever is self-limiting and only supportive treatment is needed. The spectrum of dengue fever ranges mild or asymptomatic infection to classical DF, dengue hemorrhagic fever (DHF) and dengue shock syndrome (DSS).<sup>6</sup> The most severe form is expanded dengue syndrome (EDS) which is like “bolt from blue” where patient develop sudden shock with multiorgan failure. The classical DF starts with sudden high-grade fever, severe headache, retro-orbital pain, body ache especially spinal pain. Patients also suffer from symptoms like nausea, vomiting, abdominal pain and dehydration.<sup>7,8</sup>

After the febrile phase is over patient may progress to DHF where there is evidence of plasma leakage such as ascites, pleural effusion, dependent edema. While DHF progresses to

1. Associate Professor of Medicine, Khwaja Yunus Ali Medical College and Hospital, Enayetpur, Sirajganj, Bangladesh.
2. Assistant Professor of Biochemistry, Khwaja Yunus Ali Medical College and Hospital, Enayetpur, Sirajganj, Bangladesh.
3. Associate Professor of Biochemistry, Khwaja Yunus Ali Medical College and Hospital, Enayetpur, Sirajganj, Bangladesh.
4. Assistant Professor of Physiology, Khwaja Yunus Ali Medical College and Hospital, Enayetpur, Sirajganj, Bangladesh.
5. Medical Officer, Department of Anesthesia, Mymensingh Medical College and Hospital, Mymensingh, Bangladesh.
6. Assistant Registrar, Department of Medicine, Khwaja Yunus Ali Medical College and Hospital, Enayetpur, Sirajganj, Bangladesh.

**Corresponding author:** Kazi Shihab Uddin, Associate Professor of Medicine, Khwaja Yunus Ali Medical College and Hospital, Enayetpur, Sirajganj, Bangladesh. **Cell:** +8801714200690, **E-mail:** kazishihabuddin@gmail.com

shock then it is called DSS. The occurrence of thrombocytopenia is immune mediated which does not have diagnostic importance for different type of dengue. EDS patient presents with sudden shock but usually associated with multiorgan involvement such as pneumonitis, encephalitis/meningitis, myocarditis/pancreatitis.<sup>9</sup> However, AAC may present as an atypical feature in DF irrespective of spectrum and complications of DF.<sup>10,11</sup>

### Materials and Methods

In this randomized control study, a total of 100 admitted confirmed dengue patients were included. Clinically suggested dengue patients from outpatient department and inpatient department have undergone diagnostic test for dengue fever. Clinically suggestive and confirmed dengue patients by dengue NS1, dengue IgM and IgG and CBC were included in this study irrespective of age and sex. Among these patients the specific group who were suffering from severe abdominal pain, nausea, vomiting, low appetite and/ altered LFT was enrolled for ultrasound of whole abdomen with real time scanner. Diagnosis of AAC was made by clinical, biochemical and sonographic findings. Patients having history of gall stone disease or patients suffering from chronic cholecystitis were excluded from this study. Also, patients having evidence of chronic liver disease, chronic hepatitis and ultrasound evidence of pancreatitis were excluded from this study. Patients who were diagnosed AAC managed by supportive treatment with appropriate intravenous fluid, broad spectrum antibiotics, antipyretics, platelet transfusion if needed. Regular monitoring for further development of any complication and follow up was done routinely until complete recovery.

#### Data analysis

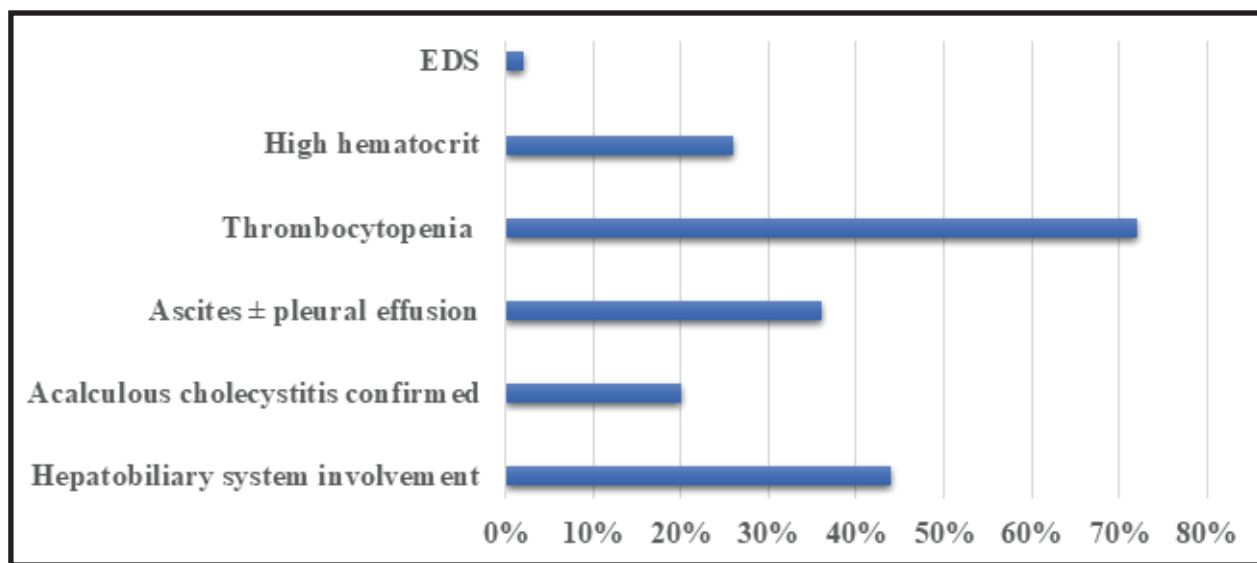
Statistical analyses and data visualization were done in MS Office Excel 2016 (Microsoft, Washington, USA).

### Results

Among the 100 selected patients, 54 patients were suffering from severe nausea, vomiting, abdominal pain and dyspepsia. Around 44 patients from the above-mentioned group had raised liver transaminases. These 44 patients underwent for ultrasound of whole abdomen. On ultrasound 20 patients had AAC (Figure 2). Positive findings were inflamed and swollen gall bladder wall without any stone inside. However, around 36 patients had either ascites or pleural effusion or both. So, we categorized them as DHF. Around 72 patients were suffering from thrombocytopenia and 26 patients had a high hematocrit level during admission. Out of these only 3 cases needed platelet transfusion. Only 2 cases were diagnosed with EDS who were needed intensive care unit (ICU) support (Table I and Figure -1)

**Table I:** Hematological and Radiological outcome in Dengue fever patients.

	No of patient
Total cases	100
Clinically suggestive of hepatobiliary involvement	44
Ultrasound of the whole abdomen was done	44
Acalculous cholecystitis confirmed	20
Ascites ± pleural effusion	36
Thrombocytopenia	72
High hematocrit	26
EDS	02



**Figure 1:** Graphical presentation of hematological & radiological outcome of DF patients

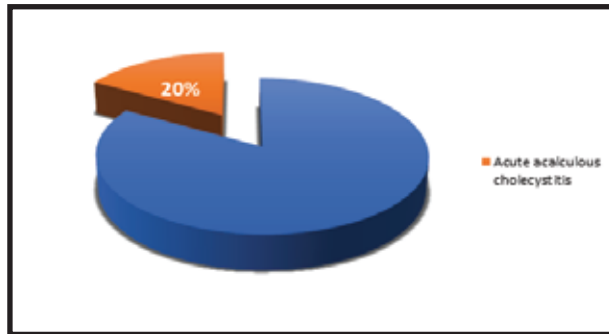


Figure 2: Percentages of dengue fever patients suffering from acute acalculous cholecystitis

The patients who were diagnosed with AAC were treated by non-surgical supportive treatment such as intravenous I/V fluid, injectable analgesics (apart from NSAIDs or corticosteroids), injectable antispasmodic and gradual introduction of oral diet. Once there was reasonable clinical improvement ultrasound of hepatobiliary system was reviewed to see sonographic improvement of gall bladder wall.

## Discussion

Apart from the classical features of DF, there are atypical features that include hepatitis, acalculous cholecystitis, pancreatitis, encephalitis and myocarditis etc. These atypical features have been reported in much higher number in the recent years.<sup>10,12</sup> It is important to accomplish relation of these atypical features with severity of dengue patient.

Our study findings showed in a clinically suggestive dengue patient who presents additionally with abdominal pain, nausea, vomiting and high liver transaminases, AAC should be suspected. Cases should be confirmed by ultrasound of whole abdomen and positive findings are inflamed, thickened and edematous gall bladder wall.<sup>11,13</sup>

In our study we observed 20% of dengue patients having AAC. This AAC in DF is neither uncommon nor atypical. Although this number is noteworthy, the actual pathogenesis is unclear. However, cholestasis and increased bile viscosity may be the cause. Increased vascular permeability which causes leakage of plasma and effusion in the gall bladder wall. This effusion is serous in nature with high albumin content.<sup>14</sup> Similar study was carried out in India showed that 38.8% DF patients had AAC without any complication.<sup>15</sup>

However, all of these patients with AAC had complete recovery by supportive and symptomatic treatment only. None of them required surgery. Additional important finding was occurrence of AAC was not associated with severity of DF. Therefore, we found AAC in DF is rather expected with involvement of hepatobiliary system and they can be managed with success. There is scope for further study including large sample size. Cases may be more randomized by doing ultrasound in all patients of study sample. It is also important to do comparative study of DF patient with AAC in outpatient group and admitted inpatient group. From these studies we may find the group of DF patients who need investigation for AAC.

## Conclusion

In dengue patient AAC is not uncommon and it is self-limiting with conservative treatment. Maintenance of fluid and electrolytes balance is very important and platelet transfusion whenever necessary. In our study surgical intervention i., e. cholecystectomy was not needed at all. Role of abdominal ultrasound is pivotal for diagnosis of AAC. After treatment the ultrasound findings of gall bladder reverse back to normal. The question remains whether we should perform ultrasound of whole abdomen in every outpatient and inpatient cases of confirmed DF.

## Acknowledgement

The authors are thankful to the doctors and staffs from the Department of Medicine, Radiology and imaging and laboratory services at Khwaja Yonus Ali Medical College hospital who helped to conduct this study. The authors are grateful to the respondents who willingly participated in this research endeavor.

## References

1. Paul, Ruma (5 August 2023). "Bangladesh grapples with record deadly outbreak of dengue fever". Reuters. Retrieved 5 August 2023. Available at <https://www.reuters.com/world/asia-pacific/bangladesh-grapples-with-record-deadly-outbreak-dengue-fever-2023-08-05/>
2. Burki, Talha (5 August 2023). "Bangladesh faces record dengue outbreak". *The Lancet*. 402 (10400):439.
3. Paul, Ruma (2023-10-02). "Bangladesh dengue deaths top 1,000 in worst outbreak." Reuters. Retrieved 2023-10-02 Available at <https://www.reuters.com/business/health-care-pharmaceuticals/bangladesh-dengue-deaths-top-1000-worst-outbreak-2023-10-02>.
4. Dengue Press Release-28/11/2023, Health Emergency Operation Center and Control Room, MIS, Directorate General of Health Services, Mohakhali, Dhaka. 28 November 2023. Available at [https://old.dghs.gov.bd/images/docs/vpr/20231011\\_dengue\\_all.pdf](https://old.dghs.gov.bd/images/docs/vpr/20231011_dengue_all.pdf)
5. Alam, Helemul (19 June 2023). "Dengue 'Den-2' variant more prominent now". *The Daily Star*. Retrieved 13 August 2023. Available at <https://www.thedailystar.net/news/bangladesh/news/dengue-den-2-variant-more-prominent-now-3350001>
6. Khan E, Siddiqui J, Shakoor S, Mehraj V, Jamil B, Hasan R. Dengue outbreak in Karachi, Pakistan, 2006: experience at tertiary care centre. *Trans R Soc Trop Med Hyg*. 2007; 101:1114-1119.
7. Kalayanaraj S, Vaughn DW, Nimmannitya S, Green S, Suntayakorn S, Kunentrasai N, et al. Early clinical and laboratory indicators of acute dengue illness. *J Infect Dis*. 1997;176:313-321.

8. Cobra C, Rigau PZ, Kuno G, Vorndam V. Symptoms of dengue fever in relation to host immunologic response and virus serotype, Puerto Rico, 1990-1991. *Am J Epidemiol.* 1995;142:1204-1211.
9. Nimmannitya S, Thisyakorn U, Hemrichant V. Dengue haemorrhagic fever with unusual manifestations. *South East Asian J trop Med.* 1987;18: 398-406.
10. Sood A, Midha V, Sood N, Kausha V. Acalculous cholecystitis as an atypical presentation of dengue fever. *Am J Gastroenterol.* 2000;95(2):3316-3317.
11. Prasad A, Yasmeen M, Prasad GS. Study of acute acalculous cholecystitis as an atypical manifestation in dengue fever. *Int J Med Sci Public Health.* 2015; 4:1231-1234.
12. George R, Liam CK, Chua CT, Lam SK, Pam T, Geethan R, et al. Unusual clinical manifestations of dengue virus infection. *South east Asian J Trop Med Public Health.* 1988;19: 585-590.
13. Gulati S, Maheshwari A. Atypical manifestations of dengue. *Trop Med Int Health.* 2007;12(9):1087-1095
14. Gubler DJ, Kun G, Sather GE, Velez M, Oliver A. Mosquito cell cultures and specific monoclonal antibodies in surveillance for dengue virus. *Am J Trop Med Hyg.* 1984; 33:158-165.
15. Manish chandey, Harjot Kour, Sukhjeet Kaur. Acute acalculous cholecystitis in dengue fever patients. *Int J Adv Med.* 2017; 4(2): 375-377.