

**ORIGINAL ARTICLE**DOI: <https://doi.org/10.3329/mediscope.v9i1.58522>**Patients' experiences of Submucous Resection operation under local anaesthesia with deep sedation*****MK Paul¹, B Islam²****Abstract**

Background: Submucous resection (SMR) operation can be done under local or general anaesthesia. SMR under local anaesthesia with deep sedation is a safe, simple, cost-effective and reliable procedure for patients in developing countries like Bangladesh. **Objective:** To observe the experiences of patients regarding SMR under local anaesthesia (L/A) with deep sedation. **Methods:** After taking proper approval from Institutional Review Board, fifty (50) cases were selected for doing SMR operation which was done with maintaining all aseptic precautions in Mymensingh Medical College Hospital from July 2013 to July 2014. Assessment of effectiveness under LA was done after completion of SMR. **Results:** In our study, there were 26 (52%) male and 24 (48%) female patients. Majority of the patients (70%) belonged to the age range of 18-37 years. 32 patients (64%) felt the procedure to be completely painless (Grade 1), and 16 patients (32%) complained of slight discomfort (Grade 2). None of the patients experienced moderate or severe discomfort. **Conclusion:** SMR operation under L/A with deep sedation is very simple, safe, cost effective, less time consuming and highly acceptable procedure to the patient and the surgeon.

Keywords: SMR operation, local anaesthesia.

Introduction

Nasal obstruction causing difficulty in breathing is one of the most common problems bringing a patient to the ENT out-patient department and septal deviation is a frequent structural etiology.¹ A physiological septum deviation is defined as a deviation without subjective or objective reduction of the nasal breathing. Accordingly, a pathological septum deviation has to be defined as a septum deviation with subjective reduction of nasal breathing. Thus, the problem of precisely defining the septum deviation is pretty evident.² Septal pathology can be deviation, dislocation or spur which can involve cartilage or both cartilage and bone. Untreated deviations resulting in

functional sinus problems opened the doors for functional sinus surgery.³ Surgical correction of septal deviation is the third most common head and neck procedure in the United States and it generally is performed to improve the quality of life.⁴

The submucous resection (SMR) was first described by Freer in 1902 and by Killian in 1904. The preservation of bilateral muco-perichondrial flaps and cartilaginous supports were considered essential in their technique.^{4,5} Most of the surgeons adopted Killian's technique with preservation of caudal and dorsal struts of the septal cartilage to minimise the complications.⁶ The major complications of this procedure are

1. Dr. Mitun Kumar Paul, Associate Professor and Head, Department of ENT, Gazi Medical College & Hospital, Khulna.
Email: dr.mkpaul@yahoo.com.

2. Dr. Baishakhi Islam, Associate Professor and Head, Department of Pharmacology & Therapeutics, Gazi Medical College, Khulna.

septal perforation, septal hematoma, bleeding and crust formation, saddling of nose and retraction of the columella and residual deviation.^{4,5} Submucosal resection of the septum aims to remove or straighten part(s) of the deviated cartilage and bone of the nasal septum. The type of surgery used depends on the type of deviation. If the deviation lies posterior to the Cottle's line then submucosal resection of septum is preferred.¹ Nasal Septal surgery performed under local anaesthesia with pethidine sedation resulted in less surgical bleeding, less postoperative pain, a shorter recovery period and a higher level of patients' satisfaction. Moreover, local anaesthesia does not carry with it the risks of general anaesthesia in terms of aspiration and other respiratory problems. Recent evidence suggests that lignocaine with adrenaline is safe.³ The purpose of this study was to obtain experiences of patients undergoing SMR with deep sedation for symptomatic deviated nasal septum (DNS).

Methodology

Fifty (50) patients of symptomatic DNS were selected for SMR operation under local anaesthesia that came to the out-patient department of ENT in Mymensingh Medical College Hospital from July 2013 to July 2014 after taking proper approval from institutional review board. Patients of both genders having ages more than 17 years were included in the study after taking informed written consent. Patients with DNS who needed septo-rhinoplasty and patients with any acute or chronic disease in the nose, paranasal sinuses or ear and throat and also with any systemic disease like diabetes mellitus, hypertension, tuberculosis and bleeding or coagulation disorders were excluded from this study.

Operation was done under L/A with deep sedation. After introducing an intravenous channel (I/V) 1000 cc of 5% dextrose saline was pushed in drip and the I/V channel was maintained during pre and post operative periods. Injection pethidine (1mg/Kg Body weight) was given, 50% in I/V route and 50% in I/M route. Pethidine was diluted 4 times while pushing through the I/V channel. With all aseptic precaution, 2% xylocaine and 1:50,000 adrenaline was infiltrated in sub-perichondrial

planes of nasal septum. A curvilinear incision was given at the mucocutaneous junction on left side of the septum. It cuts only mucosa and perichondrium. Then mucoperichondrial and periosteal flap were elevated. Cartilage was incised just posterior to the first incision. The opposite mucoperichondrium and periosteum were elevated with the elevator being passed through the cartilage incision. Then cartilage and bone were removed with preserving a strip of cartilage about 1cm wide along the dorsal and caudal border of the septum to prevent collapse of the bridge or retraction columella. Then anterior nasal packing was given with Ribbon gauze smeared with an antibiotic ointment and nasal dressing was applied and kept for 24 hours.

A few hours after the procedure, the patients were asked to grade the effectiveness of the L/A, on a subjective scale of 1-4. A grading of 1 being 'painless', 2 being 'slight discomfort', 3 being 'moderate discomfort' and 4 being 'severe discomfort' was categorized. Descriptive statistics were shown as percentage of respective parameter.

Results

Patients recovered normally and their outcomes were reviewed. All the patients tolerated the procedure very well. A total of 50 cases were enrolled in which 26 (52%) were males and 24 (48%) were females as shown in Figure 01. Majority of patients [35 (70%)] was in the age group of 18-37 years followed by 13 (26%) in 38-57 years (Figure 02).

Out of 50 patients, 32 (64%) felt the procedure was completely painless (Grade 1). 16 patients (32%) complained of slight discomfort (Grade 2), only 2 patients (4%) felt discomfort moderately (Grade 3), whereas none of the patients experienced severe discomfort (Grade 4) as shown in (Table 01). None of them asked for operative analgesia or felt any nausea or dizziness. Most of them were discharged on the following day or the day after. The patients were followed up a week later. Regarding relief of nasal obstruction, 36 (72%) patients were 'very satisfied,' 14 (28%) patients were satisfied; and no patient was dissatisfied (Figure 03). Other findings of SMR operation under local anaesthesia are as follows: Bleeding

at the time of surgery was mild; [40-50 ml (measured with gauze piece and amount of blood in the suction bottle)]. The procedure was less time consuming: 30-40 minutes due to no issue of intubation, extubation and recovery like general anaesthesia. Complication rate was negligible but procedure was sometimes painful for some patients.

Gender distribution

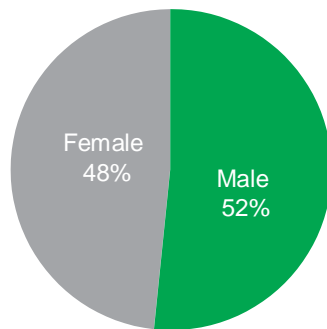


Figure 01: Gender distribution of the patients

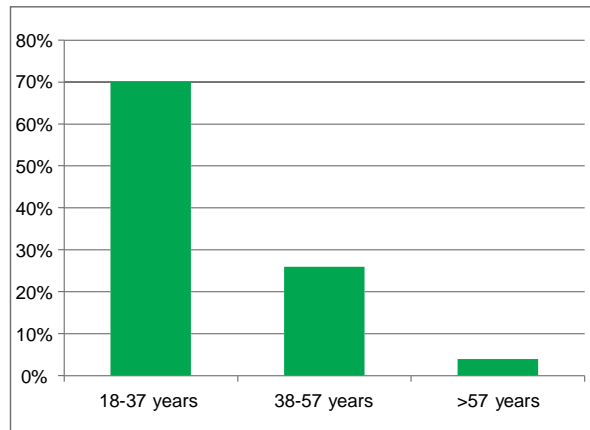


Figure 02: Age distribution of the patients

Table 01: Patients' feelings about the operative procedure

Grading	Patients' feelings	n=50
Grade 1	Painless	32 (64%)
Grade 2	Slight discomfort	16 (32%)
Grade 3	Moderate discomfort	2 (4%)
Grade 4	Severe discomfort	0 (0%)

Relief of nasal obstruction

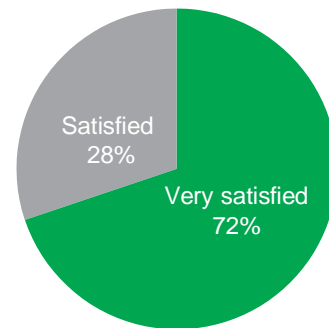


Figure 03: Patients' satisfaction about relief of nasal obstruction

Discussion

SMR under local anesthesia is a better option for relieving nasal obstruction because of short hospital stay, being cheap, less per operative bleeding, no serious complication, no post operative vomiting and hangover effect like general anaesthesia.³

In present study males (52%) were more commonly affected than females (48%). This was comparable to other studies done by Padma et al.¹, Sheikh et al.⁴, and Buckland et al.⁷ where males were more predominant. The possible reason for male predominance may be more environmental exposure and trauma.⁴ Most of the patients in our study belonged to the age group of 18-37 years (70%) which is consistent with other studies.^{1,4,6,7} Majority of the patients (82%) obtained relief of symptoms (nasal obstruction) in a very satisfactory level which is consistent with the results of the studies done by Padma et al.¹ (84%) and Pannu et al. (80%).⁸

Like our observation, SMR operation with local anaesthesia was found to be cost-effective in another study.⁹ Bleeding at the time of surgery was 40-50 ml which is comparatively more than the report of Chand et al.⁶ where 10-15 ml bleeding occur. Total time of procedure is less (30-40 min) which was comparable with other study where operating time ranged from a minimum of 10 min to a maximum of 1 h 55 min, the median being 30 min.¹⁰ and rate of complications was very negligible like other studies.^{3,6} The rationale for this study is based on the fact that SMR is one of the most frequent operations in a developing country like Bangladesh where masses are

struggling below poverty line, economy is the emerging concept while selecting treatment options.

Conclusion

SMR operation under L/A is a simple, reliable, cost-effective, and safe procedure causing very minimal health hazards. As this procedure brings about higher satisfaction for patients, it can be a frequent choice for ENT surgeons in developing countries like Bangladesh.

Acknowledgement

We would like to thank Professor Dr. Md. Mohsin, department of Otolaryngology and Head-Neck surgery, Gazi Medical College Hospital, Khulna for his valuable support. We are Grateful to the respondents who participated in this study. We are also thankful to the Clinical staff who helped to conduct the study.

References

1. Padma K, Prabhakar M. Comparative Study of Septoplasty VS SMR. International Journal of Contemporary Medical Research.2016;3(11):3251–5.
2. Matthias C. Surgery of the nasal septum and turbinates. GMS Curr Top Otorhinolaryngol Head Neck Surg. 2007;6: Doc10.
3. Raahat ZM, Naqvi NU, Raza SN. Submucosal Resection of Nasal Septum under Local Versus General Anaesthesia. Pakistan Journal of Otolaryngology.2014;30: 50-52.
4. Sheikh MS, Rehman AUR, Wakeel N, Yasir. Comparison of Complication in SMR vs Septoplasty. 2017;11(2):537–40.
5. Iqbal K, Khan MI, Amanullah. Submucous resection versus septoplasty: complications and functional outcome in adult patients. Gomal Journal of Medical Sciences. 2011;9(1):23-27.
6. Chand G, Shafiq M, Khan A. The comparative study of submucosal resection of nasal septum under local and general anaesthesia. J Pak Med Assoc.2010; 62(10):1020–22.
7. Buckland JR, Thomas S, Harries PG. Can the sinonasal outcome test (SNOT-22) be used as a reliable outcome measure for successful septal surgery? Clinical Otolaryngology 2003;28:43-473.
8. Pannu KK, Chadha S, Kaur IP. Evaluation of benefits of nasal septal surgery on nasal symptoms and general health. Indian journal of Otolaryngology Head Neck Surgery. 2009;61:59-65.
9. Nanda MS, Kaur M. Comparison of Septoplasty under General Anaesthesia and Monitored Anaesthetic Care with Dexmedetomidine. (IOSR-JDMS.2015; 14(1): 69-73.
10. Georgalas C, Obholzer R, Devesa PM, Sandhu G. Day case septoplasty and unexpected re-admissions at a dedicated day care unit: a 4-year audit. Ann R Coll Surg Engl 2006; 88: 201–206.