

Actinomycosis : An Update

Moniruddin ABM¹, Begum H², Nahar K³

Abstract:

Actinomycosis is a very rare disease caused usually by one of a group of opportunistic otherwise harmless commensals that may be complicated by one or more of another group of copathogens. Because of its rarity, there is a chance of missing its diagnosis & proper treatment leading to substantial morbidity & mortality. Maltreated patients are at risk of developing life threatening complications. This article is intended to review the present status of aetiology, pathology, clinical features, complications & management of actinomycosis.

Keywords

Actinomyces israeli, Actinomyces gerencseriae, Actinomyces naeslundii, Actinomyces odontolyticus, Actinomyces viscosus, Actinomyces turicensis, Actinomyces meyeri, Propionibacterium propionicus, Peptostreptococcus, Actinobacillus actinomycetemcomitans, Prevotella, Fusobacterium, Bacteroides, Staphylococcus, Streptococcus, Enterobacteriaceae, actinomycetes.

Introduction:

Actinomycosis was once a common & ultimately fatal disease¹. Now the number has declined since the introduction of antimicrobial agents. The outlook of patients suffering from this infection has improved remarkably. Few physicians see many cases. As patients no longer commonly present advanced disease, actinomycosis has become a more diagnostic challenge². Actinomycosis is a subacute-to-chronic bacterial infection characterized by contiguous spread, suppurative and granulomatous inflammation, and formation of multiple abscesses and sinus tracts that may discharge 'sulfur granules'³. As a disease process, the causative organism can primarily or secondarily invade gum, jaw⁴, neck, pleura, lungs⁵, liver⁶, kidney⁷, appendix⁷, caecum⁷, skin¹, heart⁸, meninges⁹ etc. Even bones like mandible, ribs & vertebra (causing osteomyelitis)¹⁰ are not immune to its invasion. The most common clinical forms of actinomycosis are cervicofacial (ie, lumpy jaw), thoracic, and abdominal¹. In women, pelvic actinomycosis is documented¹¹. Epidural abscesses⁹, Meningitis⁹,

Endocarditis⁸, Pericarditis¹², Pneumonia (Community Acquired¹ or Nosocomia¹⁵), Lung abscess⁵, Bronchiectasis⁵, Empyema Thoracis¹² etc when caused by these organisms remain undiagnosed or if not properly treated would endanger the life of the patient. There are significant morbidities as well.

Aetiology

The causative organisms are non-motile, non-spore forming, non-acid fast, Gram positive pleomorphic, anaerobic-to-microaerophilic filamentous bacterial rods³. The most common ones are¹ *Actinomyces israeli*, *Actinomyces gerencseriae*, *Actinomyces naeslundii*, *Actinomyces odontolyticus*, *Actinomyces viscosus*, *Actinomyces turicensis*, *Actinomyces meyeri*, *Propionibacterium propionicus*. In addition to these microorganisms, almost all actinomycotic lesions contain so-called companion bacteria. The most important of these bacteria is *Actinobacillus actinomycetemcomitans*, followed by *Peptostreptococcus*, *Prevotella*, *Fusobacterium*, *Bacteroides*, *Staphylococcus*, and *Streptococcus* species, and *Enterobacteriaceae*, depending on the location of actinomycotic lesions. These companion bacteria appear to magnify the low pathogenic potential of actinomycetes².

Actinomycosis can affect people of all ages, but the majority of cases are reported in young to middle-aged adults (aged 20-50 yrs)². No racial predilection exists. For unknown reasons, men are affected more commonly than women, with the exception of pelvic actinomycosis¹¹. The reported male-to-female ratio² is 3:1.

Actinomycosis occurs worldwide, with likely higher prevalence rates in areas with low socioeconomic status and poor dental hygiene.

History

Bollinger first reported the yellow granules in jaw masses of cattle in 1877. In 1878, Israel described the first human case. In 1879, Hartz first observed the microscopic appearance of granules of actinomycosis infection¹.

Frequency

Actinomycosis is a rare infection Its exact incidence is not known in Bangladesh. During the 1970s, the reported annual incidence in the Cleveland area of the United States was 1 case per 300,000². Improved dental hygiene and widespread use of antibiotics for various infections probably have contributed to the declining incidence of this disease¹.

1. ABM Moniruddin MBBS, FCPS(S), Consultant, Surgery, General Hospital, Narayanganj.
2. Hamida Begum MBBS, FCPS, Assistant Professor, Deptt. of Gynae & Obs, BSMMU, Dhaka.
3. Khairun Nahar MBBS, FCPS, Assistant Professor, Deptt. of Gynae & Obs, BSMMU, Dhaka.

Pathology

Actinomycetes are prominent among the normal flora of the oral cavity but less prominent in the lower gastrointestinal tract and female genital tract. As these microorganisms are not virulent, they require a break in the integrity of the mucous membranes and the presence of devitalized tissue to invade deeper body structures and cause human illness. Furthermore, actinomycosis generally is a polymicrobial infection, with isolates numbering as many as 5-10 bacterial species². Establishment of human infection may require the presence of such companion bacteria, which participate in the production of infection by elaborating a toxin or enzyme or by inhibiting host defenses. These companion bacteria appear to act as copathogens that enhance the relatively low invasiveness of actinomycetes. Specifically, they may be responsible for the early manifestations of the infection and for treatment failures. Once infection is established, the host mounts an intense inflammatory response (ie, suppurative, granulomatous), and fibrosis may develop subsequently. Infection typically spreads contiguously, frequently ignoring tissue planes and invading surrounding tissues or organs. Ultimately, the infection produces draining sinus tracts. Hematogenous dissemination⁷ to distant organs may occur in any stage of the infection, whereas lymphatic dissemination is unusual.

Cervicofacial actinomycosis

Cervicofacial actinomycosis is the most common manifestation, comprising 50-70% of reported cases. Infection typically occurs following oral surgery or in patients with poor dental hygiene². This form of actinomycosis is characterized in the initial stages by soft-tissue swelling of the perimandibular area. Direct spread into the adjacent tissues occurs over time, along with development of fistulas (sinus tracts) that discharge purulent material containing yellow (ie, sulfur) granules. Invasion of the cranium or the bloodstream may occur if the disease is left untreated.

Thoracic actinomycosis

Thoracic actinomycosis accounts for 15-20% of cases. Aspiration of oropharyngeal secretions containing actinomycetes is the usual mechanism of infection. Occasionally, thoracic actinomycosis may result from the introduction of organisms via esophageal perforation, by direct spread from an actinomycotic process of the neck or abdomen, or via hematogenous spread from a distant lesion. Thoracic actinomycosis³ commonly presents as a pulmonary infiltrate or mass, which, if left untreated, can spread to involve the pleura, pericardium, and chest wall, ultimately leading to the formation of sinuses that discharge sulfur granules.

Actinomycosis of the abdomen and pelvis

Actinomycosis of the abdomen⁷ and pelvis accounts for 10-20% of reported cases. Typically, patients have a history of

recent or remote bowel surgery (eg, perforated acute appendicitis, perforated colonic diverticulitis following trauma to the abdomen) or ingestion of foreign bodies (eg, chicken or fish bones), during which actinomycetes is introduced into the deep tissues. The ileocecal region is involved most frequently, and the disease presents classically as a slowly growing tumor. Diagnosis is usually established postoperatively, following exploratory laparotomy for a suspected malignancy. Involvement of any abdominal organ, including the abdominal wall, can occur by direct spread, with eventual formation of draining sinuses. Actinomycosis of the pelvis most commonly occurs by the ascending route from the uterus in association with intrauterine contraceptive devices (IUCDs). In such cases, an IUCD has been in place for an average of 8 years.

Complications

Osteomyelitis of the mandible, ribs, and vertebrae, CNS disease, including brain abscess; chronic meningitis; actinomycetoma; cranial, epidural, and subdural infection; and spinal epidural infection, Hepatic actinomycosis, Renal actinomycosis, Endocarditis⁸, Pericarditis¹², Pneumonia (Community Acquired¹ or Nosocomial⁵), Lung abscess⁵, Bronchiectasis⁵, Empyema Thoracis¹² etc. In addition to its serious nature of organ involvement, it can complicate other operations or situations like hip prosthesis infection¹³, septic arthritis¹⁴, endodontic infection¹⁵, IUD infection¹⁶, post-operative viscous endophthalmitis¹⁷, etc. Opportunistic actinomycotic infection has been reported in osteoradionecrosis¹⁸ in patients having head & neck cancer. Disseminated actinomycosis¹⁹ by *Actinomyces meyeri* & *Actinobacillus actinomycetemcomitans* has also been reported.

Clinical Features

1. History taking²⁰

For Cervicofacial actinomycosis (ie, lumpy jaw): History of dental manipulation or trauma to the mouth, poor oral hygiene, dental caries, or periodontal disease; local tissue damage caused by neoplasm or radiation treatment, or of painless or occasionally painful soft-tissue swelling involving the submandibular or perimandibular region; over time, multiple sinuses drain pus containing sulfur granules; tendency to remit and recur, or of reddish or bluish discoloration of the skin overlying the lesion or of chewing difficulties (ie, with involvement of mastication muscles)

For Thoracic actinomycosis: History of aspiration (Risk factors include seizure disorder, alcoholisms, and poor dental hygiene.), or of dry or productive cough, occasionally blood-streaked sputum, shortness of breath, chest pain, or of fever, weight loss, fatigue, anorexia.

For Abdominal actinomycosis: History of abdominal surgery, perforated viscus, mesenteric vascular insufficiency, or ingestion of foreign bodies (eg, fish or

chicken bones), or of Nonspecific symptoms: The most common nonspecific symptoms are low-grade fever, weight loss, fatigue, or of change in bowel habits, or of vague abdominal discomfort, or of nausea, or of vomiting, or of sensation of a mass.

For Pelvic actinomycosis: History of IUCD, or of lower abdominal discomfort, abnormal vaginal bleeding or discharge.

2. Physical findings²⁰:

For Cervicofacial actinomycosis: Tender or nontender woody hard multiple nodular lesions, usually located at the angle of the jaw, multiple abscesses, and multiple sinuses that open onto the cheek or submandibular area, sulfur granules in the exudate, typical absence of lymphadenopathy, with or without trismus & fever.

For Thoracic actinomycosis: Fever, cachexia, abnormal breath sounds, cough (dry or productive of purulent sputum), hemoptysis, sinus tracts with drainage from the chest wall (ie, pleurocutaneous fistula)

For Abdominal actinomycosis: Scar(s) from antecedent abdominal surgery, low-grade fever and cachexia (variably present), mass most often located in the right lower quadrant, less frequently in the left lower quadrant; mass typically firm-to-hard in consistency, nontender, often fixed to underlying tissue, sinus tracts with drainage from either the abdominal wall (ie, peritoneocutaneous fistula) or the perianal region

For Pelvic actinomycosis: Pelvic mass, menometrorrhagia, other manifestations, as in abdominal actinomycosis.

Differential Diagnoses

Abdominal abscess, Lung cancer, Adnexal tumours, Non-Hodgkin's Lymphoma, Appendicitis, Small & Large intestinal malignancy, Blastomycosis, Nocardiasis, Brain abscess, Epidural abscess, Pelvic Inflammatory Disease, Aspiration pneumonia, Bacterial pneumonia, Fungal pneumonia, Crohn's disease, Diverticulitis, Tuberculosis, Lung abscess, Liver abscess, Uterine cancer, Any abdominal mass^{1,2,20}

Laboratory Studies

(A) CBC count: Anemia and mild leukocytosis are common².

(B) Erythrocyte sedimentation rate (ESR) and C-reactive protein (CRP) levels are often elevated².

(C) Chemistry results usually are normal, with the exception of a frequently elevated alkaline phosphatase level in hepatic actinomycosis²⁰.

(D) Organism cultures²¹

(a) Because actinomycosis is difficult to diagnose based on the typical clinical features, direct identification and/or

isolation of the infecting organism from a clinical specimen or from sulfur granules is necessary for definitive diagnosis in most cases.

a. Acceptable specimen material is obtained from draining sinuses, deep needle aspirate, or biopsy specimens; swabs, sputum, and urine specimens are unacceptable or inappropriate.

b. Prompt transport of the specimens to the microbiology laboratory is necessary for optimal isolation of actinomycetes, preferably in an anaerobic transport device.

c. A Gram-stained smear of the specimen may demonstrate the presence of beaded, branched, gram-positive filamentous rods, suggesting the diagnosis of actinomycosis.

d. Cultures should be placed immediately under anaerobic conditions and incubated for 48 hours or longer; the isolation and definitive identification of actinomycetes may require 2-3 weeks.

e. Nucleic acid probes and polymerase chain reaction (PCR) methods are being developed for more rapid and more accurate identification.

f. Antimicrobial susceptibility testing is not indicated in the management of actinomycosis, partly because of their predictable antibiogram.

(b) The preliminary diagnosis of actinomycosis also can be made by examining sulfur granules²⁰. Granules should be crushed between 2 slides, stained with 1% methylene-blue solution, and examined microscopically for features characteristic of actinomycetes.

(c) Serologic diagnosis: Current serologic tests have no role in diagnosing actinomycosis.

Papanicolaou test^{11,17}:

a. The relationship between a Papanicolaou test that is positive for actinomycete-like organisms and the eventual development of pelvic actinomycosis is unclear.

b. The prevalence of smears positive for *Actinomyces* organisms in women who use IUCDs is approximately 7%.⁵

c. Because of the lack of sensitivity and specificity and low positive predictive value, the prognostic significance of detecting *Actinomyces* organisms is minimal in the absence of concomitant symptoms.⁵

Imaging Studies: Chest X-ray & CT Scan

A chest radiograph²⁰ may reveal a poorly defined mass or pneumonitis or cavitary lesion, with or without pleural involvement. Hilar adenopathy is uncommon. The presence of a masslike lesion that extends across fissures or pleura, invades into the adjacent chest wall or thoracic vertebrae, or causes local destruction of the ribs or sternum suggests thoracic actinomycosis.

CT scanning²² (irrespective of the anatomic area of involvement) usually reveals an infiltrative mass with focal areas of decreased attenuation that enhance with contrast. This infiltrative mass tends to invade surrounding tissues. Surrounding lymphadenopathy is uncommon.

Sometimes Colonoscopy, CT scans are combinedly required for diagnosis²²

FNAC & Open biopsy

CT scan or ultrasound-guided fine-needle aspiration and/or biopsy^{3,20,22} have been used successfully to obtain clinical material for diagnosis of actinomycosis.

Surgery²⁴ (eg, thoracotomy with open lung biopsy, exploratory laparotomy) may be required for diagnostic purposes.

Histologic Findings

Actinomycosis is characterized by mixed suppurative and granulomatous inflammatory reactions, connective-tissue proliferation, and the presence of sulfur granules^{1,2,20}.

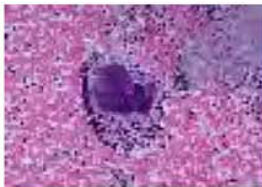


Fig. A- Actinomycosis in Endometrial tissue

The sulfur granules are nearly pathognomonic for actinomycosis, although similar findings have been reported with infections caused by *Nocardia brasiliensis*, *Streptomyces madurae*, and *Staphylococcus aureus* presenting as botryomycosis. The granules are approximately 0.1-1 mm in diameter and may be seen with the naked eye as yellowish particles.

Microscopically, the granules manifest a cauliflower-like shape at low magnification; at higher magnification (X100), when the particle has been pressed between slide and cover slip, a clump of filamentous actinomycete microcolonies surrounded by polymorphonuclear neutrophils (PMNs) can be observed. Gram stain renders these microcolonies visible as gram-positive, intertwined branching filaments, with radially arranged, peripheral hyphae. Coexisting with them are the companion bacteria, which are gram-positive and gram-negative cocci and rods.

Treatment

Medical treatment:

In most cases of actinomycosis, antimicrobial therapy^{1,2,20} is the only treatment required, although surgery can be adjunctive in selected cases. Penicillin G is the drug of choice for treating infections caused by actinomycetes.

High-dose penicillin [Adult: Penicillin G - 12-24 million U/d IV by continuous infusion or in divided doses q4h for 1-2

wk, then switch to PO (penicillin VK) for 6-12 mo] administered over a prolonged period (6 months to 1 year) is the cornerstone of therapy for actinomycosis. Success with shorter courses of therapy (<6 mo) has been reported, especially in cervicofacial actinomycosis. Ultimately, the treatment duration should be tailored to the individual patient based on clinical and radiographic response. Patients should be monitored more closely if shorter treatment durations are considered.

The risk of actinomycetes developing penicillin resistance appears to be minimal. Lack of a clinical response to penicillin usually indicates the presence of resistant companion bacteria, which may require modification of the antibiotic regimen (ie, addition of an agent that is active against these copathogens).

Alternative to Penicillins if the patient is hypersensitive to penicillin or the causative organisms are resistant to Penicillin are Ceftriaxone (Adult: 2 g IV/IM q12-24h; not to exceed 4 g/d), Imipenem/Cilastin (Adult: 500 mg-1000mg IV q8h; not to exceed 4 g/d), Clindamycin (Adult: 600 mg IV q8h, or 150 - 300 mg PO q8h), Amoxicillin/Clavulanic acid (Adult: 500 mg PO q8h, or 875 mg PO q12h), Doxycycline (Adult: 100 mg PO/IV q12h), Tetracycline, Lincomycin, Macrolides (erythromycin, Carbomycin, Spiramycin, Oleandomycin) – all these are effective. But the sensitivity should be checked in the laboratory³. Recalcitrant actinomycosis sometimes need treatment with ciprofloxacin²³. Antibiotics that possess no activity against *Actinomyces* species include metronidazole, aminoglycosides, aztreonam, co-trimoxazole (TMP-SMX), penicillinase-resistant penicillins (eg, methicillin, nafcillin, oxacillin, cloxacillin), and cephalexin. The data concerning the fluoroquinolones (ciprofloxacin, levofloxacin, moxifloxacin) are limited; however, treatment success has been cited in case reports

Surgical treatment:

Attempts are made to cure actinomycosis, including extensive disease, with aggressive antimicrobial therapy alone initially. Surgery is indicated to take a biopsy specimen, to drain abscesses, to extirpate (wide excision) a fibrotic sinus tract (not responsive to conservative treatment) or a recalcitrant fistula tract, to decompress or remove an intra-cranial or intraspinal Space Occupying Lesion, to remove severely damaged segment of lung or liver, relieving obstruction (eg, when actinomycotic lesions compress the ureter)²⁰, & to repair a defect, or to rule out a Bronchogenic carcinoma etc²⁴.

Probenecid can increase effects; coadministration of tetracyclines can decrease effects

Follow-up

Follow up should be adequate & meticulous to have a complete cure of the disease^{1,2,20}.

Prophylaxis:

Maintenance of good oral hygiene and adequate regular dental care are important. Patients and physicians alike should be aware of the increased risk of infection associated with insertion of IUCD^{2,11,16,20}.

Prognosis

The availability of antibiotics has greatly improved the prognosis for all forms of actinomycosis¹. At present, cure rates are high and neither deformity nor death is common. When actinomycosis is diagnosed early and treated with appropriate antibiotic therapy, the prognosis is excellent. The more advanced and complicated actinomycotic forms require aggressive antibiotic and surgical therapy for optimal outcome; however, deaths can occur despite such therapy^{20,24}.

Conclusion:

As it is an endogenous disease, there is no risk of person to person transmission. This is an important message for health personnels & patient attendants et relatives. To minimize delays in diagnosis, actinomycosis should be considered in the differential diagnoses of any inflammatory lesion of subacute or long-term nature.

References:

- David J. M. Haldane. Community Acquired Pneumonia. In: Springer US. Medicine 2007. 53:827-840.
- Weese WC, Smith IM. A study of 57 cases of actinomycosis over a 36-year period. A diagnostic "failure" with good prognosis after treatment. Arch Intern Med. Dec 1975; 135(12):1562-8.
- De Montpreville VT, Nashashibi N, Dulmet EM. Actinomycosis and other bronchopulmonary infections with bacterial granules. Ann Diagn Pathol. Apr 1999;3(2):67-74.
- Lerner PI: The lumpy jaw. Cervicofacial actinomycosis. Infect Dis Clin North Am 1988;2:203.
- Court C.A, Garrard C.S. 1992. Nosocomial pneumonia in the intensive care unit – mechanism & significance. Thorax 47: pp 465-473.
- Felekouras E, Menenakos C, Griniatsos J, et al. Liver resection in cases of isolated hepatic actinomycosis: case report and review of the literature. Scand J Infect Dis. 2004;36(6-7):535-8.
- Cintron JR, Del Pino A, Duarte B, Wood D. Abdominal actinomycosis. Dis Colon Rectum. Jan 1996;39(1):105-8.
- Huang KL, Beutler SM, Wang C. Endocarditis due to Actinomyces meyeri. Clin Infect Dis. Oct 1998;27(4):909-10.
- Yung BC, Cheng JC, Chan TT, et al. Aggressive thoracic actinomycosis complicated by vertebral osteomyelitis and epidural abscess leading to spinal cord compression. Spine. Mar 15 2000;25(6):745-8
- Rothschild B, Naples V, Barbian L. Bone manifestations of actinomycosis. Ann Diagn Pathol. Feb 2006;10(1):24-27.
- Lippes J. Pelvic actinomycosis: a review and preliminary look at prevalence. Am J Obstet Gynecol. Feb 1999;180(2 Pt 1):265-9.
- Litwin KA, Jadbabaie F, Villanueva M. Case of pleuropericardial disease caused by Actinomyces odontolyticus that resulted in cardiac tamponade. Clin Infect Dis. Jul 1999;29(1):219-20.
- Wust J, Steiger U, Vuong H, Zbinden R. Infection of a hip prosthesis by Actinomyces naeslundii. J Clin Microbiol. Feb 2000;38(2):929-30.
- Lequerre T, Nouvellon M, Kraznowska K, et al. Septic arthritis due to Actinomyces naeslundii: report of a case. Joint Bone Spine. Oct 2002;69(5):499-501.
- T, Baumgartner JC. Occurrence of Actinomyces in infections of endodontic origin. J Endod. Sep 2003;29(9):549-52.
- Soria-Aledo V, Flores-Pastor B, Carrasco-Prats M, et al. Abdominopelvic actinomycosis: a serious complication in intrauterine device users. Acta Obstet Gynecol Scand. Sep 2004;83(9):863-5.
- Scarano FJ, Ruddat MS, Robinson A. Actinomyces viscosus postoperative endophthalmitis. Diagn Microbiol Infect Dis. Jun 1999;34(2):115-7.
- Curi MM, Dib LL, Kowalski LP, et al. Opportunistic actinomycosis in osteoradionecrosis of the jaws in patients affected by head and neck cancer: incidence and clinical significance. Oral Oncol. May 2000;36(3):294-9.
- Kuijper EJ, Wiggerts HO, Jonker GJ, et al. Disseminated actinomycosis due to Actinomyces meyeri and Actinobacillus actinomycetemcomitans. Scand J Infect Dis. 1992;24(5):667-72.
- Schaal KP, Lee HJ. Actinomycete infections in humans – a review. Gene. Jun 15 1992;115(1-2):201-11.
- Smith AJ, Hall V, Thakker B, Gemmell CG. Antimicrobial susceptibility testing of Actinomyces species with 12 antimicrobial agents. J Antimicrob Chemother. Aug 2005;56(2):407-9.
- Kim JC, Ahn BY, Kim HC, et al. Efficiency of combined colonoscopy and computed tomography for diagnosis of colonic actinomycosis: a retrospective evaluation of eight consecutive patients. Int J Colorectal Dis. Aug 2000;15(4):236-42.
- Macfarlane DJ, Tucker LG, Kemp RJ. Treatment of recalcitrant actinomycosis with ciprofloxacin. J Infect. Sep 1993;27(2):177-80.
- Endo S, Murayama F, Yamaguchi T, et al. Surgical considerations for pulmonary actinomycosis. Ann Thorac Surg. Jul 2002;74(1):185-90.