

Impaction of permanent Canine due to retaining of deciduous teeth

Nessa J¹, Akter M², Hasan M K³

Abstract:

24 years old female – Miss Ema Ghosh presented with discharging sinus through the space between upper rights lateral incisor and 1st premolar due to the infection of remaining root portion of deciduous canine for one month. Resulting from this retaining root portion of deciduous tooth the permanent canine became impacted. Key word: Impacted canine, BDR, OPG. Impacted canine: Impacted teeth are those with a delayed eruption time or that are not expected to erupt completely based on clinical and radiographic assessment.¹ Permanent maxillary canines are the second most frequently impacted teeth; the prevalence of their impaction is 1-2% in the general population.^{2,3} This is most likely due to an extended development period and the long, tortuous path of eruption before the canine emerges into full occlusion.²⁻⁴

BDR: Broken down root. The portion of root of a teeth due to trauma or caries. OPG: Orthopantomograph, A radiographic system that uses three axes of rotation to obtain a panoramic radiograph of the dental arches and their associated structures.

Introduction:

Miss Ema Ghosh, 24 years old female hailing from chatak, Sylhet came at the faculty of Dentistry, BSMMU. She has complaints of discharging of pus from the space between upper right lateral incisor and 1st premolar for 1 month. After clinical examination it was found that her upper right canine is missing from the normal series of teeth, and pus was discharging through a very tiny opening from the space between upper right lateral incisor and 1st premolar. At first the patient went to one of the local dental surgeon in chatak, Sylhet. The Doctor prescribed her an antibiotic of Amoxycillin group to control the infection. However that amoxicillin did not working this case and so patient became very nervous about her uncontrolled infection. She therefore came to Dhaka for a better treatment. In Dhaka she consulted with another dental surgeon who took one intra oral peri apical radiograph of that particular region.

1. Dr. Jebun Nessa Associate professor & Chairman Preventive & Children Dentistry Banghabandhu Sheikh Mujib Medical University
2. Dr. Mahmuda Akter Assistant Professor Oral & Maxillo facial Surgery Department Banghabandhu Sheikh Mujib Medical University
3. Dr. Md. Kamrul Hasan BDS, Chittagong Medical College HMO, Conservative Dentistry & Endodontics BSMMU

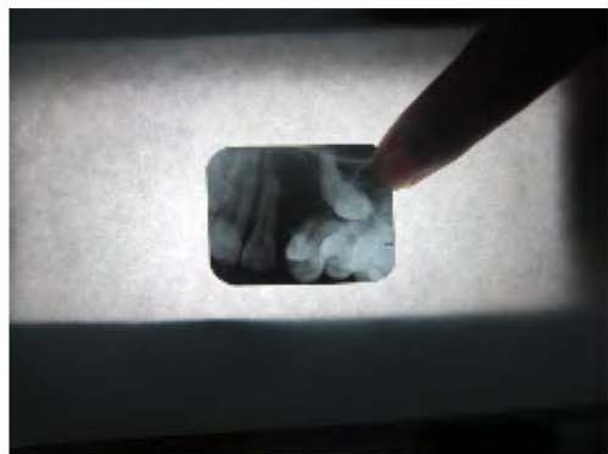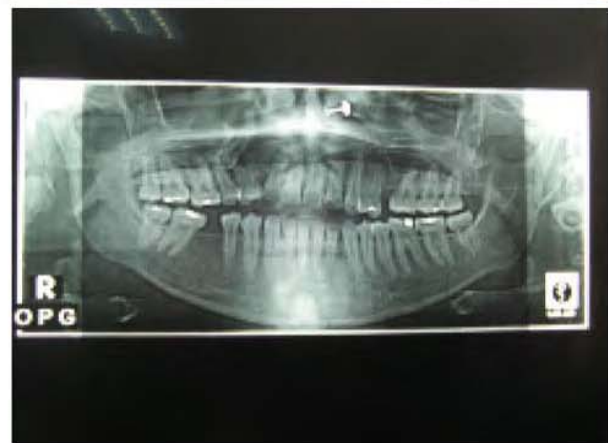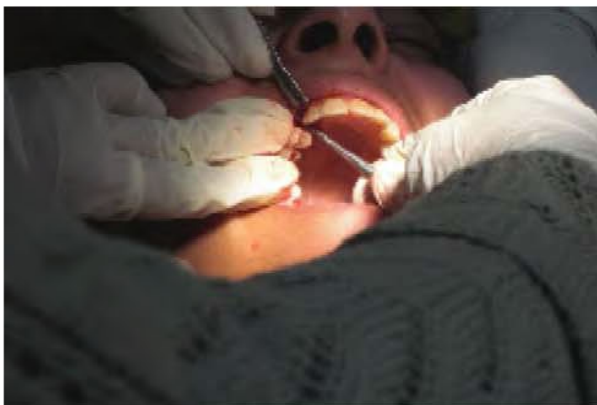
Unfortunately due to overlapping that radiograph findings did not show any specific clue about discharging sinus although that radiographs shows an impacted upper right permanent canine which is placed horizontally across the roots of 1st and 2nd premolar as well as some periodontal lesion in both premolars of the affected area especially in the 1st premolar. After that, 2nd dentist prescribed her an antibiotic of flucloxacillin group to control her infection assuming that discharging of pus due to local infection. But after taking full course of antibiotic, discharging of pus only reduced in amount but not completely stopped. Afterwards 2nd dental surgeon advised her to remove impacted canine and for this reason she was referred to the Faculty of dentistry of BSMMU.

Author took up the case to take care after reviewing all of her treatment documents. The patient was examined clinically again in the faculty of dentistry of BSMMU. On palpation the author found pus was coming out through a very tiny whole though it was not so painful. The author also found and felt that an elevated area in between the lateral incisor and 1st premolar. Her advice the patient to take an OPG X-ray. On OPG broken down root (BDR) of deciduous canine was identified which was submerged within the alveolar ridge of that region as well as Impacted permanent canine was seen in OPG. Then her parent was interviewed about her dental caries and deciduous tooth shedding history. They informed that all of her upper anterior teeth were eaten up by caries upto the gum line when she was a kid. In dentistry this condition is termed as “Nursing bottle syndrome”. About the tooth shedding they also informed that the upper four anterior teeth were extracted by the dental surgeon a little bit earlier than the proper shedding time. If the primary canine is still present it should be extracted. Sufficient soft tissues & bone should then be removed from the crown of the impaction to maintain an opening that will stimulate the eruption of the impacted tooth⁵. The author decided to remove impacted BDR of deciduous canine surgically. After removing gum flap, the root of deciduous canine was seen very clearly and she was able to remove that BDR easily. Now the patient is cured and has no complaints of discharge, although her permanent canine is horizontally impacted. So the patient is advised to take follow up radiograph at least one in every year to see the latest position of the impacted permanent canine as well as if this impacted canine would not disturbed her then it is better to keep as it is.

Discussion:

Timely removal of deciduous (milk teeth) is very important. It is not only like that it would delay the eruption of permanent successors. From very simple to severe complaints may arise from this type of silly ignorance. In our mouth 2 sets of teeth are present. At the age of 6 months (Varies from person to person) 1st deciduous teeth erupt and eruption of deciduous teeth completed around the age of 2 years. The number of deciduous teeth is 20 (2 incisors, 1 canine, 2 molar on each quadrant of both jaws). The 1st permanent tooth erupts at the age of 6 years behind the 2nd deciduous molar on each quadrant of both jaws. Most people do mistake about these 4 permanent molar teeth as deciduous because they erupt in such a young age. Normally every deciduous tooth has a definite time to shed to create free space for their permanent successors. Sometimes due to various reasons deciduous teeth are not shed timely. Most of the time the general public has no idea about the shedding time of deciduous teeth of their kids as well as the possible complication for retaining teeth in the jaw if not remove in the right time.

A severe complication from very simple mistake (not to extract the deciduous tooth timely) arouse in case of this patient. She did not realize that one of her deciduous teeth is still in her mouth. And only presence of this tiny tooth particle the permanent canine (Which is very important tooth for facial expression) could not be able to erupt as well as failure to take its proper position in the mouth. Impaction of the maxillary canine may occur because this tooth has the longest period of developmental positions in succession. it can also be easily deflected from its normal course of eruption⁶. Rather than it turned its position horizontally which is shown in both intra oral peri-apical and OPG radiograph.

**References:**

1. Thilander B, Jakobsson SO. Local factors in impaction of maxillary canines. *Acta Odontol Scand* 1968; 26:145-68.
2. Rayne J. The unerupted maxillary canine. *Dent Pract Dent Rec* 1969; 19:194-204.
3. Bass TB. Observations on the misplaced upper canine tooth. *Dent Pract Dent Rec* 1967; 18:25-33.
4. Hitchin AD. The impacted maxillary canine. *Br Dent J* 1956; 100:1-14.
5. *Dentistry for the Child & adolescent*; Ralph E McDonald, David R Avery
6. Cohen MI recognition of the developing malocclusion, *Dent clin, North Am* 299 – 311, 1959.