

## Interstitial lung disease: A case report

Kamal SM<sup>1</sup>, Bakar MA<sup>2</sup>, Ahad MA<sup>3</sup>

### Abstract

*A 65 years old farmer was admitted in Medicine ward with the complaints of progressive exertional breathlessness, non-productive cough and recurrent episodes of fever. The patient had clubbing and chest examination revealed end inspiratory crackles. Chest x-ray, CT scan of chest and spirometry revealed the features of interstitial lung disease (ILD). So we diagnosed the case as idiopathic pulmonary fibrosis variety of ILD. We reported this rare case for developing awareness among the clinicians.*

### Introduction

Interstitial lung disease (ILD) comprises a group of lung disorders characterized by various levels of inflammation and fibrosis due to injury to the alveolar epithelial lining<sup>1</sup>. Following injury the alveolar epithelial cells (AEC) actively participate in re-epithelialization or in the development of fibrosis through the process of epithelial mesenchymal transition (EMT), endoplasmic reticulum (ER) stress pathway, apoptotic pathway and developmental pathway<sup>2</sup>. EMT has an important role in the development of many tissues during embryogenesis. Similar cell changes are recapitulated during pathological process such as fibrosis<sup>3</sup>.

In the epithelial mesenchymal transition (EMT) process there occurs complex changes in the alveolar epithelial cells (AEC) in their architecture and behaviour. There is loss of epithelial characteristics and gain of mesenchymal properties leading to generation of fibroblast and myofibroblast<sup>4</sup>. The molecules that regulate ER stress response could be the targets for drugs in the ILD.

The injuries to the epithelial cells may be environmental, radiation, occupational agents, infections and drugs<sup>5,6</sup>. Genetic factors may also be responsible. Familial cause of

ILD transmitted as autosomal dominant trait with reduced penetrance have been reported<sup>7</sup>. The majority of ILD cases are considered idiopathic without a curable treatment<sup>8</sup>. There is a rising trend of ILD cases worldwide with international

differences in the prevalence rates<sup>9</sup>. ILD has more than double the incidence rate in UK over the recent years<sup>10</sup>. Almost all of the cases are idiopathic pulmonary fibrosis (IPF) and there was significant association with ischaemic heart disease as co-morbidity. Study was conducted regarding the age, sex, smoking habits, co-morbidity of diabetes mellitus, atrial fibrillation, hyperlipidaemia and use of drugs (such as beta-blockers, statins, aspirin, non-steroidal anti-inflammatory drugs, loop diuretics and proton pump inhibitors). But no significant association was found<sup>11</sup>.

### Case Report

A 65 years old male farmer presented with the complaints of breathlessness and cough for one year and fever for 15 days. Breathlessness increased with physical exertion and gradually deteriorated over the last one year. For the last one month he felt respiratory distress during activities of daily living and even during self care. Cough was non-productive and progressively distressing. He noticed recurrent episodes of fever over this one year.

He was a smoker having 1 pack (10 sticks)/day for last 40 years. He was active as a farmer throughout his whole occupational life. He was non-diabetic and non-hypertensive. He had clubbing (Fig-I) and chest examination revealed end inspiratory crackles.

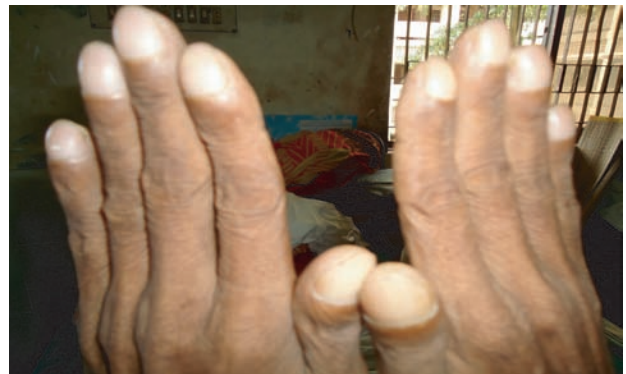

Fig-I: Clubbing.

Other systemic examination revealed normal findings. Complete blood count, urine routine microscopic examination, blood sugar, serum creatinine, sputum examination for acid fast bacilli, mantoux test (MT) and electrocardiogram revealed normal findings. Chest x-ray revealed diffuse reticulo-nodular opacity involving all the zones of both lung fields (Fig-II).

01. Corresponding Author: Dr. S M Kamal FCPS, MACP  
Associate Professor, Department of Medicine  
Khulna Medical College, Khulna, Bangladesh  
Email: smkamal10@gmail.com

02. Dr. Md. Abu Bakar FCPS, FRCP  
Professor, Department of Medicine  
Khulna medical College, Khulna, Bangladesh.

03. Dr. MA Ahad FCPS, MD, FACP  
Associate Professor, Department of Gastroenterology  
Khulna Medical College, Khulna, Bangladesh.

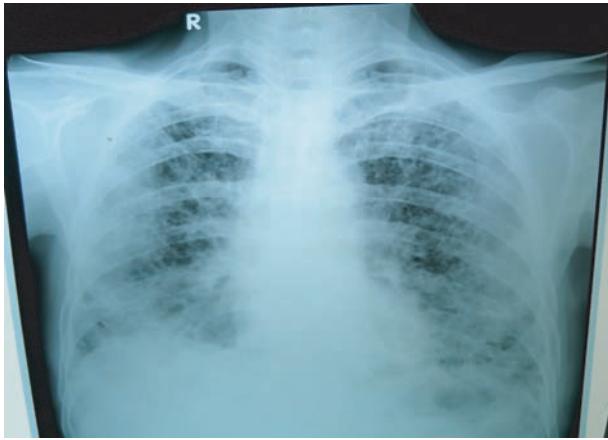


Fig-II: CXR Diffuse reticulo nodular apacity involving all the zones of both lung fields.

Computerised tomographic (CT) scanning of the chest revealed features of fibrosis with linear and nodular opacities leading to architectural disruption of all the zones of both lungs (Fig-III). Spirometry revealed restrictive type of lung disease. Lung biopsy was not done. The patient was diagnosed as a case of idiopathic pulmonary fibrosis variety of interstitial lung disease.

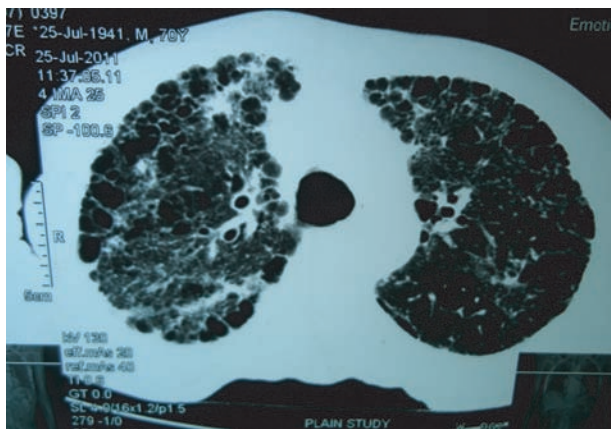


Fig-III: CT scan of the chest. Linear and nodular opacities, fibrosis, architectural disruption of lung.

## Discussion

This 65 years old male farmer presented with exertional breathlessness, non-productive cough and fever. He had clubbing and chest examination revealed end-inspiratory crackles. Chest x-ray, CT scan of chest and spirometry revealed the features of ILD.

The patient was a farmer. But clubbing is not a usual feature of farmer's lung. So we considered the other possibilities such as sarcoidosis, drug induced ILD, ILD associated with connective tissue disease, familial ILD and idiopathic pulmonary fibrosis variety of ILD.

He had no features suggestive of sarcoidosis except negative Mantoux Test (MT). Due to our limitations we could not perform lung biopsy and histopathology to see granuloma in lung fibrosis which is a feature of sarcoidosis.

Various drugs are associated with ILD such as amiodarone, non-steroidal anti-inflammatory drugs, chemotherapeutic agents, colony stimulating factors, interferon, anti-thymocyte globulin, intravenous immunoglobulin and immunosuppressive agents (methotrexate and cyclophosphamide)<sup>12</sup>. This patient has no history of taking any of these drugs.

ILD is a major feature of connective tissue disease such as systemic lupus erythematosus, systemic sclerosis, dermatomyositis. Polymyositis and rheumatoid arthritis<sup>13</sup>. This patient has no features of any connective tissue diseases. He had no family history of ILD.

This patient had clubbing which is usually present in idiopathic pulmonary fibrosis. So we decided that our patient is a case of idiopathic pulmonary fibrosis (IPF) variety of interstitial lung disease.

## References

1. Ley K, Zarbock A. From lung injury to fibrosis. *Nat Med* 2008;14:20-1.
2. Corvol H, Flamein R, Epaud R, Clement A, Guillot L. Lung alveolar epithelium and interstitial lung disease. *J bio cell* 2009;41:1643-1651.
3. Lee JM, Dedhar S, Kallusi R, Thompson EW. The epithelial mesenchymal transition: new insights in signaling development and disease. *J cell boil* 2006;172:973-81.
4. Thiery JP, Sleeman JP. Complex networks orchestrate epithelial mesenchymal transitions. *Nat Rev Mol Cell Biol* 2006;7:131-42.
5. American Thoracic Society/ European Respiratory Society. International multidisciplinary consensus classification of the idiopathic interstitial pneumonias. *Am J Respir Crit Care Med* 2002;165:277-304.
6. Verleden GM, Du Bois RM, Bouros D et al. Genetic predisposition and pathogenetic mechanisms of interstitial lung diseases of unknown origin. *Eur Respir J* 2001;18:17-29.
7. Nogee LM, Dunbar III AE, Wert S, Askin F, Hamvas A, Whitsett JA. Mutations in the surfactant protein C gene associated with interstitial lung disease. *Chest* 2002;121: 205-15.
8. Bouros D, Antonio KM. Current and future treatment approaches in idiopathic pulmonary fibrosis, *Eur Respir J* 2005;16:693-703.
9. Tinelli C, De silvestri A, Richeldi L, Oggionni T. The Italian register for diffuse infiltrative lung disorders: four years report. *Sarcoidosis vasc diffuse lung dis* 2005;22:54-8.
10. Gribbin J, Hubbard RB, Le Jeune I, Smith CJP, west J, Tata LJ. Incidence and mortality of idiopathic pulmonary fibrosis and sarcoidosis in the UK. *Thorax* 2006;61:980-5.

11. Ponnuswamy A, Manikandam R, Sabetpour A, Keeping IM, Finnerty JP. Association between ischaemic heart disease and interstitial lung disease: A case control study. *J Respir med* 2009;103:503-507.
12. Camus P, Fanton A, Banniaud P, Camus C, Fourcher P. Interstitial lung disease induced by drugs and radiation. *Respiration* 2004;71:301-26.
13. Fagundes M N, Caleiro MTC, Navarro-Rodriguez T, Baldi BG et al. Esophageal involvement and interstitial lung disease in mixed connective tissue disease. *J rmed* 2008; 103:854-860.