

## Case Report

# Oral Histoplasmosis with Previously Treated Pulmonary Tuberculosis: A Case Report

Sadat SMA<sup>1</sup>, Robin MAH<sup>2</sup>, Rita SN<sup>3</sup>, Akhter F<sup>4</sup>, Uddin AFMK<sup>5</sup>

### Abstract

*Oral Histoplasmosis is a deep fungal infection may present as oral ulceration and can be confused with oral mucosal malignancies, tuberculosis and other fungal diseases. It mostly affects individual having immunodeficiencies like tuberculosis and AIDS, but may also affect immunocompetent individuals. Here we presented a case of oral histoplasmosis with previously treated pulmonary tuberculosis and was treated by oral itraconazole. Complete disappearance of oral ulceration was evident following four weeks treatment and the patient is in regular follow up with maintenance therapy for last ten months.*

**Keywords:** Itraconazole, Oral Histoplasmosis, Oral Ulcer, Tuberculosis.

### Introduction

Histoplasmosis is caused by *Histoplasma capsulatum*, a dimorphic pathogenic fungus that develops a branching hyphal form in soil and a yeast form in the host tissue<sup>1</sup>. Infection by this organism is endemic in North America, Central America and South America, but it also has been reported in Africa, Asia, India and Australia<sup>2</sup>. The infective agents are airborne spores from the mycelial form. In Bangladesh, sporadic cases have been reported in different literature<sup>3-6</sup>. The inhalation of spores, which are present in chicken, pigeon and bat excrement, by immunocompetent hosts usually results in an asymptomatic pulmonary infection.

Hosts with immunosuppression may develop a generalized infection that involves several organs<sup>7</sup>. Clinically the disease is manifested as weakness, fever, weight loss, mucocutaneous lesions and hepatosplenomegaly.

Clinically Histoplasmosis is classified into primary acute pulmonary form, chronic pulmonary form and disseminated form (DH). The course of this disease can be affected by the immune status of the host and by the degree of exposure to infective propagules<sup>8</sup>. Oral lesions have been reported in 25 to 45 percent of patients with documented cases of progressive disseminated histoplasmosis and in several case reports<sup>9</sup>.

Around 30-66% of patients with DH have oral lesions, frequently presenting as the initial sign. Generally lesions of histoplasmosis in the oral cavity are the local manifestation of pulmonary or disseminated disease<sup>10</sup> but rarely may they be the primary or even the only manifestation of the disease<sup>11</sup>.

*H. capsulatum* is a major opportunistic pathogen in patients infected with the human immunodeficiency virus (HIV) in endemic areas; approximately 5 percent of patients with AIDS in these areas develop disseminated histoplasmosis<sup>12</sup>. In immunocompetent hosts, few cases of oral histoplasmosis without detectable systemic involvement have been described. Oral histoplasmosis may manifest at any region of the mouth as nodules, deep ulcerative or vegetative lesions or painful shallow lesions<sup>13</sup>.

Diagnosis of Histoplasmosis is usually based on clinical signs and symptoms, organ function tests and fungal demonstration or culture from a lesion or secretion. Serological testing may help together with other suggestive but non-diagnostic clinical criteria<sup>14,15</sup>. Recently, molecular typing of *H. capsulatum* has been shown to be useful in distinguishing relapse from reinfection, and in defining the likely source of the infection<sup>16</sup>. Furthermore, molecular typing of *H. capsulatum* by the random amplified polymorphic DNA polymerase chain reaction (RAPD-PCR) method is able to discriminate among clinical isolates, making it a useful tool for epidemiological investigation<sup>16</sup>.

#### Corresponding Author:

1. Dr. S. M. Anwar Sadat, BDS, BCS, MCPS, FCPS, MS  
Resident Surgeon, Department of Oral & Maxillofacial Surgery  
Dhaka Dental College & Hospital, Dhaka, Bangladesh  
Email: an\_sadat@yahoo.com
2. Dr. Munshi Ahmed Hossain Robin, BDS,  
Lecturer, Department of Oral & Maxillofacial Surgery  
Holy Family Red Crescent Medical College, Dhaka
3. Dr. Sufia Nasrin Rita, BDS, FCPS  
Associate Professor and Head, Department of Orthodontics  
Sapporo Dental College, Dhaka
4. Dr. Feroza Akhter, BDS, MPH  
Senior Medical Officer, Dept of Dentistry  
BIRDEM Hospital, Dhaka, Bangladesh.
5. Dr. A. F. M. Kamal Uddin, MBBS, DTCD, MD (Radiation Oncology)  
Lecturer, Department of Medicine  
Dhaka Dental College, Dhaka

Amphotericin B has been the drug of choice for systemic histoplasmosis<sup>17,18</sup>. The options have broadened considerably since the introduction of the azole compounds, ketoconazole and itraconazole<sup>14, 17</sup>. The successfully treated 1st reported case in Bangladesh was in 1982<sup>3</sup>.

### Case Report

A 65-year-old male farmer presented with two painful ulcers on upper alveolar gingivae and palatal mucosae and poor general health for three weeks. There was a history of difficulty in mastication with no history of pus discharge, paresthesia or numbness. Patient was habituated with smoking and gave no history of extra-marital sexual exposure. He gave history of previous pulmonary tuberculosis with irregular treatment. The other medical histories of patient were noncontributory. Extraoral examination revealed imaciated face with mild anaemia and enlarged, firm, non-tender, non-fixed lymph nodes in bilateral submandibular regions. Intraoral examination revealed poor oral hygiene with two almost identical ulcers in maxillary alveolar ridge and palatal mucosae on both sides. The indurated ulcers were tender with edematous, raised margin and the surfaces were covered with slough and focal areas of necrosis (Figure 1).

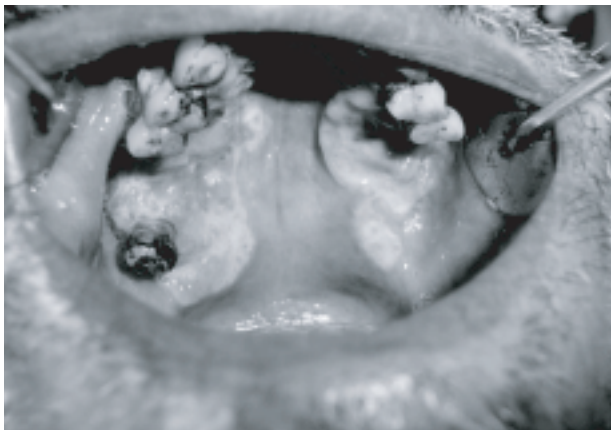


Figure 1: Ulcer present on the palatal mucosa and gingiva

Haematological values were within normal limits with normal blood sugar level and non-reactive VDRL, HIV1 and HIV2 in Western blot assay. Orthopantomogram showed no significant alvolar bone loss. Chest radiograph shows Koch's Lesion (Bilat) with volume reduction (Figure 2). Considering the possibilities of deep fungal infection, tuberculosis or mucosal malignancies, incision biopsy was done. Initial biopsy report revealed severely inflamed and oedematous fibrocollagenous tissue covered by ulcerated stratified squamous epithelium showing minor salivary glands with multiple granulomata composed of epitheloid cells with extensive areas of caseation necrosis which was consistent with tuberculosis. The patient was re-evaluated by a group of physicians who recommended repeat biopsy which revealed dense infiltration of acute and chronic inflammatory cells including many eosinophils, aggregates of epitheloid histiocytes and

some of the histiocytes contained intra-cytoplasmic round to oval bodies; morphologically consistent with histoplasmosis. There was no evidence of caseous necrosis or malignancy in the tissue sections (Figure 3). Based on the clinical features and investigatory findings, a final diagnosis of oral histoplasmosis in a non-HIV patient was made. Then the patient was evaluated systemically, where systemic involvement of histoplasmosis was ruled out.

With proper education and counseling, patient was treated with oral Itraconazole 200 mg twice daily. The lesions completely healed following four weeks medication (Figure 4). The patient, however, is under regular follow-up and no recurrence is noted after ten months.

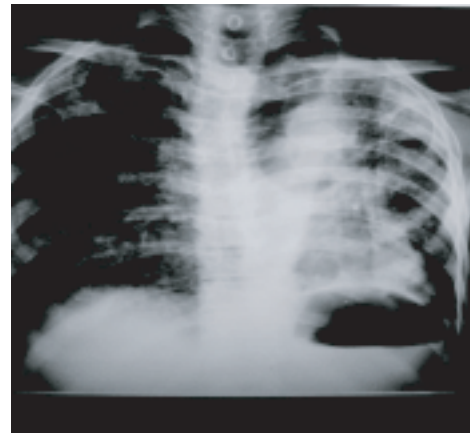


Figure 2: Chest radiograph shows Koch's Lesion

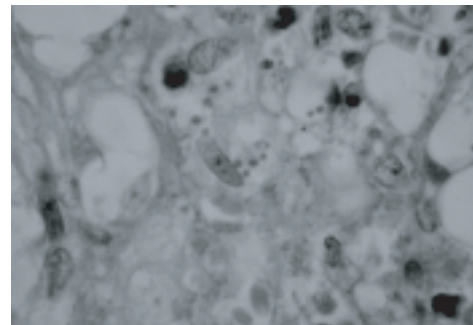


Figure 3: Histopathology shows epitheloid histiocytes with intracytoplasmic round to oval bodies.

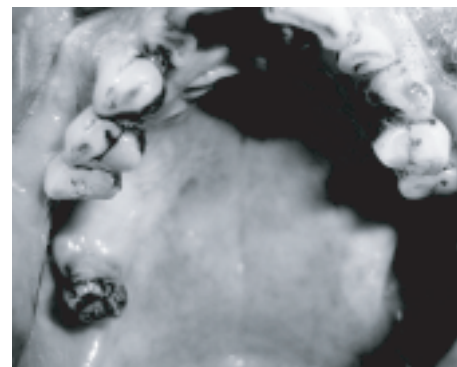


Figure 4: Post treatment showing complete resolution of palatal lesion

## Discussion

*H. capsulatum* is the organism responsible for occurring the fungal infection, Histoplasmosis. Oral manifestations, usually associated with the chronic disseminated form of the disease, constitute a rare event in immunocompetent patients. Most primary infections are asymptomatic, or the symptoms are acute and affect only the lungs. Oral lesions show a varied clinical appearance and are rarely painful. Mostly they presented as an ulcerative lesion with an elevated border, located mainly on the gingiva, tongue and palate. The reported case presented with painful ulcer in gingiva and palatal mucosa with dysphagia and poor general health.

Oral lesions of histoplasmosis occurred only as secondary local manifestations of pulmonary or disseminated disease<sup>9</sup>. Some investigators have claimed that primary oral histoplasmosis is possible and may develop as a result of direct inoculation of the fungus into the mucosa. Our reported case did not present any pulmonary infection or disease involvement. Clinicians usually diagnose primary oral histoplasmosis after discovering the lesions in the upper digestive tract in the absence of pulmonary signs and the diagnosis is based on identification of the fungus. For superficial and accessible oral lesions, cytologic evaluation and a biopsy usually are recommended. However, in cases in which the lesions are not accessible, serologic examination to detect antibodies or antigens may be a complementary diagnostic tool. Traumatic ulcers, necrotizing ulcerative gingivitis or stomatitis, syphilis, tuberculosis, squamous cell carcinoma and other mycoses, such as paracoccidioidomycosis should be considered as differential diagnosis. The reported case was confirmed by histopathology with PAS staining. HIV1 and HIV2 were also excluded.

Though spontaneous remission of oral histoplasmosis is reported, failure to treat the infection in patients with AIDS may result in death. Hidden immunosuppression should be considered always especially in HIV infection. General practitioners must exercise caution when examining patients, because oral lesions of histoplasmosis may be the only sign of AIDS. The basic inflammatory response in a deep fungal infection is granulomatous, with macrophages and multinucleated giant cells dominating the histologic picture. Diffuse, small granulomas contain a variable number of yeastlike *H. capsulatum* cells, which are highlighted by methenamine silver and PAS staining<sup>1</sup>.

Histoplasmosis as systemic disease is treated by intravenous amphotericin B, which should be administered in a hospital because of its varied adverse effects, such as nausea, chills, fever, vomiting and renal complications. On the other hand, new and less toxic

antifungal agents are available, such as the oral azoles, which are the drugs of choice for long-term maintenance therapy. Negroni and colleagues reported that treatment with itraconazole was favorable for localized oral lesions, when no systemic signs or symptoms could be detected. This drug appears to be safe and effective for both induction and maintenance therapies, with less toxicity than that of amphotericin B. Similarly our reported case was treated by oral itraconazole with maintenance therapy. The disease responded well with regaining normal oral mucosa form and function and also improvement of general health.

Histoplasmosis usually affect immunodeficient individual, knowledge of the oral manifestations of histoplasmosis might enable clinicians to make earlier diagnoses and initiate therapy more quickly. It is important for general dental and medical practitioners to perform thorough clinical examinations and include histoplasmosis in the differential diagnosis of any persistent ulcerated oral lesions of both immunodeficient and immunocompetent patients.

## References

1. Wheat LJ. Laboratory diagnosis of histoplasmosis: update 2000. *Semin Respir Infect* 2001;16:131-140.
2. Durkin MM, Connolly PA, Karimi K. Pathogenic differences between North American and Latin American strains of *Histoplasma capsulatum* var. *capsulatum* in experimentally infected mice. *J Clin Microbiol* 2004;42:4370-4373.
3. Islam N, Chowdhury NA. Histoplasmosis from Bangladesh: a case report. *Bangladesh Med Res Counc Bull* 1982;8:21-24
4. Rappo U, Beitler UR, Faulhaber JR. Expanding the horizons of histoplasmosis: disseminated histoplasmosis in a renal transplant patient after a trip to Bangladesh. *Transpl Infect Dis* 2009;1-6.
5. Mahbub MS, Ahsan MN, Miah MT, Alam MB, Gupta RD, Arif KM, Hasnain M: Disseminated histoplasmosis. *J Medicine* 2010;11:70-73.
6. Rahman MM, Hossain SM, Faiz MA, Rahman J, Sultan MT, Dewanjee AK: Disseminated Histoplasmosis in AIDS. *J.BCPS* 2005;23: 43-45.
7. Borges AS, Ferreira MS, Silvestre MT, Nishioka Sde A, Rocha A. Histoplasmosis in immunodepressed patients: study of 18 cases seen in Uberlândia, MG [in Portuguese]. *Rev Soc Bras Med Trop* 1997;30:119-124.

8. Wheat LJ, Kauffman CA. Histoplasmosis. *Infect Dis Clin North Am* 2003; 7:1-19.
9. Miller RL, Gould AR, Skolnick JL, Epstein WM. Localized oral histoplasmosis: a regional manifestation of mild chronic disseminated histoplasmosis. *Oral Surg Oral Med Oral Pathol* 1982;53:367-374.
10. Loh FC, Yeo JF, Tan WC, Kumarasinghe G. Histoplasmosis presenting as hyperplastic gingival lesion. *J Oral Pathol Med* 1989;18: 533-6.
11. Reddy P, Gorelick DF, Brasher CA, Larsh H. Progressive disseminated histoplasmosis as seen in adults. *Am J Med* 1970;48:629-36.
12. Cano MV, Hajjeh RA. The epidemiology of histoplasmosis: a review. *Semin Respir Infect*-2001; 16:109-118.
13. Rocha MM, Severo LC. Histoplasmoses disseminada em pacientes com síndrome da imunodeficiência adquirida (SIDA): estudo de 25 casos [Disseminated histoplasmosis in patients with acquired immunodeficiency syndrome (AIDS): study of 25 cases.]. *Rev Inst Med Trop São Paulo* 1994;36:167-170.
14. Bullock WE. *Histoplasma capsulatum*. In: Mandell GL, Bennett JE, Dolin R, eds. *Principles and practice of infectious diseases*, 4th edn. New York: Churchill Livingstone, 1995; 2340-53
15. Kirchner JT. Opportunistic fungal infections in patients with HIV disease: combating cryptococcosis and histoplasmosis. *Postgraduate Med* 1996;99:209-16.
16. Limaye AP, Connolly PA, Sagar M, et al. Brief Report: Transmission of *Histoplasma capsulatum* by organ transplantation. *N Engl J Med* 2000;343:1163-66.
17. Boutros HH, van Winckle RB, Evans GA, Wasan SM. Oral histoplasmosis masquerading as an invasive carcinoma. *J Oral Maxillofac Surg* 1995;53:1110-4.
18. Cobb CM, Shultz RE, Brewer JH, Dunlap CL. Chronic pulmonary histoplasmosis with an oral lesion. *Oral Surg Oral Med Oral Pathol* 1989;67:73-6.