

# FAHR'S Syndrome: A rare Neurodegenerative Disorder

Ahad MA<sup>1</sup>, Kamal SM<sup>2</sup>, Salma U<sup>3</sup>

### Abstract

Idiopathic Basal Ganglia Calcification, also known as Fahr disease or Fahr's Syndrome or Bilateral StriatoPallidoDentate Calcinosis (BSPDC) is a rare, genetically dominant, inherited neurological disorder characterized by abnormal deposits of calcium in areas of the brain that control movement, including the basal ganglia and the cerebral cortex. A rare idiopathic disease which manifests in middle age characterized by punctate areas of non-arteriosclerotic calcination in parts of the gray and dentate nuclei, particularly of smaller brain vessels. The symptoms include mental and growth retardation, dystonic movements, and athetosis. May be caused by a malfunction of the glandula parathyreoidea. The term Fahr triad consists of symmetrical calcification of the basal ganglia, neuropsychiatric symptoms, and hypofunction of the parathyroid gland. Treatment is directed toward minimizing symptoms. The prognosis for any individual with Fahr's Syndrome is variable and hard to predict. Progressive neurological deterioration generally results in disability and death.

1. Corresponding Author:  
Dr. Md. Abdul Ahad  
Professor  
Department of Gastroenterology  
Khulna Medical College, Khulna.  
e-mail: drahadbd@yahoo.com  
Mobile: 01711 184343
2. Dr. S.M. Kamal  
Professor  
Department of Medicine  
Khulna Medical College, Khulna.
3. Dr. Umme Salma  
Assistant Surgeon  
OSD DG Health.  
DMU, M D  
Department of Nuclear Medicine, Phase-A (NINMAS)  
BAEC, BSMMU Campus, Dhaka.

### Introduction

It is a rare degenerative neurological disorder characterized by calcifications and cell loss within the basal ganglia. The disease was first noted by German neurologist Karl Theodor Fahr in 1930<sup>1</sup>. According to reports in medical literature, Fahr Disease is often familial<sup>2</sup>. It is believed to have autosomal dominant inheritance<sup>3</sup> but a few cases have been reported to have

autosomal recessive inheritance and even some sporadic cases have been reported in literature<sup>4</sup>. Idiopathic calcification of the basal ganglia, also known as Fahr's disease, is a rare neurologic disorder of unknown etiology characterized by neuropsychiatric abnormalities,<sup>5,6,7</sup> Parkinsonian or choreoathetotic-type movement disturbance, and extensive symmetrical calcification of the basal ganglia and dentate nuclei in the cerebellum. These symptoms cannot be explained by any other particular disorder of the calcium phosphorus metabolism or any other disease. Dementia is a well-recognized neuropsychiatric manifestation of Fahr's disease<sup>8</sup>. In addition, a schizophrenia-like psychosis characterized by paranoia, hallucinations, and delusions has been reported<sup>9</sup>. There is no cure for Fahr's syndrome, which worsens over time, nor is there a standard course of treatment.

### Discussion

Idiopathic Basal Ganglia Calcification, also known as Fahr disease or Fahr's Syndrome or Bilateral Striato Pallido Dentate Calcinosis (BSPDC) is a rare, genetically dominant<sup>3</sup>, inherited neurological disorder characterized by abnormal deposits of calcium in areas of the brain that control movement, including the basal ganglia and the cerebral cortex. The calcium deposits in the brain may occur before the onset of the symptoms, usually in the third decade of life. Although it may also be evident in childhood<sup>10,11</sup> and with advancing age the amount of calcification increases. In Fahr's disease the mineral deposits tend to be selective for small capillaries and small vessels of white matter, which is different from that in atherosclerosis<sup>12</sup>. The calcification may include endothelial and stromal vascular cells as well as the interstitium.

However, the local circulatory disturbances such as regional ischemia have been regarded as the primary event precipitating the deposition of calcium as well as other minerals. Other contributed factors are abnormality in the calcium metabolism<sup>13</sup> or local inflammatory process<sup>14</sup>. Also, the calcification could be a primary event occurring without preceding circulatory dysfunction, since a significant familial type suggests either autosomal recessive or dominant inheritance<sup>3</sup>. Brain calcification without symptoms such as the small calcifications in the basal ganglia, and less commonly in the dentate nucleus of the cerebellum can occur in elderly patients. According to reports in medical literature, Fahr Disease is often familial. It is believed to have autosomal dominant inheritance but

a few cases have been reported to have autosomal recessive inheritance and even some sporadic cases have been reported in literature. The association between the abnormal phenotypes and abnormal genes remain unclear despite the recent mapping to chromosome 14q of a susceptible locus for Fahr Disease<sup>15</sup>.

CT axial images show calcifications in the bilateral basal ganglia. Symptoms may include motor function deterioration, dementia, mental retardation, spastic paralysis, dysarthria (poorly articulated speech), spasticity (stiffness of the limbs), ocular (eye) problems, and athetosis (involuntary, writhing movements) (figure-1).

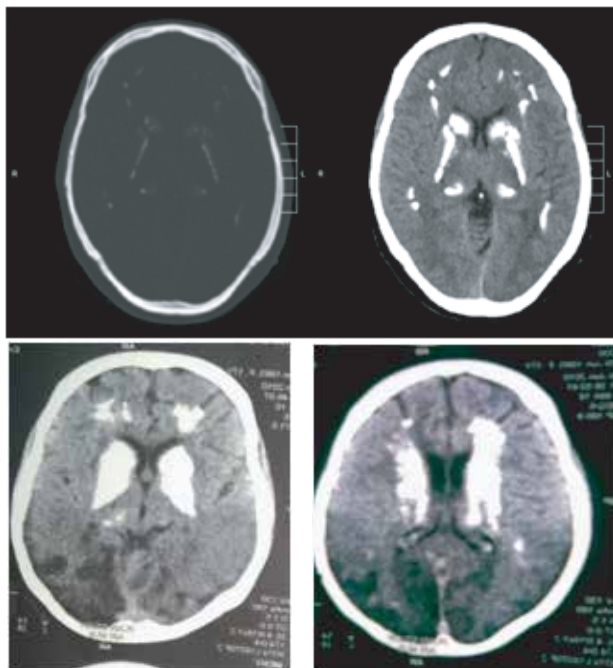


Figure-1: CT axial images

Features of Parkinson's disease<sup>16</sup> such as tremors, rigidity (resistance to imposed movement), a mask-like facial appearance, shuffling gait and a "pill-rolling" motion of the fingers may also occur in individuals with Fahr's syndrome. Other symptoms may include dystonia (disordered muscle tone), chorea (involuntary, rapid, jerky movements), and seizures<sup>17</sup>. Onset of the disorder may occur at any time from childhood to adulthood. Fahr syndrome thus involves abnormalities of the neurologic system (cerebral calcification, dementia, spastic paraplegia, athetosis), skull (microcephaly, i.e. an abnormally small head), eyes (glaucoma, optic nerve atrophy, retinitis pigmentosa) and a significant hormone problem, namely hypoparathyroidism (the parathyroid gland regulates calcium). The disease is inherited as an autosomal recessive trait in which both parents carry a Fahr gene and each of their children (boys and girls alike) stands a 1 on 4 (25%) risk of receiving both Fahr genes and therefore having this dread disease.

Idiopathic calcification of the basal ganglia, also known as Fahr's disease, is a rare neurologic disorder of unknown

etiology characterized by neuropsychiatric abnormalities,<sup>5</sup> Parkinsonian or choreoathetotic-type movement disturbance and extensive symmetrical calcification of the basal ganglia and dentate nuclei in the cerebellum<sup>18</sup>. These symptoms cannot be explained by any other particular disorder of the calcium phosphorus metabolism or any other disease<sup>14</sup>. Dementia is a well-recognized neuropsychiatric manifestation of Fahr's disease<sup>8</sup>.

In addition, a Schizophrenia-like psychosis characterized by paranoia, hallucinations, and delusions has been reported<sup>9</sup>. The pathophysiology of psychosis in Fahr's disease remains unknown, though previous studies have found a decreased cerebral blood flow matching the distribution of calcification or decreased perfusion in the cortex, which may reflect secondary deficits due to calcification.

There is no cure for Fahr's syndrome, which worsens over time, nor is there a standard course of treatment. The process of calcification cannot be stopped or reversed. Treatment is directed toward minimizing symptoms. Where possible, clinicians focus on alleviating its various mental and physical effects. These may vary to some degree depending on the individual, even among members of the same family. Case reports have suggested that haloperidol or lithium carbonate may help with psychotic symptoms,<sup>19</sup> while antidepressant medications are often used to combat depression. Ear infections associated with Fahr disease can be treated with antibiotics and pain medication.

The prognosis for any individual with Fahr's Syndrome is variable and hard to predict. There is no reliable correlation between age, extent of calcium deposits in the brain, and neurological deficit. Since the appearance of calcification is age-dependent, a CT scan could be negative in a gene carrier who is younger than the age of 55<sup>18</sup>. The prognosis (outlook) for individuals with Fahr's syndrome is poor. Progressive neurological deterioration generally results in disability and death.

Radiological diagnosis could be the starting point to guide the clinician for possibility of Fahr's disease. The differential diagnosis includes but not limited to;<sup>20</sup> Parkinson's disease, Huntington's disease, Progressive supranuclear palsy, Wilson's disease, Spasmodic torticollis, Oligodendroglioma, Low-grade astrocytoma<sup>21</sup> and Arteriovenous malformation. Therefore Fahr's Disease or Bilateral Striato Pallido Dentate Calcinosis (BSPDC) is a diagnosis of exclusion.

#### References

1. T.Fahr: Idiopathische Verkalkung der Hirngefäße. Zentralblatt für allgemeine Pathologie und pathologische Anatomie. 2009;50:129-33.
2. Westenberger A1, Klein C. The genetics of primary familial brain calcifications. *Curr Neurol Neurosci Rep.* 2014;14(10):490.

3. Yamada N, Hayashi T. Asymptomatic familial basal ganglia calcification with autosomal dominant inheritance: a family report. *No to hattatsu Brain and development*. 2006;32(6):515-19.
4. Oliveira JR, Spiteri E, Sobrido MJ, Hopfer S, Klepper J, Voit T, et al. Genetic heterogeneity in familial idiopathic basal ganglia calcification (Fahr disease). *Neurology*. 2004;63(11):2165-67.
5. Cummings JL, Gosenfeld LF, Houlihan JP. Neuropsychiatric disturbances associated with idiopathic calcification of the basal ganglia. *Biol Psychiatry*. 2010; 18:591-601.
6. Nicolas G, Guillin O, Borden A, Bioux S, Lefaucheur R, Hannequin D. Psychosis revealing familial idiopathic basal ganglia calcification. *Gen Hosp Psychiatry*. 2013;35 (5):575.
7. Srivastava S, Bhatia MS, Sharma V, Mahajan S, Rajender G. Fahr's Disease: An Incidental Finding in a Case Presenting with Psychosis. *German J Psychiatry*. 2010;13(2):89-90.
8. Modrego PJ, Mojonero J, Serrano M, Fayed N. Fahr's syndrome presenting with pure and progressive senile dementia. *Neurol Sci*. 2005;26 (5):367-69.
9. Francis AF. Familial basal ganglia calcification and Schizophreniform psychosis. *Br J Psychiatry*. 2004;79: 360-62.
10. Abbitt DP, Tang T, Dobbs J, Berk R. Idiopathic familial cerebrovascular ferrocalsinosis (Fahr's disease) and review of differential diagnosis of Intracranial calcification in children (Eng). *Am J Roentgenol Radium Ther Nucl Med*. 2005 Feb; 10 (2):352-58.
11. Matsui K, Yamada M, Kobayshi T, Miyake S, Iwamoto H, Hara M, et al. An autopsy case of Fahr disease (infantile form) (Jpn). *No to Hattatsu*. 2009 Jul;24 (4):358-63
12. Pilleri G. A case of Morbus Fahr (Nonarteriosclerotic, idiopathic intracerebral calcification of the blood vessels) in three generations. An clinico-anatomical contribution. (Eng) *Psychiatr Neurol (Basel)*. 2007;152(1):43-58.
13. Beall SS, Patten BM, Mallette L, Jancovic J. Abnormal systemic metabolism of iron, porphyrin, and calcium in Fahr's syndrome. Division of Biology, California Institute of technology, Pasadena, 91125 (Eng). *Ann Neurol*. 2008 Oct;26(4):569-75.
14. Morgante L, Vita G, Meduri M. Fahr's Syndrome: Local inflammatory factors in the pathogenesis of calcification. (Eng) *J Neurol*. 2010 Feb; 233(1): 19- 22.
15. Geschwind, D.H. Loginov, M.Stern, J.M. Identification of a locus on chromosome 14q for idiopathic basal ganglia calcification (Fahr disease). *Am.J.Hum.Genet*. 2011;65:764-72.
16. Manyam BV. What is and what is not "Fahr"s disease". *Parkinsonism Relat Disord*. 2005;11:73-80.
17. Hoque MA, Siddiqui MR, Arafat Y, Khan SU, Rahman KM, Mondol BA, et al. Fahr's disease: a very rare cause of epilepsy. *Mymensingh*.
18. Brannan TS, Burgfr AA, Chaudhary MY. Bilateral basal ganglia calcifications visualized on CT scan. *J Neurol Neurosurg Psychiatry*. 2008;43:403-6. *Med J* 2010;19(1):127-29.
19. Munir KM. The treatment of psychotic symptoms in Fahr's disease with Lithium carbonate. *J Clin Psychopharmacol*. 2009 Feb;6 (1):36-38.
20. Ahad MA, Bala CS, Karim SR. Fahr's Syndrome - A Case Report. *Bang. Med J, Khulna*. 2012;45 (1& 2):33-35.
21. Ang LC, Rozdilsky B, Alport EC, Tchang S. Fahr's disease associated with astrocytic proliferation and astrocytoma. Department of Pathology, University of Saskatchewan, Canada *Surg Neurol*. 2013;39:365-69.