

Comparison between Sutureless and Glue Free versus Sutured Limbal Conjunctival Autograft in Primary Pterygium Surgery

Md. Mahmud-ul-Huda ¹, Sajed Abdul Khaleque ^{*2}

Abstract

Introduction: To compare and evaluate the safety and efficacy of two surgical techniques for the management of primary pterygium. **Materials & Methods:** The study included 176 eyes of 176 patients with primary pterygium. The mean age was 49 ± 12 years (range 24–74 years). Simple excision under local anesthesia was performed followed by closure of the bare sclera by sutureless and glue free conjunctival autograft in 76 eyes of 76 patients (group 1), versus the conventional method of a sutured conjunctival autograft in 100 eyes of 100 patients (group 2). **Results:** The pterygium recurrence rate was 6% for group 1, 8% for group 2. Graft dehiscence occurred in 4 eyes out of 50 (8%) in group 1. Graft retraction occurred in 6 (12%) out of 50 eyes for group 1 versus 6 eyes (6%) in group 2. Pyogenic granuloma occurred in 3 (3%) eyes out of 100 in group 2. No other serious complications were noted. At the 3 week visit the overall patient satisfaction score was statistically significantly higher for group 1 ($P < 0.002$) compared to group 2. At 3 months postoperatively, the gain in uncorrected visual acuity (UCVA) ranged from 0.2 to 0.5 Log MAR in 10 eyes. **Conclusion:** Sutureless and glue free conjunctival autograft technique is easy, safe, effective, prevents potential adverse reactions encountered with the use of foreign materials. This technique has an acceptable pterygium recurrence rate that is comparable to conventional sutured conjunctival autograft for primary pterygium.

Keywords: Pterygium surgery, Sutureless glue free conjunctival autograft, Conjunctival autograft, Amniotic membrane graft.

Number of Tables: 02; Number of Figures: 06; Number of References: 49; Number of Correspondences: 02

1. Dr. Md. Mahmud-ul-Huda

FCPS (Ophth)
Assistant Professor
Department of Eye
Sheikh Hasina Medical College, Jamalpur.

*2. Corresponding Author:

Dr. Sajed Abdul Khaleque

FCPS (Ophth)
Associate Professor
Department of Eye
Ibn Sina Medical College, Dhaka.

Introduction

Pterygium is a degenerative ocular surface disorder with wing-shaped fibro-vascular growth of the subconjunctival tissue onto the cornea. Pterygium (derived from pterygion, ancient Greek for wing) is a common ocular disease seen mostly in tropical and subtropical areas between the latitudes 30 north and south of the equator^{1,2}. Pterygium is almost always in the palpebral fissure and thought to be caused by increased light exposure, dust, dryness, heat and wind. Although it can be easily excised, it has a high rate of recurrence ranging from 24% to 89%³. It is a common ocular surface disease, but also potentially blinding, so different surgical procedures have been used to prevent it.

The pathogenesis of pterygia is still not completely understood. An overall view of the growth process reveals a multiplicity of factors that are correlated and interrelated⁴. Recent evidence implicates anti-apoptotic mechanisms, immunological mechanisms, cytokines, growth factors, extracellular matrix modulators, genetic factors and viral infections, among other possible causative factors^{5,6}. The prevalence rates vary widely (from 2% to 29%),⁷ but generally they are higher in the tropics than at temperate latitudes^{8,9}. It is accepted that pterygium occurs in an equatorial belt delimited by Latitude 40N and S, associating it with ultra-violet light⁹⁻¹¹. Prevalence increases geographically towards the equator and is greater in people exposed to outdoor environments¹². In addition; there are associations with rural regions, increasing age and male gender, which correlate with outdoor work¹³.

Early pterygium is usually asymptomatic. Pterygium causes dryness, burning and itching due to irregular wetting of the cornea. Pterygium causes defective vision due to induced astigmatism or direct encroachment onto the visual axis. Lesions larger than 3.5mm onto the cornea are likely to be associated with >1 Diopter astigmatism¹⁴. In early pterygium patients can be advised to use lubricants and protective eyewear.

Surgical Techniques

Recurrence is the most common complication of pterygium surgery. Several techniques have been advised to reduce the rate of recurrence. These include bare sclera excision, conjunctival and conjunctival limbal auto graft and use of amniotic membrane¹⁵. In addition several adjunctive therapies included the use

of Beta irradiation, thiotepa, 5-FU, and mitomycin C has been recommended due to their antifibrotic and anti angiogenic properties. High recurrence rates are weighted against eye threatening postoperative complications. Amniotic membrane transplantation is used for advanced cases with bilateral heads or those who might need glaucoma surgery later¹⁶. Recently, with the popularity of conjunctival autograft and use of antimetabolites such as mitomycin C and 5-Fluorouracil the incidence of recurrence has been greatly reduced up to 12%¹⁷⁻¹⁹. The role of carbon dioxide and eximer lasers in pterygium surgery remains uncertain. Additionally, the relative benefits and risks are debatable of physiochemical methods to prevent recurrence. For example possible complications of mitomycin C and beta-irradiation include aseptic necrosis of the sclera and cornea, cataract, persistent epithelial defects and visual loss²⁰.

Therefore, a simple surgical procedure that can reduce the recurrence rate to an acceptable level with minimal complications and without the use of potentially toxic drugs or radiotherapy would be ideal for the management of pterygium. Recent reports favor the use of fibrin glue above sutures. The use of fibrin glue has been reported to improve comfort, decrease surgical time, reduce complications and recurrence rates²¹⁻²⁴. Suture-related complications include infection, prolonged operating time, postoperative discomfort, suture abscesses, buttonholes, and pyogenic granuloma which usually require a second surgery for removal and chronic inflammation,^{25,26}. Plasma-derived fibrin glue has the potential risk of prion disease transmission and anaphylaxis in susceptible individuals.

The latest approach is fixation of the graft with autologous blood, a technique also known as suture and glue free autologous graft²⁷. Patients own blood is used as a bio-adhesive or fixative²⁹. Autologous blood is natural, has no extra cost, no associated risk and can overcome post operative irritation, redness, and foreign body sensation. Surgical time is very less when compared to suturing technique^{28,29}. Sutureless grafting has been used successfully in gingival grafts,³⁰ and represents a similar mucosal membrane tissue environment to the conjunctiva of the eye. In this study, we compare and evaluate the safety and efficacy of sutureless glue free limbal conjunctival autograft and conventional sutured autograft for the management of primary pterygium. With this approach, after the pterygium and associated conjunctiva are excised, the surgeon allows a thin film of blood clot to form over the bare area. Any active bleeding is stopped by direct tamponade. Next, a thin, Tenon-free conjunctival auto graft, with or without inclusion of limbal stem cells, is fashioned. After the graft is aligned, it is placed over the blood film in the bare area, and the edges are held with forceps, usually for three to five minutes, to give adequate time for graft fixation to occur.

Materials and Methods

Type of Study was prospective study. The present study was conducted in Department of Ophthalmology,

250 bedded General Hospital Jamalpur. 176 patients of nasal pterygium were included in the group [172 were primary nasal pterygium and 4 were Recurrent pterygium]. 76 patients underwent pterygium excision with suture and glue free autologous graft and 100 patients underwent pterygium excision with suture to secure the graft. Subjects included in the study were from 24 to 70 years of age having pterygium (primary and recurrent) involving any eye. Necessary approval from Institute was obtained beforehand. Written informed consent was taken from each patient. Preoperative ocular examination included slit lamp biomicroscopy, fundus examination, and photographic documentation of the pterygium. Surgeries were done from 15.09.16 to 30.11.16 and 01.11.2017 to 26.08.2018 followed up upto October 2018.

Inclusion criteria were primary nasal pterygium and recurrent pterygium.

Exclusion criteria were temporal pterygium, atrophic pterygium, pseudo pterygium, double head pterygium, ocular surface pathology, patients taking oral nonsteroidal anti-inflammatory drug (NSAID) and anticoagulant, active infection or inflammation, symblepharon, past ocular surgery within last 6 months, trauma, systemic diseases such as diabetes mellitus, collagen vascular disease, pregnancy/bleeding disorders.

Indications of Surgery

- Pterygium causing foreign body sensation
- Encroachment of the pupillary area threatening the visual axis
- Defective vision from induced astigmatism
- 3 to 4 mm encroachment on the cornea
- Rapid growth with cosmetic concerns
- Diplopia due to interference with ocular movements

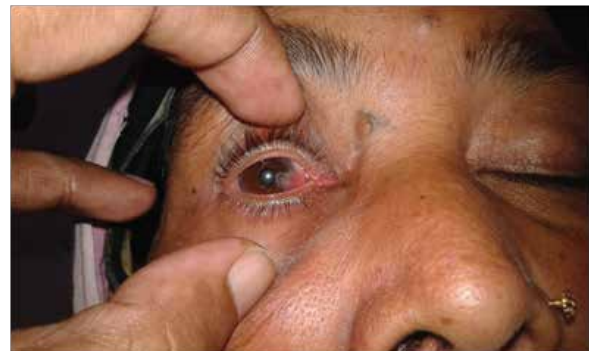

Figure-1: A case of pre-operative primary right nasal pterygium.

The patients were randomly assigned into one of two groups: group 1 underwent sutureless and glue free limbal conjunctival autograft (n = 76 eyes) and group 2 underwent free limbal conjunctival autograft with suturing, (n = 100 eyes). The technique used in our study is simple randomization technique³¹. This technique maintains complete randomization of patient assignment to a particular group. The most common and basic method of simple randomization is a coin toss. For example, with the two treatment groups (group 1 versus group 2), each side of the coin determines the assignment of each patient to a group.

Surgical Technique

The goals of pterygium surgery were to remove the pterygium, restore the conjunctival anatomy, leave the cornea as smooth and clear as possible, and prevent recurrence. Simple pterygium excision was performed under peribulbar anesthesia (Xylocaine 2%). All the surgeries were done under a microscope by the same single surgeon using the same technique. Taking all aseptic precautionary, eyelid was then separated by a speculum, and sub-conjunctival and sub-ptyerygial 0.5 ml lignocaine solution (xylocaine 2%) was injected. Local anesthesia was used to balloon the pterygium separating it from the sclera. Gentle massage over the lesion was applied by cotton tipped applicator for few seconds. The neck of the pterygium was then lifted up with the help of fine toothed forceps, while the head of the pterygium was gently avulsed from the cornea by placing closed tips of a curved corneal scissors or Iris repository underneath the neck of the pterygium mass, keeping the same constant tractional force throughout. Gentle dissection was then carried out in between the conjunctiva and the sclera with the help of crescent knife, to resect at least 4–5 mm the pterygium mass that included both the superior and inferior border. Neither cautery nor saline irrigation was used throughout the surgery, except active bleeding, with bi-polar cautery whenever required to check excess hemorrhage. The size of the bare sclera defect was then measured with Castroviejo calipers. Corneal care was taken by applying wet cotton throughout the procedure. Now, approximately 0.5 ml xylocaine 2% was used to balloon up an supero-temporal conjunctival flap. Corneal scissor was used to make a fine film of 0.5 mm oversized, free conjunctival graft, carefully avoiding inclusion of tenon, or making button-hole within it.

In group 1, hemostasis was allowed to occur spontaneously without use of cautery to provide autologous fibrin to glue the conjunctival graft. The graft was then laid over the bare sclera ensuring same limbus to limbus orientation and the scleral bed was viewed through the transparent conjunctiva to ensure that residual bleeding did not lift the graft. We waited for 5 to 10 min for hemostasis to occur. In cases, where the surgeon appreciated the lack of adequate amount of blood at the recipient site, episcleral blood vessel was intentionally punctured to create bleeding. The eye was then patched for 24 h to 48 h with Chloramphenicol ointment.

In group 2, the graft was sutured in position with 10/0 nylon. First the two limbal corners were sutured into the episclera and then into the conjunctiva keeping the limbal edge of the graft on gentle stretch then the posterior corners of the graft were sutured to the bulbar conjunctiva and additional sutures were placed to close the wound edges. Antibiotic ointment at the end of the procedure.

Post-operatively a pressure eye patch was applied. The eye was assessed for symptom, graft adherence, or any

complication(s) under slit lamp. Postoperatively, patient was put on topical antibiotic and steroid combination for first 2 weeks thereafter tapered over next 4. The patients were instructed to avoid rubbing their eyes and avoid dust, heat, direct sun exposure. The patients were also advised to wear sun glasses to reduce UVB exposure.

Thereafter, an attempted follow-up of cumulative 6 months (at postoperative day 1, 7, 15, 30, 120, and 180) was done to every patient. At each postoperative visit, thorough slit lamp examination, tonometry were done, and any recurrence, complication(s), or any complaint were recorded. The primary outcome measure was the recurrence and the secondary measures were complication(s) and surgical time.

The main postoperative outcomes noted were the recurrence rate which was defined as fibrovascular proliferation invading the cornea more than 1.5 mm at the site of previously excised pterygium, graft dehiscence, graft retraction. The secondary outcomes were duration of surgery, postoperative pain, foreign body sensation, photophobia, hyperemia, chemosis, overall satisfaction and the complications as, persistent epithelial defect, dellen, inclusion cyst, pyogenic granuloma, conjunctival edema, corneo-scleral necrosis, infective scleritis, keratitis and endophthalmitis.

Results

The pterygia were located nasally in all eyes for both groups. Patient age in both groups ranged from 25 to 71 years (mean, years) (Table I). There were 77 males and 99 females enrolled in this study. In 96 eyes, pterygia were present in the right eye and 80 in the left eye. There was no statistically difference in age between groups ($P > 0.05$). The two groups were clinically similar regarding the size of the pterygium.

Table-I: Clinical data.

Age group	No. of patient (176)		Male (77)		Female (99)	
	Group 1	Group 2	Group 1	Group 2	Group 1	Group 2
<20	0	0	0	0	0	0
21-30	11	10	7	5	4	5
31-40	35	21	17	7	18	14
41-50	29	26	15	8	14	18
51-60	19	16	7	6	12	10
61-70	5	3	3	2	2	1
>71	1	0	0	0	1	0
Total	100	76	49	28	51	48

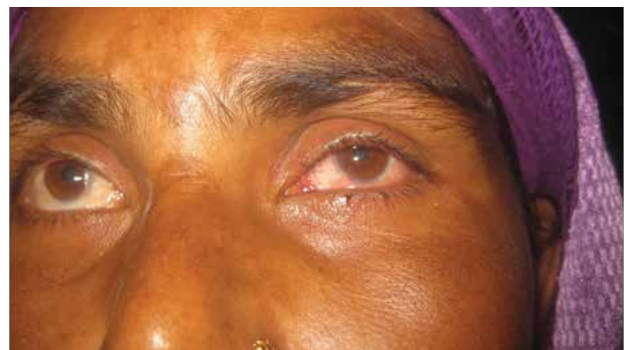

Figure-2: A case of post-operative sutureless and glue free conjunctival limbal autograft in place.

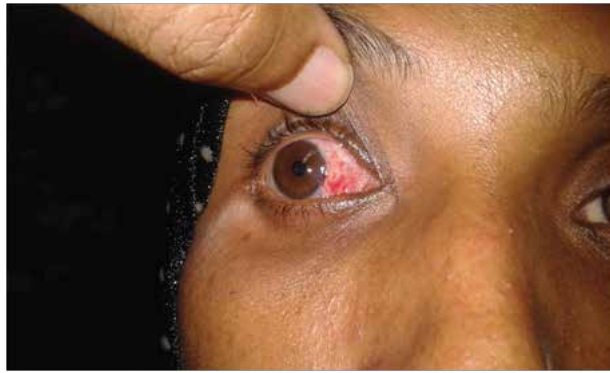

Figure-3: A case of post-operative conventional sutured conjunctival limbal autograft by Nylon 10/0.

Table II presents the main and secondary postoperative outcomes. The recurrence rate was 1.3 % (1 eyes) in group 1. Recurrence in group 1 occurred after 3 months. The recurrence rate was 2 % (2 eyes) in group 2. All cases of recurrence in group 2 occurred after 6 months. Graft dehiscence occurred in 1.3% (1 eyes) in group 1 and there were no cases of graft dehiscence in group 2. It occurred following vigorous rubbing of the eye on the 6th postoperative day. Patient was treated by suturing the same graft with (10/0 nylon sutures).

Table-II: Showing postoperative main and secondary outcomes.

	Group 1 N = (76 eyes)	Group 2 N = (100 eyes)
Haemorrhage	2 (2.6%)	8 (8%)
Graft retraction	3 (3.9)	0 (0%)
Graft I dehiscence	1 (1.3%)	0 (0%)
Conjunctival edema	5 (6.6%)	4 (4%)
Conjunctival granuloma	0 (0%)	3 (3%)
Dellen	0 (0%)	2 (2%)
Conjunctival cyst	0 (0%)	1 (1%)
Recurrence	1 (1.3%)	2 (2%)
Scleral thinning	0 (0%)	0 (0%)
Scleral necrosis	0 (0%)	0 (0%)
Symblepharon	0 (0%)	0 (0%)
moderate Foreign body sensation	8 (10.5 %)	91 (91%)

Early graft retraction with exposure of scleral bed (Fig-4) occurred in 3 eyes (3.9 %) in group 1 and in 4 eyes (4%) in group 2 within the first postoperative week due to conjunctival edema and chemosis. All cases were resolved with conservative management

Conjunctival edema (Fig-5) occurred in 5 eyes (6.6%) in group 1 and in 4 eyes (4%) in group 2. Most cases of conjunctival edema resolved gradually within the first post-operative week. Conjunctival granuloma (Fig-6) occurred only in group 2 in three eyes (3%), all of them treated by surgical excision within the first post-operative month. Conjunctival cyst occurred in one eye (1%) in group 2 and dellen occurred in two eye (2%) in group 2. There are no anesthetic complications, graft necrosis, symblepharon, scleral necrosis or thinning, excessive bleeding, globe perforation or injury to medial rectus in all of patient groups.

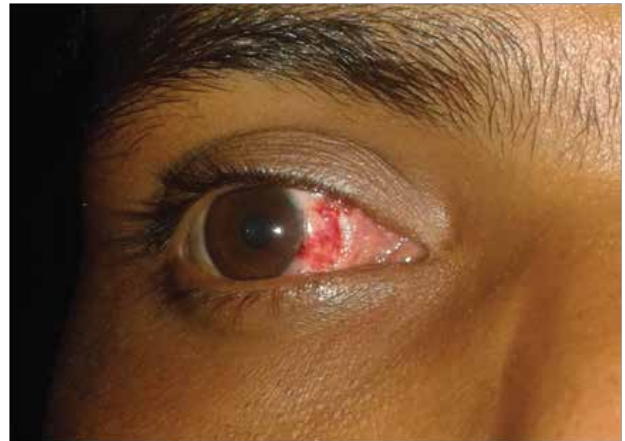

Figure-4: A case of post-operative graft retraction reported in group 1.

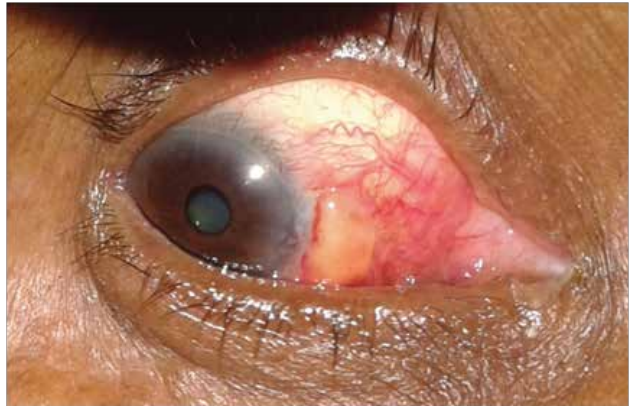

Figure-5: A case of post-operative graft retraction reported in group 1.

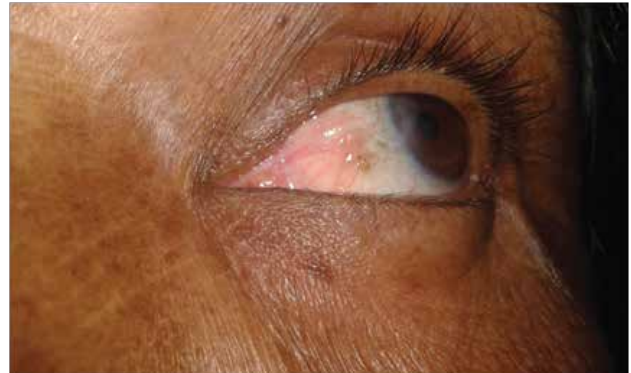


Figure-6: A case of post-operative Stitch granuloma reported in group 2.

Clinically significant difference between groups in the postoperative signs and symptoms on visits day 3, 1 week, 2 weeks and 3 weeks post-operatively. Moderate foreign body sensation was experienced by 8(10.5%) patients of group 1, whereas 91(91%) patients of group 2 had the same.

Discussion

Pterygium surgery should ideally have a low or no recurrence, minimal complications and be cosmetically acceptable. Conjunctiva auto graft using sutures was a standard procedure. The grafts were stable with acceptable cosmetic results. Suture related problems like postoperative inflammation, granuloma formation, pain, foreign body sensation

were present. The presence of sutures may lead to prolonged healing and fibrosis. Surgical techniques for the management of pterygium vary, but high recurrence rates after successful excision remain a challenge. The aim of pterygium surgery is to excise the pterygium and prevent its recurrence. However, there are very few clinical guidelines for optimal treatment that lower recurrence and complication rates. The variety of techniques, range from the bare sclera procedure to more complex approaches, such as amniotic membrane transplantation and lamellar keratoplasty, including conjunctival autograft, and limbal conjunctival transplant, conjunctival flap, conjunctival rotation autograft surgery, cultivated conjunctival transplant (ex-vivo expanded conjunctival epithelial sheet) and use of fibrin glue. Adjunctive therapies include Beta irradiation, Thiotepa, 5-Fluorouracil, Daunorubicin, and mitomycin C (MMC)³²⁻³⁵.

Bare sclera excision (BSE) has an unacceptably high recurrence rate (40–60%) and has become obsolete. BSE with perioperative MMC,³⁶⁻³⁸ preoperative subconjunctival injection, intraoperative application and postoperative drops had yielded better outcomes, but the risk of complications has made this procedure less favorable. BSE with beta irradiation,³⁹ has resulted in encouraging outcomes (13% recurrence); however it has toxic and serious complications.

Pterygium excision with limbal conjunctival autograft,⁴⁰ has been reported to be more effective with low recurrence but it may compromise the corneal stem cell population. Additionally, adjunctive use of amniotic membrane graft results in low recurrence but costly^{37,41}.

Fibrin glue has been used as an alternative to sutures for securing the conjunctival grafts²³. A study has reported recurrence rate of 5.3% for glue versus 13.5% for sutures and suggested that immediate adherence of the graft and lack of postoperative inflammation may inhibit fibroblast ingrowth and reduce the recurrence²³. The main issue in using commercial fibrin glue, despite viral inactivation techniques, is the transmission of infectious agents such as parvovirus B19 (HPV B19) and prions⁴². Furthermore, anaphylactic reaction has been reported after the use of (TISSEEL) fibrin sealant which was due to bovine protein aprotinin⁴³. Foroutan et al.⁴² prepared autologous fibrin glue, though much safer but it is not yet used widely because of the duration it takes to procure the fibrin and lack of laboratory facilities at all centers. Fibrinogen compounds may be susceptible to inactivation by iodine preparations used for conjunctival disinfection before pterygium surgery⁴⁴.

In our study we compared the two techniques of sutureless and glue free conjunctival limbal autograft (group1) with the conventional sutured conjunctival limbal autograft (group2) in primary pterygium surgery.

The recurrence rate (1.3%) in group 1 was comparable to group 2 (2%). Massautis et al.⁴⁵ stated that the concept of surgical success in pterygium surgery can be defined as the provision of a white cosmetic conjunctiva, with

no persistent symptoms and a low recurrence rate (less than 10%). The recurrence rate in our study agrees with The Massautis et al.'s criteria. The recurrence rate is also similar to Malik et al.⁴⁶ who reported recurrence rate of 2.5% using a similar procedure of sutureless and glue free graft.

Graft dehiscence is a recognized complication of techniques using glue^{47,48}. Froutan et al.⁴² reported 13.33% rate of graft dehiscence using autologous fibrin and attributed this to a low concentration of thrombin and fibrinogen in autologous glue compared to a commercial preparation. In our study graft dehiscence occurred in 1 eye (1.3%) in group 1, and did not occur in group 2. The case in group 1, was due to a patient rubbing his eye vigorously. Hence, we instruct patients to use a protective shell and not to rub the eye in the 1st week post-operatively. Additionally, meticulous dissections of thin donor limbal conjunctival autograft free of Tenons capsule are mandatory for successful graft uptake.

Graft retraction was reported by Tan²⁶ who advocated sub-conjunctival fibrosis and recommended meticulous dissection of sub-epithelial graft tissue. Foroutan et al.⁴² reported 20% of cases with graft retraction, in our study graft retraction occurred in 3 eyes out of 76 (3.9%) eyes in group 1 and 4 eyes (4%) in group 2. All the cases of graft retraction were due to conjunctival chemosis and edema and were resolved with conservative treatment. In comparison, Wit et al.⁴⁴ reported no graft displacement and postulated that sutureless and glue free graft resulted in even tension across the whole graft interface and no direct tension on the free edges resulting in reduced stimulus for sub-conjunctival scar formation. Wit et al.⁴⁴ also proposed that the apposition of the eye lids to the bulbar conjunctiva provides a natural biological dressing, compression, and a smooth frictionless surface.

Pyogenic granuloma occurred in 3 eyes out of 100 (3%) eyes in group 2 and did not occur in group 1, cyst formation occurred in one eye (1%) in group 2 and dellen occurred in two eyes (2%) in group 2. These outcomes indicate that complications related to sutures are more common in group 2 despite using 10/0 nylon which induces minimal reaction and were removed after 2 weeks with some discomfort and foreign body sensation post-operatively.

Conjunctival edema occurred in our study in 5 eyes (6.6%) in group 1 and (4%) in group 2, using interrupted 10/0 nylon suture in group 2 which allows for any fluid build up to escape through the intervening spaces rather than precipitating a minimal reaction. Most of the cases resolved spontaneously with conservative treatment.

The mean operative time in group 1 was 15 (±1) min and 18 (±1) min in group 2. These times are comparable however they are longer than other studies^{49,44} using fibrin glue which reported average operative time of 16 min (range 14–16) and 20 min (range 20–29) in suture group and reported 14 (±1.4) min in suture-less and glue free conjunctival autograft. Although our study was conducted over a two-year duration, we believe it was

worthwhile to provide the patients with the benefits of suture-less and glue free conjunctival limbal autograft.

Our results confirmed significantly lower post-operative signs and symptoms including pain, FB sensation, photophobia, hyperemia and chemosis at all visits in the first post-operative month as well as significantly higher overall patient satisfaction in group 1 compared to group 2. None of our patients developed serious complications such as scleral necrosis, sclera thinning, graft necrosis, symblepharon, excessive bleeding, medial rectus muscle injury, or globe perforation.

Conclusion

Pterygium excision and conjunctival auto graft with autologous blood is a viable and better surgical option for management of primary as well as recurrent pterygium. The feasibility of adherence of graft without glue and sutures is promising. The potential risks associated with the use of fibrin glue and suture related problems can be avoided in this technique. This procedure has excellent outcome. It is cost effective, time saving, easy to perform, less patient discomfort, greater patient satisfaction and safe for the patients with good cosmetic output.

Conflict of Interests: None.

Acknowledgement

We are thankful to the Principal, Jamalpur Medical College, Jamalpur and assistant director(AD), 250 bed General Hospital, Jamalpur for their cooperation.

References

1. K.F. Schulz, D.G. Altman, D. Moher for the CONSORT Group. CONSORT 2010 Statement: updated guidelines for reporting parallel group randomized trials. *BMJ*. 2010; 340: c332.
<https://doi.org/10.1136/bmj.c332>
PMid:20332509 PMCID:PMC2844940
2. J.W. Rosenthal Chronology of pterygium therapy. *Am J Ophthalmol*. 1953; 36: 1601.
[https://doi.org/10.1016/0002-9394\(53\)91792-9](https://doi.org/10.1016/0002-9394(53)91792-9)
3. V.P. Gupta Conjunctival transplantation for pterygium. *DJO*. 1997; 5: 5-12.
4. Solomon A: Pterygium. *BrJOphthalmol*. 2006; 90: 665-666.
<https://doi.org/10.1136/bjo.2006.091413>
PMid:16714259 PMCID:PMC1860212
5. Bradley J, Yang W, Bradley R, Reid T, Schwab I. The science of pterygia. *BrJOphthalmol*. 2010; 94(7): 815-820.
<https://doi.org/10.1136/bjo.2008.151852>
PMid:19515643
6. Song Y, Ryu Y, Choi S, Kim C. The involvement of adult stem cells originated from bone marrow in the pathogenesis of pterygia. *Yonsei MedJ*. 2005; 46: 687-692.
<https://doi.org/10.3349/ymj.2005.46.5.687>
PMid:16259068 PMCID:PMC2810576
7. Leonard P, Jocelyn L, Donald T. Current concepts and techniques in pterygium treatment. *Curr Opin Ophthalmology*. 2007; 18: 308-313.
<https://doi.org/10.1097/ICU.0b013e3281a7ecbb>
PMid:17568207
8. Gazzard G, Saw S, Farook M, Koh D, Widjaja D, Chia S, et al. Pterygium in Indonesia: prevalence, severity and risk factors. *BrJ Ophthalmol*. 2002; 86:1341-1346.2.
9. Luthra R, Nemesure B, Wu S, Xie S, Leske M. Frequency and risk factors for pterygium in the Barbados Eye Study. *Arch Ophthalmol*. 2001;119:1827-1832.
<https://doi.org/10.1001/archophth.119.12.1827>
PMid:11735795
10. Cameron M. Pterygium throughout the World. Edited by Thomas CC. Illinois: Spring field; 1965.
11. Vojnikovic B, Njiric S, Cocklo M, Toth I, Spanjol J, Marinovic M. Sunlight and incidence of pterigium on Croatian Island Rab: epidemiological study. *Coll Antropol*. 2007; 31: 61-62.
PMid:17469753
12. Ti S, T Seng S. Management of primary and recurrent pterygium using amniotic membrane transplantation. *Curr Opin Ophthalmol*. 2002;13: 204-212.
<https://doi.org/10.1097/00055735-200208000-00003>
PMid:12165701
13. Ma K, Xu L, Jie Y, Jonas J. Prevalence of and factors associated with pterygium in adult Chinese: the Beijing Eye Study. *Cornea*. 2007; 26: 1184-1186.
<https://doi.org/10.1097/ICO.0b013e318151f9c6>
PMid:18043173
14. Ardalan Aminlari, Ravi Singh, David Liang. Management of pterygium. *Ophthalmic Pearls Cornea American Academy of Ophthalmology*. 2010 Nov/dec; *Eye Net*: 37-39.
15. S Srinivasan, M Dollin, PMC Allum, Y Berger, DS Rootman, AR Slomovic. Fibrin glue vs sutures for attaching the conjunctival autograft in pterygium surgery a prospective observer masked clinical trial. *BJO*. 2009; 93: 215-218.
<https://doi.org/10.1136/bjo.2008.145516>
PMid:19019930
16. Pinnita Prabhasawat. Comparison of conjunctival autografts, Amniotic membrane grafts & primary closure for pterygium excision. *Ophthalmology*. 1997 June; 104(6): 974-985.
[https://doi.org/10.1016/S0161-6420\(97\)30197-3](https://doi.org/10.1016/S0161-6420(97)30197-3)
17. G. Singh, N.R. Wilson, C.S. Foster Mitomycin eye drops as treatment for pterygium. *Ophthalmology*. 1988; 95: 813-821.
[https://doi.org/10.1016/S0161-6420\(88\)33104-0](https://doi.org/10.1016/S0161-6420(88)33104-0)
18. W. Kleis, G. PicoThio-TEPA theory to prevent post operative pterygium occurrence and neovascularization. *Am J Ophthalmol*. 1973; 76: 371-373.
[https://doi.org/10.1016/0002-9394\(73\)90493-5](https://doi.org/10.1016/0002-9394(73)90493-5)
19. K.H. Tarr, I.J. Constable Late complications of pterygium treatment. *Br J Ophthalmol*. 1980; 64: 496-505.
<https://doi.org/10.1136/bjo.64.7.496>
PMid:6968590 PMCID:PMC1043747

20. L.A. Gans Surgical treatment of pterygium Focal points: clinical modules for ophthalmologists. American Academy of Ophthalmology, San Francisco. 1996; 14: 2.
21. M. Ayala Results of pterygium surgery using a biologic adhesive Cornea. 2008; 27: 663-667.
<https://doi.org/10.1097/QAL.0b013e31815d105e>
22. H.H. Kim, H.J. Mun, Y.J. Park, K.W. Lee, J.P. Shin Conjunctivolimbal autograft using a fibrin adhesive in pterygium surgery. Korean J Ophthalmol. 2008; 22: 147-154.
23. G. Koranyi, S. Seregard, E.D. Kopp Cut and paste: a no suture, small incision approach to pterygium surgery. Br J Ophthalmol. 2004; 88: 911-914.
<https://doi.org/10.1136/bjo.2003.032854>
PMid:15205236 PMCID:PMC1772242
24. G. Koranyi, S. Seregard, E.D. Kopp The cut-and-paste method for primary pterygium surgery: long-term follow-up. Acta Ophthalmologica Scandinavica. 2005; 83: 298-301.
<https://doi.org/10.1111/j.1600-0420.2005.00465.x>
PMid:15948780
25. B.D. Allan, P. Short, G.J. Crawford, G.D. Barrett, I.J. Constable Pterygium excision with conjunctival autografting: an effective and safe technique. Br J Ophthalmol. 1993; 77: 698-701.
<https://doi.org/10.1136/bjo.77.11.698>
PMid:8280682 PMCID:PMC504627
26. D. Tan Conjunctival grafting for ocular surface disease. Curr Opin Ophthalmol. 1999; 10: 277-281.
<https://doi.org/10.1097/00055735-199908000-00010>
PMid:10621536
27. Jean Shaw, LW Hirst, Santanu Mitra, Jonathan E Moore. Clinical update. Cornea. XEye net. American academy of Ophthalmology A new approach emerges for pterygium surgery. 1953; 36: 1601.
28. Abraham Kurian, Iodine Raghunandhan. KGR. Autologous blood versus fibrin glue for conjunctival autograft adherence in sutureless pterygium surgery. A randomised controlled trail. Nair BJO. 2015; 99: 467-470.
29. Singh PK, Singh S, Vyas C, Singh M. Cornea. Conjunctival autograft without fibrin glue or sutures for pterygium surgery. 2013 Jan; 32 (1): 104-7.
30. H.S. Dorfman, J.E. Kennedy, W.C. Bird Longitudinal evaluation of free autogenous gingival grafts. A four year report J Periodontol. 1982; 53: 349-352.
<https://doi.org/10.1902/jop.1982.53.6.349>
PMid:7050339
31. K.P. Suresh An overview of randomization techniques: an unbiased assessment of outcome in clinical research. J Hum Reprod Sci. 2011; 4 (1): 8-11.
<https://doi.org/10.4103/0974-1208.82352>
PMid:21772732 PMCID:PMC3136079
32. F.D. Mackenzie, L.W. Hirst, B. Kynaston. Recurrence rate and complications of 5-Fluorouracil as chemoadjvant for primary pterygium surgery: preliminary report. Cornea. 2003; 22: 522-526.
<https://doi.org/10.1097/00003226-200308000-00007>
33. C. Akarsu, P. Taner, A. Ergin 5-Fluorouracil as chemo-adjvant for primary pterygium surgery: preliminary report. Cornea. 2003; 22: 522-526
<https://doi.org/10.1097/00003226-200308000-00007>
PMid:12883344
34. S. Dadeya, S. Kamlesh, C. Khurana. Intraoperative daunorubicin versus conjunctival autograft in primary pterygium surgery. Cornea. 2003; 22: 763.
<https://doi.org/10.1097/00003226-200311000-00010>
<https://doi.org/10.1097/00003226-200311000-00011>
35. J.S. Chapman-Smith Pterygium treatment with triethylene thiophosphoramidate. Aust N Z J Ophthalmol. 1992; 20: 129-131.
<https://doi.org/10.1111/j.1442-9071.1992.tb00724.x>
PMid:1389130
36. H.C. Cheng, S.H. Tseng, P.L. Kao, F.K. Chen Low-dose intraoperative mitomycin -C as chemo adjuvant for pterygium excision. Cornea. 2001; 20: 24-29.
<https://doi.org/10.1097/00003226-200101000-00004>
PMid:11188998
37. K.E. Donaldson, E.C. Alfonso Recent advances in pterygium excision. Contemp Ophthalmol. 2003; 2: 1-8.
38. L.W. Hirst The treatment of pterygium. Surv Ophthalmol. 2003; 48: 145-180.
[https://doi.org/10.1016/S0039-6257\(02\)00463-0](https://doi.org/10.1016/S0039-6257(02)00463-0)
39. Y. Nishimura, A. Nakai, T. Yoshimasu. Long-term results of fractionated strontium-90 radiation therapy for pterygia. Int J Radiat Oncol Biol Phys. 2000; 46: 137-141.
[https://doi.org/10.1016/S0360-3016\(99\)00419-8](https://doi.org/10.1016/S0360-3016(99)00419-8)
40. A.K. Wong, S.K. Rao, A.T. Leung, A.S. Poon, D.S. Lam Inferior limbal-conjunctival autograft transplantation for recurrent pterygium. Indian J Ophthalmol. 2000; 48: 21-24.
PMid:11271929
41. D.H. Ma, L.C. See, S.B. Liao, R.J. Tsai Amniotic membrane graft for primary pterygium: comparison with conjunctival autograft and topical mytomycin C treatment. Br J Ophthalmol. 2000; 84: 973-978.
<https://doi.org/10.1136/bjo.84.9.973>
PMid:10966947 PMCID:PMC1723628

42. A. Foroutan, F. Beigzadeh, M.J. Ghaempanah, P. Eshghi, N. Amirizadeh, H. Sianati, et al. Efficacy of autologous fibrin glue for primary pterygium surgery with conjunctival autograft. *Iranian J Ophthalmol.* 2011; 23: 39-47.
43. A.M. Oswald, L.M. Joly, C. Gury, M. Disdet, V. Leduc, G. Kanny Anesthesiology, Fatal intraoperative anaphylaxis related to aprotinin after local application of fibrin glue. 2003; 99: 762-763.
44. D. Wit, I. Athanasiadis, A. Sharma, J. Moore. Sutureless and glue free conjunctival autograft in pterygium surgery: a case series. *Eye.* 2010; 24: 1474-1477.
45. P. Massautis, S. Khemka, W. Ayliffe. Clinical outcome study of a modified surgical technique for pterygium excision. *Can J Ophthalmol.* 2006; 41: 704-708.
46. K.P.S. Malik, R. Goel, S.K. Gupta, S. Kamal, V.K. Malik, S. Singh. Efficacy of sutureless and glue free limbal conjunctival autograft for primary pterygium surgery. *Nepal J Ophthalmol.* 2012; 4(8): 230-235.
47. H.S. Uy, J.M. Reyes, J.D. Flores, R. Lim-Bon-Siong. Comparison of fibrin glue and sutures for attaching conjunctival autografts after pterygium excision. *Ophthalmology.* 2005; 112: 667-671.
48. S. Srinivasan, A.R. Slomovic. Eye rubbing causing conjunctival graft dehiscence following pterygium surgery with fibrin glue. *Eye.* 2007; 21: 865-867.
49. I. Bahar, D. Weinberger, G. Dan, R. Avisar. Fibrin glue versus vicryl sutures for conjunctival closure. *Cornea.* 2006; 25 (10): 1168-1172.c