

## Case Report

# Bilateral Breast Cancer-A Case Report.

Alia M Y<sup>1</sup>, Mostafa S G<sup>2</sup>, Baki M O<sup>3</sup>, Kaderd K M<sup>4</sup>, Shamim A<sup>5</sup>, Chowdhury Q<sup>6</sup>

### Abstract:

*We present a case of a 40 year old female who presented with a short history of synchronous, bilateral breast lumps. Core biopsies of both lesions revealed duct cell carcinoma in both breasts. The recognized aggressive course and rapid progression of bilateral synchronous tumors was apparent in our patient. This case illustrates the importance of screening for metastatic disease in patients presenting with bilateral breast lumps.*

### Introduction:

A 40 year old premenopausal lady presented with a short history of breast lumps in her left breast in November, 2008. On examination a 3 cm discrete lump was palpated in the upper outer quadrant of her left breast and a 2cm lump in the axillary tail was felt in the right breast and diagnosed as a case of carcinoma left breast (FNAC of the lump, Lt. breast):

Duct cell carcinoma, NOS, grade-1(Robinson's cytological grading). After one month she also complained another lump in her right breast, after examination and FNAC also diagnosed as a case of carcinoma Rt. breast (FNAC, Rt. breast: Features are suggestive of Infiltrating ductal carcinoma (Fig No:1). Her disease staging were Lt. Breast Stage: T2N1Mx and Rt. Breast Stage:T1NxMx. Other systemic examinations revealed nothing relevant. Routine blood test showed Hb 72% total & differential count of WBC within normal limit and ESR 57mm in the 1st hour. RBS-5.5 mmol/l, S. creatinine- .80 mg/dl, SGPT-39.0 U/L, SGOT-23.5 U/L,CA-125; 14.40U/ml, CA 15-3; 17.20U / ml.S.Alkaline Phosphatase-44U/L.

Ultrasonography of the whole abdomen revealed normal study. X-ray chest P/A view & E.C.G finding were normal.

1. Md. Yeaqub Ali  
Asst. professor, Radiation Oncology  
National Institute of Cancer Research and Hospital Mohakhali, Dhaka.
2. SK.Golam Mostafa  
Professor and Head of the department of Radiation Oncology,  
National Institute of Cancer Research and Hospital Mohakhali, Dhaka.
3. Mollah Obayedullah Baki  
Director and Professor of Radiation Oncology  
National Institute of Cancer Research and Hospital Mohakhali, Dhaka.
4. Kazi Manzur Kader  
Associate Professor of Radiation Oncology  
National Institute of Cancer Research and Hospital Mohakhali, Dhaka.
5. Ahsan Shamim  
Associate Professor of Radiation Oncology and Project Director,  
National Institute of Cancer Research and Hospital Mohakhali, Dhaka.
6. Qamruzzaman Chowdhury  
Associate Professor of Radiation Oncology,  
National Institute of Cancer Research and Hospital Mohakhali, Dhaka.

She had done bilateral mastectomy with axillary clearance simultaneously on 20-02-2009.

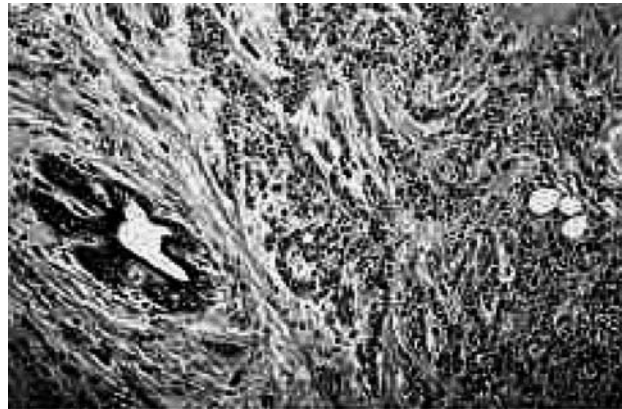


Fig. 1: Prototypical invasive ductal carcinoma

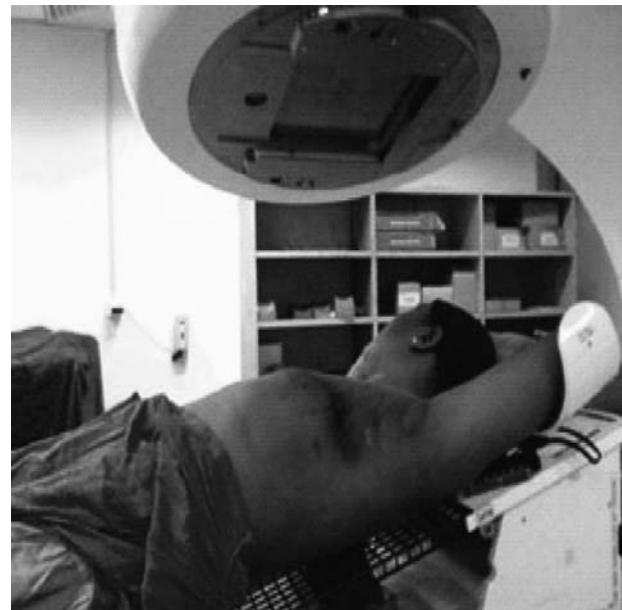

Fig no; 2: Patient is on Radiotherapy (LINAC machine) treatment couch.

After surgery she received total 8 cycles of chemotherapy till 31-05-2009. First 4 cycles were FAC (Inj.FU 750 mg+Inj. Adriamycin90 mg + Inj. Cyclophosphamide 900mg) and the rest 4 cycles were Inj.Taxotere 80mg +Inj. Doxorubicin 90mg i.v. X 3 Weekly cycles. Then we start loco-regional radiotherapy for her (Fig no : 2) into the left breast area from 29-07-2009 to 06-09-2009. Thereafter we

treated her by loco-regional radiotherapy on the right breast area from 12-09-2009 to 20-10-2009. She had no significant family history.

A whole body bone scan confirmed on 5<sup>th</sup> January 2009 revealed: normal whole body bone scan.

### Discussion

Synchronous tumours are defined as two or more tumours where each are malignant, occurring simultaneously and where neither can originate with metastasis from another tumour<sup>2</sup>. Our patients bilateral multiple tumours were consistent with this definition of being synchronous. Bilateral synchronous breast cancer is an uncommon finding in women presenting with multiple breast lumps. It is reported to account for only 2% of women with breast cancer whereas metachronous breast tumours account for 5% of cancer cases<sup>3</sup>. The overall incidence of multiple primary cancers among cancer patients is 0.83%. The interval between the onsets of two cancers varies from 1 month to 30 years. The majority of the patients are male. The most commonly diagnosed multiple primary cancers are larynx and lung cancers, followed by lip and larynx cancers. Such malignancies, which occur together, probably have similar etiopathogenetic mechanisms<sup>4</sup>. The incidence of synchronous or metachronous contralateral breast cancer was reported as 2.7% in male breast cancer patients, similar to that of women<sup>4</sup>. However, the incidence of synchronous or metachronous cancer was reported as 10.6% for male breast cancer patients, higher than that of women<sup>4</sup>. However it appears that this familial link is more likely with metachronous bilateral breast cancer than either unilateral or synchronous bilateral cases. Furthermore the risk of having breast cancer is substantially increased with a first degree relative with bilateral breast cancer<sup>1</sup>.

Such type of patients are lower disease free survival and high rates of distant metastasis is a recognised feature of bilateral synchronous tumours which therefore has a worse overall survival compared to unilateral tumours<sup>3</sup>. There does not however appear to be any difference in survival if synchronous tumours are compared to the metachronous

ones<sup>5</sup>. She was treated with external radiotherapy to the chest wall, axilla and supraclavicular fossa with doses of 50 Gy (2 Gy dose daily, five weekly fractions) in the left breast from 29-07-2009 to 06-09-2009. Thereafter we treated her by loco-regional radiotherapy on the right breast area from 12-09-2009 to 20-10-2009 as same dose. She had no significant family history. Adjuvant chemo or hormone therapy was not carried out owing to our concept at that time.

**Conclusion:** In conclusion we note that in women, who present with bilateral breast lumps, synchronous tumours should be considered as a possibility of malignancy and investigate for distant metastasis at presentation should be routine even in those who are asymptomatic. It is relatively a rare neoplasm. Only few cases have been reported in the literature. Further study is recommended.

### References:

1. McPherson K, Steel C M, Dixon J M. ABC of breast diseases: Breast cancer epidemiology, risk factors, and genetics. *BMJ*, 2000; 321:624-628.
2. Warren S, Gates O. Multiple primary malignant tumours. A survey of the literature and statistical study. *AM J Cancer* 1932; 16 : 1358-1405.
3. Carmichael AR, Bendall S, Lockerbie L, Prescott R, Bates T. The long term outcome of synchronous bilateral breast cancer is worse than metachronous or unilateral tumours. *Eur J Surg Oncology* 2002;28:388-91.
4. Cutuli BF, Lacroze M, Dilhuydy JM, Florentz P, Velten M, Allavena C, et al. Breast cancer in men: incidence and types of associated previous synchronous and metachronous cancers. *Bull Cancer* 1992; 79:689-96.
5. Zhang T, Zhang BN. Bilateral primary breast cancer: a report of 217 cases. *Zhonghua Zhong Liu Za Zhi*. 2004; 26: 756-8. Chinese.
6. Engin K. Cancers in multiple primary sites. *Int Surg* 1994; 79:33-7.