

Average Working Length of Maxillary Central Incisor- A Single-Centre Study in Bangladesh

Abdullah Al Mahmud^{*1}, Farhad Farzana², Md. Atiqul Islam Rabby³, Iffat Ara Ferdoushi⁴

Abstract

Introduction: The permanent maxillary central incisor is the most visible tooth in the mouth and endodontic treatments are frequently performed in maxillary incisors. Over-instrumentation may cause periradicular inflammation, postoperative pain, and inhibition of the healing process. Working length (WL) determination and maintenance is therefore of major importance. **Materials and Methods:** This prospective study was conducted in Dhaka Dental College & Hospital, Dhaka from May 2013 to November 2013. A total of 39 cases were included in this study. For electronic method of WL determination iPex NSK (Japan) was used. The radiographic working length was determined by evaluating the position of the end of the file in the canal on the radiograph and it was 0.5 to 1.0 mm short of radiological apex. **Results:** Pain (94.9%) and trauma (56.4%) were the most common history among the study population. In clinical findings, caries was the most common (56.4%) than swelling was present in 35.9% cases and discoloration was in 30.8% cases. In all cases we found single root of maxillary central incisors. Mean working length (WL) of our study population by apex locator was 21.423 ± 1.259 and by radiograph it was 21.397 ± 1.176 ; there was no statistically significant difference in WL between these two methods ($p=0.743$). **Conclusion:** According to radiographic method working length of our study population was 21.39 mm. WL of our study population was found to be less than the values found by the other studies population like Caucasians, African, Sinhalese, Mongolian and Korean.

Keywords: Maxillary central incisor, working length, Bangladesh.

Number of Tables: 05; Number of Figures: 03; Number of References: 25; Number of Correspondences: 02.

*1. Corresponding Author:

Dr. Abdullah Al Mahmud

BDS, FCPS

Assistant Professor

Department of Conservative Dentistry & Endodontics
Sapporo Dental College & Hospital, Dhaka.

E-mail: shawonmahmud0212@gmail.com

Mobile: +8801612-207793

2. Dr (Lt. Col) Farhad Farzana

BDS, FCPS

Classified Specialist

Conservative Dentistry & Endodontics
Military Dental Centre, Bogura.

3. Dr. Md. Atiqul Islam Rabby

BDS

Lecturer

Dept. of Conservative Dentistry & Endodontics
Marks Medical College & Dental Unit, Dhaka.

4. Dr. Iffat Ara Ferdoushi

BDS

Lecturer

Department of Paediatric Dentistry
Update Dental College & Hospital, Dhaka.

Introduction:

The prime concern of endodontic treatment is cleaning, disinfecting, shaping & obturation of the root canal system. Root canal preparation and obturation should be within the tooth canal, it should not extend beyond the apical constriction of the root canal¹. Over biomechanical preparation may cause several types of side effect likes periradicular inflammation, postoperative pain and inhibition of healing pathway². So, accurate working length (WL) determination and maintenance is therefore of key importance. The WL is "the distance from a coronal reference point to the point at which canal preparation and filling should terminate"³. Apical constriction coincides with the narrowest diameter of the root canal, anatomically it indicates the apical boundary for the extinction of endodontic treatments⁴, and as it often helps in WL determination³. In clinical setting locating of the AC is critical. In relation to the apical foramen the location of the CDJ is varied⁵. It is commonly accepted as being 0.50-0.75 mm coronal to the apical foramen⁶. The maxillary central incisor (MCI) is the most visible tooth in the mouth. Principle functions of MCI are included incising, speech, articulating providing lip support, maintaining aesthetics and guiding the mandible posteriorly in the final phase of closure and occlusion of posterior teeth⁷. It is so vital in maintained in the dental arch⁷. This is sometimes hard as because the tooth is one of the frequent traumatized tooth⁸; that's why it is the most endodontically treated tooth⁹.

Generally incidents of trauma to this tooth occur between the ages of 11-23 years^{8,10} and more frequently in male¹¹; hence MCI is the most endodontically treated tooth in the dental arch^{12,13}. The majority of the accessible study findings are on Caucasian population of Europe & USA, there is no plenty of information supporting for the use of tooth length in non-Caucasian; especially Bangladeshi people. A review of literature exposed that there is a lack of information on average endodontic working length reference for permanent maxillary central incisors in Bangladeshi. The accessible reference information on known tooth length is based on Caucasians¹⁴ and Asian¹⁵ studies; which are the solitary references for endodontic treatment for Bangladeshi. Open literature shows a difference in dental anatomy based on sex, race and genetics¹⁶⁻¹⁸. This study is to establish an average working length for the permanent maxillary central incisor in the Bangladeshi population and explore the similarity and dissimilarity with other populations; and to identify any gender variation.

Materials and Methods:

This study was a Prospective study, conducted in the department of Conservative Dentistry & Endodontic of Dhaka Dental College & Hospital, Dhaka, Bangladesh. The study was conducted from May 2013 to November 2013. A total of 39 patients were taken as sample population for this study came to the department. The sampling method was purposive sampling. The central limit theorem¹⁹ suggest that at least 30 cases are required for calculating mean with an assumption of normal distribution. Reviewing the previous similar studies, this sample size appeared as a well acceptable sample size for this study.

Patients of 15 to 60 years old regardless of sex and race were included in this study. Patients, who were aged above 60 years and below 15 years, tooth with open apices or blunderbass canal, apical resorption, calcification in the root canal, Fractured or broken tooth, patient with cardiac prosthesis were excluded from this study.

Working length was the distance from a coronal reference point to the point at which canal preparation and obturation should terminate. Working length was estimated by the electronic method first and then by the radiographic method. For electronic method of working length estimation apex locator of Fourth generation named iPex from NSK(Japan) was used. Working length determination was began first with apex locator (iPEX) according to the device's manufacturer instruction. Then the same file in the same length that was obtained by electronic method was again inserted into the canal and a radiograph was taken. Then the radiographic working length was determined by evaluating the position of the end of the file in the canal on the radiograph and it was 0.5 to 1.0 mm short of radiological apex. And this value was then documented as estimated working length by radiographic method. Finally, the acquired values by these two methods were compared statistically.

Ethical clearance was obtained from the Ethical Committee of Dhaka Dental College. Written informed consent was taken from the patient's or legal guardian. Patient confidentiality was strictly maintained. No names, addresses or contact details of the patients were divulged.

Statistical analysis using descriptive statistic was done. All quantitative values were presented as mean \pm SD for continuous data and as percentages for categorical data. Qualitative data were presented as frequency and percentage. Quantitative data was analyzed by student's t-test. All tests were two-tailed and statistically significant results will be considered when p value < 0.05. All statistical operations were analyzed by SPSS version 20 and Micro-soft Excel 10.

Results:

A total of 39 patients, aged 15 to 60 years were included in this study. Among them 20(51.3%) were male and 19(48.7%) were female, with M:F ratio of 1:1.05 (Figure 1). Majority (53.9%) of the patients were within 21-30 years of age, mean age of our study population was 29.51 \pm 10.05 (Table I). Pain was the most common (94.9%) history among the study population. History of trauma was in 22(56.4%) cases. In clinical findings, caries was the most common (43.6%) than swelling was present in 35.9% cases; discoloration was in 30.8% cases and sinus in 20.5% cases (Figure 2). In our study 100% cases we found single root of maxillary central incisors (Table II). Mean working length (WL) of our study population by apex locator was 21.423 \pm 1.259 and by radiograph it was 21.397 \pm 1.176; there was no statistically significant difference of WL between these two methods (p=0.743) (Table III). Distribution of mean working length in male and female is shown in figure 3. The mean WL of female was significantly less than male (p< 0.5) (Table IV). Table V shows working length of maxillary central incisor in different ethnic population. The overall variation of the WL of different populations from our study population were ranged from +0.61 to +4.41 mm. So WL of our study population was found to be less than the values found by the other researchers in different countries.

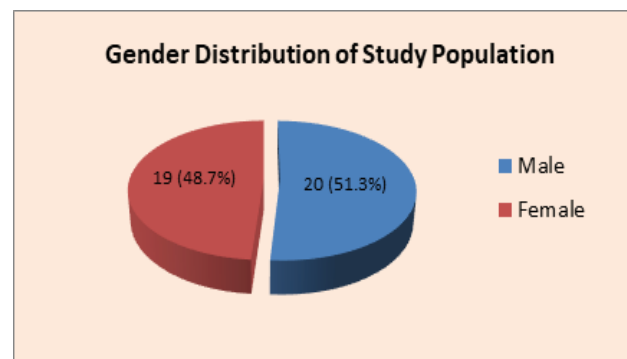


Figure 1: Gender distribution of the study population

Table I: Age with sex distribution of the study population

Age	Male n (%)	Female n (%)	Total n (%)
15-20	1(2.6)	4(10.3%)	5(12.8%)
21-25	5(12.8)	7(17.9%)	12(30.8%)
26-30	6(15.4)	3(7.7%)	9(23.1%)
31-35	2(5.1)	2(5.1%)	4(10.3%)
36-40	3(7.7)	3(7.7%)	6(15.4%)
41-45	0	0	0
46-50	1(2.6)	0	1(2.6)
51-55	1(2.6)	0	1(2.6)
56-60	1(2.6)	0	1(2.6)
Total	20(51.3%)	19(48.7%)	39(100.0%)
Min-Max			
15-60	32.4±11.4	26.47±7.46	29.51±10.05
P	0.065		

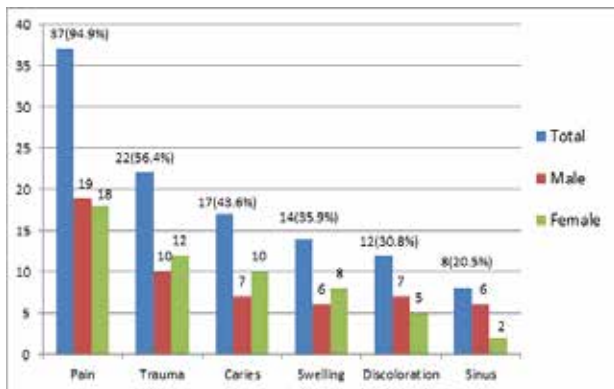


Figure 2: Clinical history & findings of study population

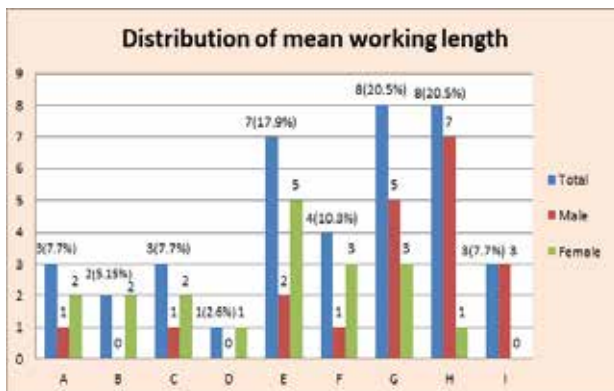


Figure 3: Distribution of mean working length in male and female

Key: A=19mm, B= 19.5mm, C=20mm, D=20.5mm, E=21mm, F=21.5mm, G=22mm, H=22.5mm, I=23mm

Table II: The percentage of the number of maxillary incisor root

Number of Roots	n (%)
Single root	39 (100%)
>1 (More than one)	-

Table III: Measured working length (WL) of the study population

WL by Apex locator	WL by Radiograph	P
21.423±1.259	21.397±1.176	0.743

Table IV: Working length by Apex locator Vs Radiograph in Male & Female

Method	WL in male	WL in female	P
Apex Locator	21.95±1.05	20.87±1.25	0.0057
Radiograph	21.95±1.02	20.82±1.06	0.0016

Table V: Working length of maxillary central incisor in different ethnic population

Principle Author & year of publication	Study country/ Ethnic group	Method of length measurement	Length in mm	Variation from our study population (in mm)
Harries EF 2006 ²⁵	UAS (White American)	CBCT	25.8	+4.41
Sede MA, 2013 ²⁰	Nigeria (African)	Both Apex locator & radiograph	25.0	+3.61
Kim E 2005 ²²	USA (Caucasian)	Both Apex locator & radiograph	23.5	+2.11
JayawardenaCK 2009 ²³	Sri Lanka (Sinhalese)	Digital calipers on extracted tooth	23.12	+1.73
Chi SH 2017 ²⁴	South Korea (Korean)	CBCT	22.8	+1.41
Carrotte P 2004 ¹⁴	UK, USA (Caucasian)	Radiograph	22.5	+1.11
Kartika Dewi, 2017 ²¹	Indonesia (Mongoloid)	Radiograph (with digital caliper)	22.03	+0.64
Kim E, 2005 ²²	South Korea (Korean)	Both Apex locator & radiograph	22.0	+0.61

Discussion:

Working length is the distance from a coronal reference point to the point at which canal preparation and obturation should terminate³. Working length was estimated by the electronic method first and then by the radiographic method. The apical foramen is the main apical opening of the root canal. It is frequently eccentrically located away from radiological apex. The apical constrictor is the apical portion of the root canal having the narrowest diameter, this position may vary but it is usually 0.5 to 1.0 mm short of the apical foramen. The determination of the working length and its maintenance during cleaning and shaping procedures are key factors for successful endodontic treatment.

This study has shown that electronic measurements, in general, tend to be same with radiographic measurements. The mean working lengths by electronic method and by radiographic method were 21.42 mm and 21.39 mm with standard deviation of 1.26 and 1.17 respectively. In Paired sample test, mean difference between electronic and radiographic working length at 5% level of significance was 0.0256 mm. Correlation was 0.923. Here, $t = 0.33$, this calculated t value is less than the critical t value. And here $p = 0.74$ at 95% confidence interval, that is $p > 0.05$. So, statistical analysis and comparison revealed that the differences between two measured values are not significant and statistically there is no significant difference between electronic measurement and radiographic measurement in working length determination. So the average tooth length of upper central incisor was founded to be approximately 22 mm. The mean WL of female (20.82 ± 1.06) was significantly less than male (21.95 ± 1.02) ($p = 0.0016$).

To access the tooth & working length of maxillary central incisor, several studies have been done on different ethnic groups in different countries around the world by using different methods^{14,20-25}. Sede MA et al. conducted his study in Nigeria on African population with both apex locator & radiograph²⁰. His study revealed a value of 25.0 mm as the average working length of permanent maxillary central incisor in Nigerian adult. By using same type of methods Kim E et al. founded 23.5 mm as the average working length of maxillary central incisor of Caucasian²². He conducted his study in Philadelphia in USA. In another study by Carrotte P et al. reported 22.5mm was the average length of Caucasian maxillary central incisor. With cone beam computed tomography (CBCT) Harries EF et al. conducted his study among white American people; in his study he found average tooth length of maxillary central incisor was 25.8mm²⁵.

According to Jayawardena CK et al. the mean tooth length of maxillary central incisors of Sri Lankan Sinhalese populations was 23.12; the method was direct measurement with digital calipers on extracted teeth²³. In 2005 Kim E et al. conducting a comparative study of root canal length between Asian (Korean) and Caucasians (USA), in that study it was found that root canal length of maxillary central incisor of Korean people was 20.0mm²². In his study Kim uses both apex locator and radiograph methods. But in another research among Korean by Chi SH it was seen that the mean length of maxillary central incisors was 22.8mm²⁴. Chi SH used cone beam computed tomography (CBCT) in his research. In Indonesia, Kartika Dewi conducted research on Mongoloid race by using periapical radiography. From her study it has been known that the length of maxillary central incisors of Indonesian Mongoloid race was 22.03mm²¹. The overall variation of the WL of different populations from our study population were ranged from +0.61 to +4.41 mm. So WL of our study population was found to be less than the values found by

the other researches^{14, 20-25}.

In our study there was no significant difference in male (51.3%) and female (48.7%) proportion, where male (63.6%) were predominant in African population²⁰ and female (79.0%) were predominant in Korean population²⁴. Majority (53.9%) of our study patients were within 21-30 years of age, that was similar with the study of Sede MA. In our study 100% cases we found single root of maxillary central incisors. Similar finding was reported by Kartika Dewi²¹. Pain was the most common (94.9%) history among the study population; history of trauma was in 56.4% cases and in clinical findings, caries was the most common (56.4%). In African population trauma (61.4%) was the common indication for root canal treatment of maxillary central incisor²⁰.

As our study design and the sample size did not represent the whole community of Bangladesh, a study with larger scale which will represent our whole community, should be carried out to verify the real picture of the average tooth length of upper central incisor in our community.

Conclusion:

According to radiographic method of working length of our study population was 21.39 mm. so the average tooth length of upper central incisor was founded approximately 22 mm. WL of our study population was found to be less than the values found by the other studies population like Caucasians, African, Sinhalese, Mongolian and Korean.

Conflict of Interest: None.

Acknowledgement:

The faculties of Conservative Dentistry & Endodontic department of Dhaka Dental College & Hospital, Dhaka.

References:

1. Barbizam JV, Fariniuk LF, Marchesan MA, Pecora JD, Sousa-Neto MD. Effectiveness of manual and rotary instrumentation techniques for cleaning flattened root canals. *Journal of endodontics*. 2002 May 1;28(5):365-6. <https://doi.org/10.1097/00004770-200205000-00004> PMID:12026920
2. Kielbassa AM, Muller U, Munz I, Monting JS. Clinical evaluation of the measuring accuracy of ROOT ZX in primary teeth. *Oral Surgery, Oral Medicine, Oral Pathology, Oral Radiology, and Endodontology*. 2003 Jan 1;95(1):94-100. <https://doi.org/10.1067/moe.2003.99> PMID:12539034
3. American Association of Endodontists (AAE). Glossary of Endodontic Terms, 7th ed. Chicago, IL: American Association of Endodontists; 2003.
4. Kuttler Y. Microscopic investigation of root apices. *J Am Dent Assoc*. 1955;50:544-552. <https://doi.org/10.14219/jada.archive.1955.0099> PMID:14366934//doi.org/10.3177/jnsv.65.451

PMid:31666483

5. Dummer PM, McGinn JH, Rees DG. The position and topography of the apical canal constriction and apical foramen. *Int End J*. 1984;17:192-198.

<https://doi.org/10.1111/j.1365-2591.1984.tb00404.x>
PMid:6593303

6. Ricucci D, Langeland K. Apical limit of root canal instrumentation and obturation, part 2. A histological study. *Int Endod J*. 1998;31:394-409.

<https://doi.org/10.1046/j.1365-2591.1998.00183.x>

PMid:15551607

7. Chandra S. *Textbook of Dental and Oral Anatomy, Physiology and Occlusion*. 2nd Ed. Jypee Brothers New Delhi, India. 2007:108-122.

8. Bastone EB, Freer TJ, McNamara JR. Epidemiology of dental trauma: a review of the literature. *Australian dental journal*. 2000 Mar;45(1):2-9.

<https://doi.org/10.1111/j.1834-7819.2000.tb00234.x>

PMid:10846265

9. Al-Negrish AR. Incidence and distribution of root canal treatment in the dentition among a Jordanian sub population. *International dental journal*. 2002 Jun 1;52(3):125-9.

<https://doi.org/10.1111/j.1875-595X.2002.tb00616.x>

PMid:12090261

10. Caliřkan MK, Trkn M. Clinical investigation of traumatic injuries of permanent incisors in Izmir, Trkiye. *Dental Traumatology*. 1995 Oct;11(5):210-3. <https://doi.org/10.1111/j.1600-9657.1995.tb00490.x> PMid:8625933

11. Hamilton FA, Hill FJ, Holloway PJ. An investigation of dento-alveolar trauma and its treatment in an adolescent population. Part 1: The prevalence and incidence of injuries and the extent and adequacy of treatment received. *British dental journal*. 1997 Feb;182(3):91-5.

<https://doi.org/10.1038/sj.bdj.4809313>

PMid:9055474

12. Hoseini A, Abbaszadegan A. Endodontic treatment of a maxillary lateral incisor with two roots; A case report with 6 months follow-Up. *J. Dent. Shiraz Univ. Med. Sci*. 2014; 15(4): 204-207.

13. Sponchiado Jr EC, Ismail HA, Braga MR, De Carvalho FK, Simes CA. Maxillary central incisor with two root canals: a case report. *Journal of Endodontics*. 2006 Oct 1;32(10):1002-4.

<https://doi.org/10.1016/j.joen.2006.03.022>

PMid:16982283

14. Carrotte P. Endodontics: Part 4 Morphology of the root canal system. *British Dental Journal*. 2004 Oct;197(7):379-83.

<https://doi.org/10.1038/sj.bdj.4811711>

PMid:15475893

15. Kim E, Fallahrastegar A, Hur YY, Jung IY, Kim S, Lee SJ. Difference in root canal length between Asians and

Caucasians. *International endodontic journal*. 2005 Mar;38(3):149-51.

<https://doi.org/10.1111/j.1365-2591.2004.00881.x>

PMid:15743417

16. Wasti F, Shearer AC, Wilson NH. Root canal systems of the mandibular and maxillary first permanent molar teeth of South Asian Pakistanis. *International endodontic journal*. 2001 Jun;34(4):263-6.

<https://doi.org/10.1046/j.1365-2591.2001.00377.x>

PMid:11482136

17. Sert S, Bayirli GS. Evaluation of the root canal configurations of the mandibular and maxillary permanent teeth by gender in the Turkish population. *Journal of endodontics*. 2004;30(6):391-8. <https://doi.org/10.1097/00004770-200406000-00004>

PMid:15167464

18. Rwenyonyi CM, Kutesa AM, Muwazi LM, Buwembo W. Root and canal morphology of maxillary first and second permanent molar teeth in a Ugandan population. *International Endodontic Journal*. 2007;40(9):679-83.

<https://doi.org/10.1111/j.1365-2591.2007.01265.x>

PMid:17608678

19. Levin R, Rubin D: *Statistics for Management*, 5th Edition, Prentice-Hall International, Inc, 1991, 8:87.

20. Sede MA, Oboro-Onuora HO, Umanah AU. Endodontic working length of permanent maxillary central incisors in Nigerians. *West African journal of medicine*. 2013;32(3):186-9.

21. Kartika D, Batubara FY. Analysis of the Tooth Length of Maxillary Incisors in Indonesian Mongoloid Race Population Based on Periapical Radiography. In *International Dental Conference of Sumatera Utara 2017 (IDCSU 2017)*. 2018 Feb (pp. 66-67). Atlantis Press.

<https://doi.org/10.2991/idcsu-17.2018.18>

22. Kim E, Fallahrastegar A, Hur YY, Jung IY, Kim S, Lee SJ. Difference in root canal length between Asians and Caucasians. *International endodontic journal*. 2005;38(3):149-51. <https://doi.org/10.1111/j.1365-2591.2004.00881.x> PMid:15743417

23. Jayawardena CK, Abesundara AP, Nanayakkara DC, Chandrasekara MS. Age-related changes in crown and root length in Sri Lankan Sinhalese. *Journal of oral science*. 2009;51(4):587-92. <https://doi.org/10.2334/josnusd.51.587> PMid:20032612

24. Choi SH, Kim JS, Kim CS, Yu HS, Hwang CJ. Cone-beam computed tomography for the assessment of root-crown ratios of the maxillary and mandibular incisors in a Korean population. *The Korean journal of orthodontics*. 2017;47(1):39-49. <https://doi.org/10.4041/kjod.2017.47.1.39> PMid:28127538 PMCid:PMC5266124

25. Harris EF, Couch Jr WM. The relative sexual dimorphism of human incisor crown and root dimensions. *Dental Anthropology Journal*. 2006;19(3):87-95.

<https://doi.org/10.26575/daj.v19i3.127>