

## Aesthetic Management of an Unerupted Maxillary Central Incisor with a Closed Eruption Surgical Technique: A Case Report

Md. Kamrul Hasan\*<sup>1</sup>, Rokeya Rahman Tani<sup>2</sup>, Mohsin Munir Khan Nabil<sup>3</sup>, Samira Rahman<sup>4</sup>

### Abstract

**Introduction:** Treatment of impacted teeth requires a combination of orthodontics and surgery. **Case report:** Reported case is of a 12-year-old-girl with an unerupted maxillary central incisor obstructed by an odontome. **Discussion:** Surgical exposure was done and traction with closed eruption technique was used. **Result:** The tooth was aligned in the dental arch with accepted aesthetic and functional satisfaction of the patient.

**Keywords:** Impacted tooth, surgical exposure, fixed orthodontics.

Number of Figures: 06; Number of References: 16; Number of Correspondences: 03.

### \*1. Corresponding Author:

**Dr. Md. Kamrul Hasan**

BDS, FCPS- Orthodontics, FICD, FWFO.

Associate Professor of Orthodontics and Dental Unit Head  
Chattagram Maa O Shishu Hospital Medical College  
Chattagram, Bangladesh.

E – mail : [dr.kamrul\\_cmc@yahoo.com](mailto:dr.kamrul_cmc@yahoo.com)

Mobile – 01712513431

### 2. Dr. Rokeya Rahman Tani

BDS, MCPS, FCPS- Orthodontics

Bangladesh.

### 3. Dr. Mohsin Munir Khan Nabil

BDS, MCPS, FCPS part II Trainee of OMFS  
Bangladesh.

### 4. Dr. Samira Rahman

MBBS, CMU, DMU, Sonologist

Qrex Diagnostic and Consultation Center Pvt. Ltd.  
Bangladesh.

### Introduction

Missing or unerupted maxillary incisors were considered to be the most unattractive deviant occlusal trait in one American study and it can have a major impact on dental and facial aesthetics<sup>1</sup>. So this may have an effect on self-esteem and general social interaction and it is important to detect and manage the problem as early as possible<sup>2</sup>. The frequency of maxillary central incisor impaction has been found in the range of 0.03–1.96 %<sup>3</sup>. The patient of current case report was treated by surgical exposure of upper right central incisor and immediately (standard edgewise fixed Appliance/ bondable button) was fitted and then orthodontically brought into the dental arch with proper alignment.

### Case Report:

A 12 year-old girl came for treatment with the complain of failure of eruption of a front tooth in

her upper jaw as her chief complaint. On clinical examination- The maxillary right central incisor is missing from the arch, Anterior cross bite presented with reverse over jet & over bite about 2 mm, Upper midline to facial midline was shifted off to the right side by 1.5 mm. which is not coincident with lower midline. Otherwise all the intraoral & extraoral findings were normal. On the assessment of dental panoramic view, Occlusal view & periapical view, reported missing incisor was present within the alveolus and it is obstructed by presence of a calcified odontome like structure on its path of eruption. Rest of the cephalometric parameters were within normal range.

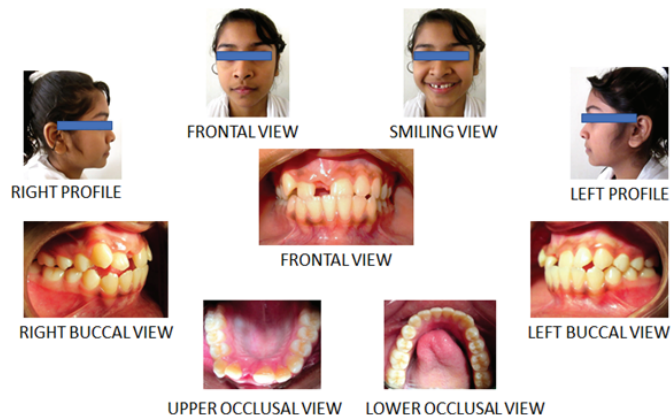
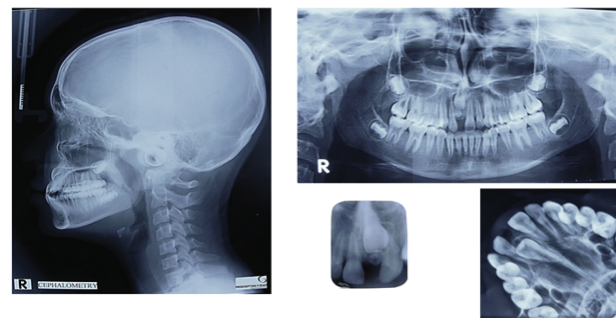


Figure -1 : Initial Extraoral & Intraoral Photographs



Initial DPT, Occlusal view, IOP, Cephalometry

Figure -2 : Radiological images of patient

This is a case of Class-I malocclusion with Anterior cross bite and Impacted maxillary right central incisor and there is buccally placed maxillary right canine. Where Molar Relation is Class- I, Canine Relation is Class- I and Incisor Relation is Class- III. Our Treatment objective for this case is firstly Levelling and alignment of upper and lower arch, welcome preparation. Secondly Surgical exposure of the maxillary right central incisor with removal of the odontome. Then Attachment to the exposed incisor & orthodontic traction then align it to normal occlusion. And finally, Reassessment of the case and regular follow-up. This patient was treated in following four phases:

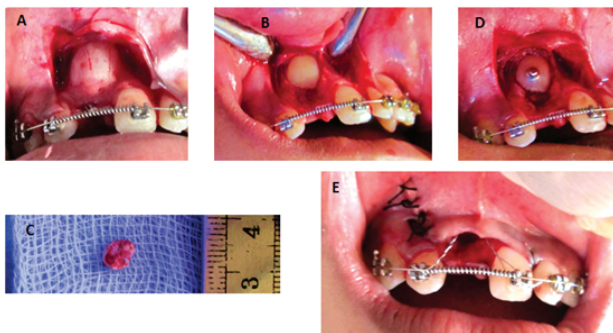
1. Levelling and alignment,
2. Surgical exposure,
3. Attachment to the tooth and
4. Orthodontic mechanics to bring the tooth into the arch.

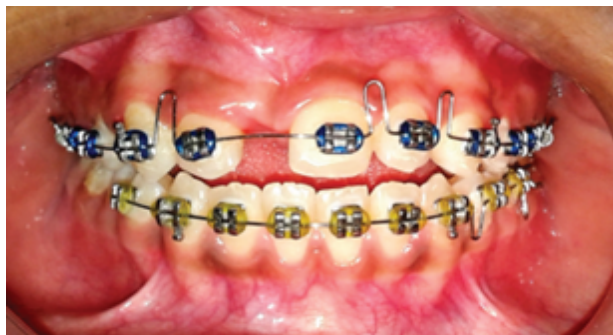

Figure – 3: Initial Alignment & Leveling done

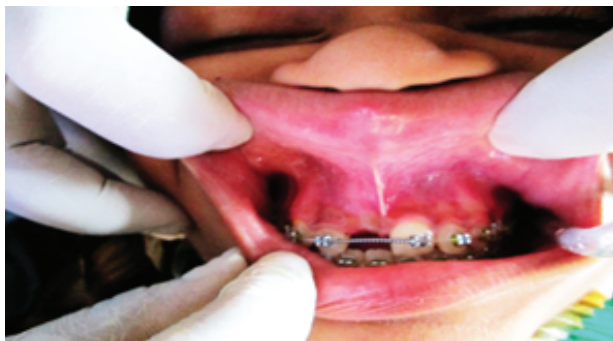

Figure – 4 :Space gained by Open coil spring



Surgical exposure of upper rt. central by triangular envelop flap(A,B), Excised odontome(C), Bonded button(D), Closure was done by 3/0 black silk(E)

Figure – 5 : Steps of surgical procedure

One year after the initial treatment, the patient was consulted again with pre-treatment and post-treatment records. A class-I incisor relation was achieved with optimal over-bite and over-jet relationship. The post treatment panoramic radiography revealed a complete eruption of upper right central incisor. The roots of the tooth were fairly parallel, supporting tissues appeared healthy both clinically and radiologically.

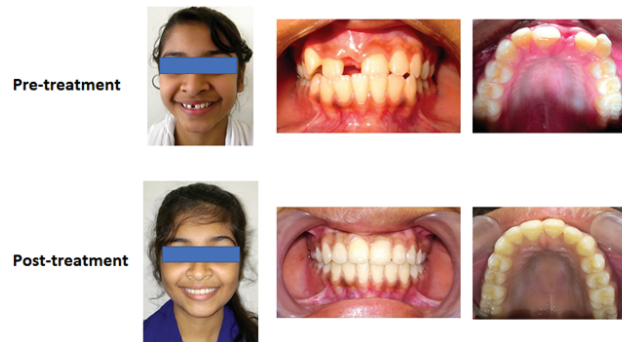

Figure – 6 : Extra oral and Intra Oral View of patient – Before and After treatment

**Discussion:**

The incidence of unerupted maxillary central incisor has been reported as 0.13% in the 5–12 year-old age group<sup>5</sup>. In a referred population to regional hospitals the prevalence has been estimated as 2.6%<sup>6</sup>. Unerupted maxillary incisors can be associated with hereditary and environmental factors. However, the relevant importance of these different factors is unknown. For example, the presence of supernumerary teeth does not necessarily mean that the incisor will be prevented from eruption<sup>7</sup>. Often the position of the impacted incisor (ie distance from alveolar crest, rotation, angulation and inclination) determines the surgical procedure used. One study of 30 patients suggested that the closed technique resulted in a more aesthetically pleasing gingiva than the apically repositioned flap. However, there was no significant difference between the techniques regarding periodontal attachment. In contrast, superior results have been reported in terms of gingival, periodontal and pulp status using the closed eruption technique in comparison with the apically repositioned flap<sup>8</sup>. The timing of intervention has been suggested as being important, with several studies suggesting that the younger the age, the quicker the tooth erupts<sup>9</sup>. However, other studies have suggested that age of intervention has no effect. To some extent the differences can be explained by the small mean time difference of about three months in eruption, inadequate sample sizes and unmatched age groups. We first determined whether the impacted tooth could be successfully aligned in its proper position on the basis of its position and orientation, the amount of root formation, and the degree of root dilaceration<sup>10</sup>. It is important to plan when and how the impacted tooth will be moved to its proper position, as well as the positions of adjacent teeth and the intermaxillary relationships. In this patient, there was insufficient space for the maxillary right canine; the lateral incisors had drifted into the unoccupied space, and the right molar had moved mesially. Extraction of the first premolar and the

deciduous canine made the orthodontic correction easier by eliminating the possibility of other complications. This is in accordance with the studies of Jacobs<sup>11</sup> and Stivaros and Mandall,<sup>12</sup> who showed that preventing or intercepting a palatally displaced canine by extracting the deciduous canine is best carried out as early as the displacement is detected, typically around 10 years of age. Usually, prevention or interception will prevent the impaction of a palatally displaced canine and might help to prevent resorption of the adjacent incisor root. Movement of an impacted central incisor could be impossible because of ankylosis and external root resorption<sup>13,14</sup>. Furthermore, even successfully treated patients can have irregular root formation<sup>11</sup> or an unesthetic gingival margin after alignment<sup>9</sup>. However, these complications did not occur in this patient. Although the closed-eruption technique usually provides the most esthetically pleasing result, we did not use this surgical technique<sup>15,16</sup>. The horizontal position of the impacted maxillary central incisor meant that direct removal of the oral mucosa was the only way to expose the tooth and attach the wire. This procedure, although more direct, has the disadvantage of producing a nonkeratinized vestibular gingival margin<sup>9</sup>. This was corrected with an apically positioned flap during the traction to provide adequate width of the attached gingiva and result in a more esthetic gingival margin. Because of the relatively high prevalence of gingival defects in some studies, adjunctive postorthodontic periodontal surgery might be required in many patients treated with this method to achieve an esthetic gingival margin contour over the central incisors and provide the teeth with an adequate zone of attached gingiva<sup>16</sup>.

#### Conclusion:

Unerupted maxillary incisors should be identified early and managed accordingly based on a comprehensive clinical examination and radiographic investigation. Depending on the position and prognosis of the tooth, appropriate treatment plan with multidisciplinary involvement should be carried out. Successful treatment outcome depends on early detection and multidisciplinary approach.

**Conflict of Interest:** None.

#### References:

1. Cons NC, Jenny J, Kohout FJ. DAI: the dental aesthetic index. Iowa: College of Dentistry, University of Iowa; 1986.
2. Shaw WC, O'Brien KD, Richmond S, Brook P. Quality control in orthodontics: risk/benefit considerations. *Br Dent J.* 1991; 170: 33-37.  
<https://doi.org/10.1038/sj.bdj.4807399>  
PMid:2001299
3. Mead SV. Incidence of impacted teeth. *Int Orthod.* 1930; 16:885-90.  
[https://doi.org/10.1016/S0099-6963\(30\)90010-5](https://doi.org/10.1016/S0099-6963(30)90010-5)
4. Rita SN, Sadat SMA, Hossain MZ. Surgical Exposure of Impacted Upper Right central Incisor and Its proper alignment in the Dental Arch. *Bangladesh Journal of Orthodontics and Dentofacial Orthopedics (BJO & DFO).* Vol. 1, No. 2, April.  
<https://doi.org/10.3329/bjodfo.v1i2.15986>
5. Mac Phee CG. The incidence of erupted supernumerary teeth in consecutive series of 4000 school children. *Br Dent J.* 1935; 58: 59-60.
6. Di Biase DD. Midline supernumeries and eruption of maxillary central incisors. *Transactions of the BSSO.* 1968-1969; 83-88.
7. Stafne EC. Supernumerary upper central incisors. *Dental Cosmos.* 1931; 73: 976-80.
8. Vermette ME, Kokich VG, Kennedy DB. Uncovering labially impacted teeth: apically positioned flap and closed-eruption techniques. *Angle Orthod.* 1995; 65: 23-32.
9. Brin I, Zilberman Y, Azaz B. The unerupted maxillary central incisor: review of its etiology and treatment. *ASDC J Dent Child.* 1982; 49: 352-56.
10. Tanaka E, Hasegawa T, Hanaoka K, Yoneno K, Matsumoto E, Dalla-Bona D, et al. Severe crowding and a dilacerated maxillary central incisor in an adolescent. *Angle Orthod.* 2006;76: 510-8.
11. Jacobs SG. The impacted maxillary canine. Further observations on aetiology, radiographic localization, prevention/interception of impaction, and when to suspect impaction. *Aust Dent J.* 1996; 41:310-6.  
<https://doi.org/10.1111/j.1834-7819.1996.tb03139.x>  
PMid:8961604
12. Stivaros N, Mandall NA. Radiographic factors affecting the management of impacted upper permanent canines. *J Orthod.* 2000; 27: 169-73.  
<https://doi.org/10.1093/ortho/27.2.169>  
PMid:10867073
13. Brand A, Akhavan M, Tong H, Kook YA, Zernik JH. Orthodontic, genetic, and periodontal considerations in the treatment of impacted maxillary central incisors: a study of twins. *Am J Orthod Dentofacial Orthop.* 2000; 117:68-74.  
[https://doi.org/10.1016/S0889-5406\(00\)70250-2](https://doi.org/10.1016/S0889-5406(00)70250-2)  
PMid:10629522
14. Brand A, Akhavan M, Tong H, Kook YA, Zernik JH. Orthodontic, genetic, and periodontal considerations in the treatment of impacted maxillary central incisors: a study of twins. *Am J Orthod Dentofacial Orthop.* 2000; 117:68-74.  
[https://doi.org/10.1016/S0889-5406\(00\)70250-2](https://doi.org/10.1016/S0889-5406(00)70250-2)  
PMid:10629522
15. Becker A, Brin I, Ben-Bassat Y, Zilberman Y, Chaushu S. Closed-eruption surgical technique for impacted maxillary incisors: a postorthodontic periodontal evaluation. *Am J Orthod Dentofacial Orthop.* 2002; 122:9-14.  
<https://doi.org/10.1067/mod.2002.124998>  
PMid:12142887
16. Becker A. Early treatment for impacted maxillary incisors. *Am J Orthod Dentofacial Orthop.* 2002; 121:586-7.  
<https://doi.org/10.1067/mod.2002.124171>  
PMid:12080308