

Classic Swenson abdomino perineal pull through in the treatment of Hirschsprung's Disease – 3 years experience in a tertiary care Paediatric Hospital in Bangladesh

K Mahmud¹, A R Khan², B H N Yasmeen³, M K Islam⁴, S Karim⁵

Abstract

Background : Hirschsprung disease (HD) is a common cause of intestinal obstruction. Definitive treatment is to excise aganglionic segment and anastomosis with anal remnant.

Objective : The aim of the study was to analyze the short term outcome of children who have undergone the Classic Swenson abdominoperineal pull through operation in the treatment of Hirschsprung's disease.

Methods : This Prospective study had been carried out in the department of paediatric surgery, Dhaka Shishu (Children) Hospital during the period of January 2013 to January 2016. Total 50 patients with Hirschsprung's disease with or without colostomy except total colonic aganglionosis were included in this study. We also excluded those patients with major co-morbidities and patients who did not agree to close stoma within 12 weeks of pull through. Consideration was given to postoperative complications (Cuff /anastomotic/pelvic abscess, wound infection, anastomotic leakage, fecal incontinence, urinary incontinence, mortality), operation time and post operative hospital stay and as well as the short term outcome.

Result : Among the study population 36 (72%) were male and 10 (28%) were female with a male female ratio of 2.5:1. Mean age at presentation was 17.96 ± 12.05 months. Thirty eight patients had diverting colostomy and underwent staged procedure. On the other hand 12 patients had no colostomy and underwent single stage procedure. Four patients developed anastomotic abscess, 3 patients developed urinary incontinence, 4 fecal incontinence and 2 patients developed post operative intestinal obstruction. The mean Operation time was 114.14 ± 13.02 minutes and mean hospital stay was 6.18 ± 1.83 days. Thirty seven patients were discharged without any complications.

Conclusion : The Classic Swenson's procedure is an effective procedure in the treatment of HD.

Key words : Hirschsprung disease, Classic Swenson pull through.

Northern International Medical College Journal Vol. 8 No. 01 July 2016, Page 185-188

¹ Dr. Khalid Mahmud
Medical Officer
Dept. of Paediatric Surgery
Dhaka Shishu (Children) Hospital

² Prof. A R Khan
Professor & Head
Dept. of Paediatric Surgery
Dhaka Shishu (Children) Hospital
& Bangladesh Institute
of Child Health (BICH)

³ Prof. Dr. B H Nazma Yasmeen
Professor & Head
Dept. of Pediatrics
Northern International Medical
College, Dhaka

⁴ Prof. M K Islam
Professor & Head
Dept. of neonatal surgery
Dhaka Shishu (Children) Hospital
& BICH

⁵ Dr. Sabbir Karim
Registrar
Dept. of Paediatric Surgery
Dhaka Shishu (Children) Hospital

Correspondence
Dr. Khalid Mahmud
Medical Officer
Dept. of Paediatric Surgery
Dhaka Shishu (Children) Hospital
E-mail: drmahmud@yahoo.com

Introduction

Hirschsprung's disease is one of the most common surgical diseases in paediatrics with an incidence of approximately 1 in 5000 live births characterized by the absence of ganglion cells in the myenteric and submucosal nerve plexuses of the distal intestine.¹⁻³ Because these cells are responsible for normal peristalsis, patients with Hirschsprung disease present with functional intestinal obstruction at the level of aganglionosis. The absence of ganglion cells or aganglionosis starts at the distal bowel beginning at the internal anal sphincter and extending proximally for various lengths (in 5% to 10% of cases can involve the entire colon or even a significant amount of the small intestine).^{4,5} The initial attempt to cure the disease were a diverting colostomy suggested by various authors.⁴ The procedure relieved the symptoms

but recurred after closure of colostomy.

Swenson pull through was the historic breakthrough in the understanding of pathogenesis and treatment of HD. The procedure, soon became popular as Swenson's procedure, brought a realistic hope that children with HD can be cured.⁶ Barium enema may help in diagnosis but transition zone may not be obvious within 3 months of age.⁷ Rectal biopsy remains the gold standard in confirming the HD. The first successful treatment of HD was undertaken over sixty years ago by Over Swenson.⁸

Since then the operative management of HD has evolved dramatically, from an endorectal dissection (soave),⁹ a retrorectal pouch procedure (duhamel)¹⁰ and a low anterior resection (Rehbein),¹¹ to more recently a primary

repair^{12,13} that can be done transanally^{14,15} and using laparoscopic technique¹⁶ to full thickness rectosigmoid dissection (swenson).¹⁷ On this background different procedures are being practiced in Bangladesh. In our institution we demonstrated our experience with Classic Swenson pull through dissection for the treatment of HD over a period of 3 years.

Materials and Methods

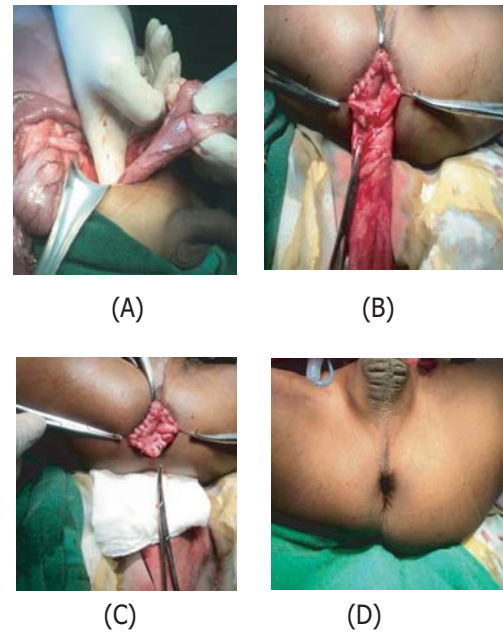
The prospective study was conducted in the department of paediatric Surgery, Dhaka Shishu (Children) Hospital during the period of January 2013 to January 2016 after getting ethical permission from ethical committee of Bangladesh Institute of Child health (BICH). Total 50 diagnosed HD patients with or without colostomy except total colonic aganglionosis and agreed to close colostomy within 12 weeks of pull through operation were included. We also excluded those patients who had major comorbidities (e.g. major Congenital Heart Disease, multiple congenital anomalies etc.) and were not interested to include in the study. All 50 patients of diagnosed HD were operated by Classic Swenson abdominoperineal pullthrough technique.

After getting written consent from parents, all data were collected from preformed questionnaire. Data included relevant history, clinical features of the patients, results of contrast enema demonstrating transition zone, histopathology report of rectal biopsy, operative findings, post operative management and follow up at 2nd, 4th, 8th and 12th weeks following operations to see the wound infection, fecal incontinence, urinary incontinence, anastomotic abscess/cuff abscess/ pelvic absces. Data of operation time and post operative hospital stay were also collected. All Collected data were compiled and arranged in a systematic manner.

Operative Technique

Mechanical bowel preparations along with rectal irrigations are recommended. Prior to Operation. A total body preparation from the nipples to the toes and urinary catheterization is performed.

The operation was originally done through a laparotomy, with the anastomosis being performed from a perineal approach after eversion of the aganglionic rectum. Coloanal anastomosis was done 1cm proximal to dentate line(picture:1B).Dissection continued up to the tip of the coccyx (picture:1A). Then the dissected aganglionic gut was pulled through the anus in everted fashion. Last of all the healthy ganglionic gut was pulled through the aganglionic gut keeping a seromuscular cuff measuring 1 cm anteriorly and 0.5 cm posteriorly(picture:1C)



Picture 1 :

Showing steps of classic abdominoperineal Swenson Pull through. (A) Identification of normal colon with mobilization. (B) Colo anal anastomosis. (C) Anastomosis complete. (D) Reposition of anastomosis.

Results

After employing inclusion criteria 50 patients were enrolled, with age at the time of operation ranging from 1day to 96 months with mean was 17.96±12.05 months. There were 36 male (72%) and 14 (28 %) female patients and a male female ratio of 2.5:1. Age and sex distribution has shown in Table I.

Table-1 : Age and sex distribution among study population (n=50)

Age	
Range	1 day- 96 months
Mean±SD	17.96±12.05 month
Sex	
Male	36(72%)
Female	14(28%)
M:F Ratio	2.5:1

The clinical presentations were shown in Table-2. Chronic constipation and abdominal distention were common. History of delayed passes of meconium was present in 38 (78%) patients. All patients had features of intestinal obstruction on plain abdominal radiograph. Contrast enema was performed in all patients and demonstrated transition zone.

Thirty (60%) patients had colostomy prior pull through operation. Twenty five (83%) were sited in right transeverse colon and remaining 5 (17%) were sited in sigmoid colon. Eighteen (60%) had diverting colostomy and remaining 12 (40%) had loop costomy.

Table-II : History and Clinical Presentation in children with HD

Clinical features	Frequency(%)
Delayed passes of meconium	38(78%)
Chronic constipation	32(64%)
Abdominal distention	34(68%)
Vomiting	8(16%)
Enterocolitis	5(10%)
Failure to thrive	2 (4%)
Fecoloma	4 (8%)

The definitive Swenson procedure was done at median age of 8 months with a range of 42 weeks to 96 months. Twenty(40%) patients had primary pullthrough without colostomy. About 93% of the patients had their transition zone restricted to rectosigmoid area. (Table-III)

Table III : Level of transition zone determined by contrast enema

Site of transition zone	Frequency(%)
Rectosigmoid	40(80%)
Descending colon	6(12%)
Transverse colon	2(4%)
Splenic flexure	1(2%)

The mean operation time from incision to dressing was 115.16±16.17minutes the mean hospital stay was 7.15 ± 1.85days.(Table- IV)

Table-IV: Total time of operation and hospital stay of the study population

Features	Classic Swenson abdomino perineal pullthrough
Operation Time (min)	
Mean±SD	115.16±16.17
Range	90-135
Hospital Stay (day)	
Mean±SD	7.15±2.86
Range	7-21

Postoperative complications were evaluated immediately and on 2nd, 4th, 8th and 12th weeks following operations to see short term outcome of children who have undergone the Classic swensonabdominoperineal pull through operation in the treatment of Hirschsprung’s disease. Five patients needed perioperative blood transfusion. Two patients developed anastomotic abscess and resolved by antibiotic therapy and drainage, 2 patients developed pelvic abscess which needed laparoscopic drainage, 1 patient developed faecal incontinence and no patient developed urinary complications. One patient who had primary pullthrough needed re-do pull through due to residual aganglionosis. Only one patient developed post operative intestinal obstruction due to bands and adhesion which resolved after conservative management. One patient died after multiple procedures, most probably due to sepsis as per clinical and biochemical evidences. He had post operative anastomotic leakage. Total 35 patients (70%) had good surgical outcome (Fig.-2)

In 42(96%) patients, there were continence to flatus and

faeces. Frequency varied from once to six times daily. Two(4%) cases were occasional soiling which improved over time and one (2%) patient developed night time incontinence.

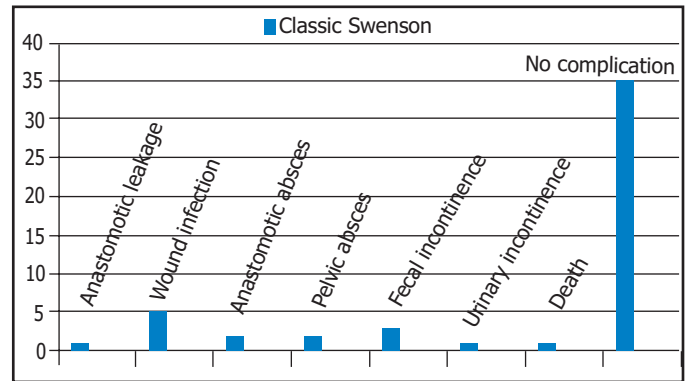


Fig.I : Total outcome of the study

Discussion

Hirschsprung’s disease was originally uncovered by Dr. Over Swenson and the original operative procedure, described by Dr. Swenson and Bill in 1948.² and since then different techniques were adopted to treat Hirschsprung’s disease.⁵⁻¹¹ This study evaluated the short term outcome of Swenson procedure for the treatment of HD in Dhaka Shishu (children) Hospital in Bangladesh. Currently transanal procedure is preferred to classical Swenson as transanal procedure is associated with less morbidity. Swenson procedure is still preferred technique in our hospital.

In this study male was predominant than female. The male female ratio was 3:1 which was very close to another study.¹

Regarding operation time, the mean operation time in this study was 68.46± 29.03 minutes which was more or less similar to the study done by Leily M et al. where the mean operation time was 134.3±51.4 minutes.²⁴

Postoperative hospital stay was ranges from 4 to 6 days and mean was 5.04±.43 days. In the study 1 patient was discharged on request on 4th POD that makes the range 4 to 6 days. After removal of the catheter on 3rd POD, patients who developed retention, burning micturation and fever was kept admitted for more days. Moreover less wound infection and less urinary complications lessen postoperative hospital stay in the study population.

In this study at follow up on 12th week we found 35(70%) patients had good postoperative outcome i, these patients were without complications. In the study of Sowande OA et al 2011, postoperative good outcome was in 76% which was also similar to our study.² Normal urinary and faecal continence is the primary goal which led to different modification of this procedure. Urinary continence is satisfactory in most patients in this series. The incidence may vary from 1% to as high as 37.7%.¹⁹⁻²⁰ In this study only 3 patients complained of soiling

after surgery and 1 patient developed urinary incontinence. Though incontinence can not be judged beyond 3 years of age. In this study patients having urinary dribbling even after last follow up (at 12 weeks) were noted as incontinence. Probably the pelvic dissection leads to injury to the nerve plexus around the bladder and causes incontinence.²¹⁻²² In our study, we noticed 4 patients had urinary dribbling after catheter removal, but in subsequent follow up on 8th week urinary dribbling of 3 patients resolved and 1 persisted up to 12th week. In the study of Zhang SC et al.²³ showed 3.1% patients developed urinary incontinence, but he judged it after a long follow up more than 3 years. So we have to follow up more to conclude finally about urinary incontinence.

In our study 2 patients developed anastomotic abscess and 2 patients developed pelvic abscess. We performed 2 stage operations by exteriorising the labelling colostomy for that 4 patients who developed anastomotic abscess and pelvic abscess. Moreover mean age of the patients who developed abscess was 24.75 months. In these patients per operatively we found sign of inadequate decompression of ganglionic segment. Probably these things played role in more abscess formation.²³ In the study of Fonkalsrud E.W et.al these complication occur in 10.52% which was higher than our study.²²

The operative mortality associated with Swenson pull through is low in many series and ranges from 0-2.5%. In this study mortality rate is 2% which is within range of other studies.²⁴⁻²⁵

Conclusion

In conclusion, our short term results are quite promising. Classic Swenson procedure is a feasible for short segment as well as long segment HD though it has some complications still it has some role in the management of HD in children especially in our setup.

References

1. Jacob CL. Hirschsprung disease. in : JA O'Neil, MI Rowe, JA Grossfield, EW Fankalsrud, AG Coran, editors. *Pediatric Surgery*, 7th edn, Missouri: Mosby year book, 2004;2: 1870-95
2. Sowande OA, Adejuyigbe O. Ten years experience with the Swenson procedure in Nigerian children with Hirschsprung's disease. *African journal of paediatric surgery*.2011;8(1):44-48
3. Badner JA, Sieber WK, Garver KL, Chakravarti A. A genetic study of hirschsprung's disease. *Am J Hum Genet* 1990;46:568-80
4. Swenson O., Bill AH. Resection of rectum and rectosigmoid with preservation of the sphincter for benign spastic lesions producing megacolon: An experimental study. *J Surg*1996; 24: 212-20.

5. Stewart DR, Von Allmen D, The genetics of Hirschsprung's disease. *Gastroenterol Clin North Am* 2003;32:819-37
6. Skaba R. Historic milestones of Hirschsprung's disease (commemorating the 90th anniversary of Professor Harald Hirschsprung's death). *J Pediatr Surg*; 2007;42: 249-51.
7. Swenson O. Partial internal sphincterotomy in the treatment. *Ann surg*1964;160:540-50
8. Swenson O., Bill AH. Resection of rectum and rectosigmoid with preservation of the sphincter for benign spastic lesions producing megacolon: An experimental study. *J Surg*; 1948; 24: 212-20
9. Soave F. A new operation for the treatment of Hirschsprung's disease. *J Pediatr Surgery*.1964; 56:1007-14
10. Duhamel. B. A new operation for the treatment of Hirschsprung's disease. *Arch Dis Child*; 1960; 35:38-39.
11. Rehbein F, Von Zimmermann H. Results with abdominal resection in Hirschsprung's disease. *Arch Dis Child*.1960; 35:29-37
12. So HB, Schwartz DL, Becker JM, et al. Endo rectal pull through without preliminary colostomy in neonates with Hirschsprung's disease. *J pediatr surg* 1980; 15:470-71
13. Teitelbaum DH, Coran AG, Primary pull through for hirschsprung's disease. *Semin Neonatol*2003; 8:233-41
14. Latorre-Mondrago NL, Ortega-Saldrago JA. Transanal endorectal pullthrough for Hirschsprung's disease. *J pediatr surg*1998; 33:1283-86
15. Langer JC, Minkes RK, Mazziotti MV. Transanal one-stage Soave procedure for infants with Hirschsprung disease. *J Pediatr Surg*. 1999; 34:148-52
16. Georgeson KE, Fuenfer MM, Hardin WD. Primary laparoscopic pull through for Hirschsprung's disease in infant and children. *J padiatrsurg* 1995; 30:1017-22
17. Levitt M A, Miller C, Hamrick B E, Andrea B, Jennifer H, Peña A. Transanal full-thickness, Swenson-like approach for Hirschsprung disease. *Journal of Pediatric Surgery*2013;48: 2289-95
18. Leily M., Ahmed KT, Mohsen R, Ali RM, Naser S, Javed G, Fathollah R, Alireza M, & Zahra G. Comparison between Swenson and Soave pull through in Hirschsprung disease. *Ann colorectal Res*. 2015; 3(4): e 32700
19. Coran AG, Teitelbaum DH, Recent advances in the management of Hirschsprung disease. *Am J Surg*2000;180:382-87
20. Gad EL-Hak NA, El-Hemaly MM, Negm EH, El-Hanafy EA, Abdel Messeh MH, Abdel Bary HH. Functional outcome of Swenson's operation for Hirschsprung disease. *Saudi J Gastroenterol*2010;16:30-34
21. Holschneider AM, Kraeft H, Scholtissek C. Urodynamic investigation of bladder disturbances in imperforate anus and Hirschsprung's disease. *Z Kinderchir*2000;35:64-68
22. Fonkalsrud E.W. Complication of Hirschsprung's disease and allied disorders. In: Holschneider, AM., Puri, P.(eds). *Hirschsprung's disease and allied disorders*. Harwood, Singapore 2000;2:425-31
23. Zhang SC., Bai Y.Z., Wang W. Long-term outcome, colonic motility, and sphincter after Swenson's procedure for Hirschsprung's disease: a single-center 2- decade experience with 346 cases. *Amer J Surg*.2007;194: 40-4724. Sherman JO, Snyder ME, Weitzman JJ, Jona JZ, Gillis DA, O'Donnell B, et al. A 40 years multinational retrospective study of 880 Swenson procedures. *J pediatr Surg*1989;24:833-38
25. Madonna MB, Luck SR, Reynolds M, Schwarz DK, Arensman RM, Swenson procedure for the treatment of Hirschsprung's disease. *Semin Pediatr Surg* 1998;7:85-88