



Three consecutive recurrent ectopic pregnancy-A Case Report

S Akhter¹, B H N Yasmeen², C T B Choudhury³

Abstract

Ectopic pregnancy (EP) is a potentially life-threatening condition, leads to increased maternal mortality and morbidity till date. About 2% of all pregnancies are Ectopic one and recurrence rate is as high as 1 in every 10 pregnancies. Here we present a case who had a history of 2 Ectopic pregnancies – 1st one treated surgically and 2nd one by medical method. Unfortunately, 3rd pregnancy was also an Ectopic one and needed surgical management. Thus, her natural reproductive ability went down and had to go for In vitro fertilization (IVF) pregnancy and successfully got twin baby (Girl, on March, 2020).

DOI: <https://doi.org/10.3329/nimcj.v12i1.61593>

Northern International Medical College Journal Vol. 12 No. 1 July 2020, Page 511-514

Introduction

An ectopic pregnancy refers to the pregnancy in which the implantation attaches outside the normal uterine cavity.¹

About 2% of all pregnancies are Ectopic one and recurrence rate is as high as 1 in every 10 pregnancies.² Though fallopian tube is the most common area of ectopic implantation, less common (10 % of ectopic pregnancies) are ovarian, cervical, abdominal, and caesarean scar.³

Currently over 90% of ectopic pregnancies can be visualized on Transvaginal scan (TVS).⁴ Early pregnancy units (EPUs) with their access to high-resolution TVS and the rapid immunoassay of serum beta human chorionic gonadotrophin (Beta-hCG) allow early diagnosis of pregnancy location.

Etiology includes tubal damage from different reasons like inflammation, infections, and surgical interventions.⁵

Risk factors include previous tubal surgery, previous ectopic pregnancy, previous genital infections, assisted reproductive technology, smoking (the risk is increased by number of cigarettes), age (increased over 40 years), intrauterine device (IUD), Progesterone only pill, multi-parity, previous abortion (spontaneous or induced), DES exposure in utero.⁶⁻⁸

Recurrence of ectopic pregnancy in those who have had previous ectopic pregnancy reaches 10-27%^{9,10} and this rises two-fold after 2-EPs.¹¹⁻¹³ Each recurrent episode exposes the patient to acute and long-term risks to her general and reproductive health. Abnormal fallopian tube anatomy is a risk factor for many recurrences of ectopic pregnancy. It is paramount to attempt to identify those at highest risk of recurrence as well as to attempt interventions in a primary ectopic pregnancy which will mitigate subsequent risks.

Management

Management options for Recurrent Ectopic Pregnancy (REP) include options available to those with a first ectopic pregnancy-salpingostomy, salpingectomy, medical and expectant management (when patient's condition is stable) and always consider which management options for an index pregnancy may lead to a higher risk of recurrence. Because it is also very important in preventing a subsequent occurrence.

When considering management options for ectopic pregnancy with the aim of reducing the risk of REP, a well-defined standard of practice has not been delineated. As with the ectopic pregnancies in general, where the American College of Gynecologists supports either salpingostomy or salpingectomy, with REP is

¹Dr. Shirin Akhter
Associate Professor
Dhaka Central International
Medical College, Dhaka

²Prof. Dr. B H Nazma Yasmeen
Professor and Head
Dept. of Paediatrics
Northern International Medical
College, Dhaka

³Dr. Chishti Tanhar Bakht Choudhury
MS (Surgery), MCPS (Gen. Surgery)
Assistant Professor
Dept. of surgery
Northern International Medical
College, Dhaka

Correspondence
Dr. Shirin Akhter
Associate Professor
Dhaka Central International
Medical College, Dhaka
Email: shirin.anu1967@gmail.com

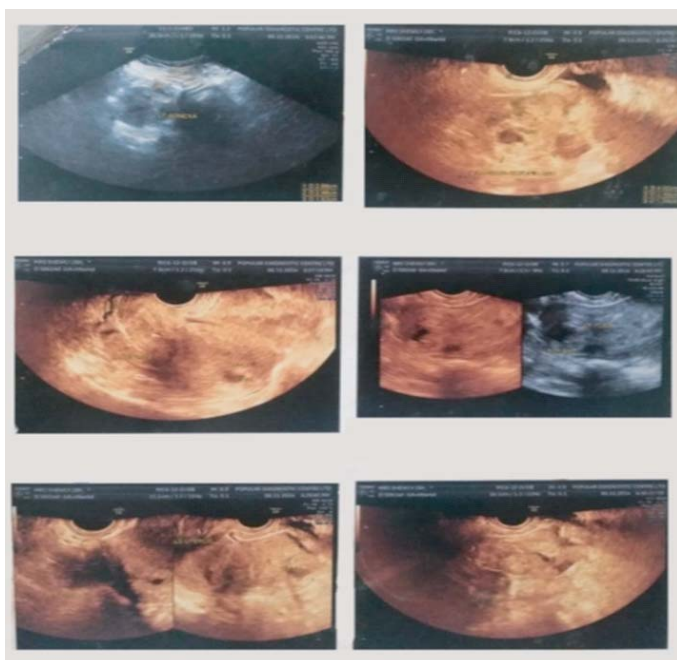
reasonable. Individual patient characteristics, risk factors of REP and clinical scenario must be assessed and considered.

Case report

A 24 years old married women with a middle class socio economic back ground hailing from Mohakhali, Dhaka got admitted in Dhaka Central Medical College Hospital. She had a history of 1st pregnancy as Ectopic pregnancy (in 2010) which was treated surgically (right sided salpingectomy) then 2nd pregnancy was also an Ectopic one (2012) while having adnexal mass with lower level of Beta hCG and when patient's condition was stable, treated conservatively with Inj.-Methotrexate (MTX) 50mg I/M-2 doses (7 days interval). Adnexal mass disappeared after 3 months, and then the tubal patency was confirmed by Day 8th of menstrual cycle with Hysterosalpingography.

Again, she tried naturally for pregnancy (4-6 months) but failed. She was also a known case of Poly Cystic Ovarian Disease. She is non-smoker. This is her second marriage. She didn't have any child in her first marital life. She didn't give any history of PID. Then she was suggested for IVF but could not avail this treatment option. Then ovulation was induced by Clomiphene Citrate for 3 cycle and got pregnant but that was also an Ectopic one (2014). At that time her investigation reports were as follows-

1. Urine for Pregnancy Test- +ve
2. S. Beta-hCG-1892mIU/ml
3. USG showed- Uterus - endometrium thickened and cavity was empty. Complex mass of about 4.0cm x 3.1cm with a sac like area within it in left adnexa. Mild collection in POD.



USG findings

Later, when patient's condition was stable having moderate lower abdominal pain, slight per vaginal bleeding. Then she was planned for conservative medical management and admitted for giving Inj.-MTX after evaluating liver function test, renal function test, CBC. Patient's condition was stable, but 3 days later suddenly she developed severe lower abdominal pain, Pulse increased, and BP was declined. Emergency laparotomy done and found left sided fallopian tube (ampulla) was ruptured and huge fresh blood was found within abdominal cavity.

Laparotomy findings

Then left sided salpingectomy done, Right Fallopian tube was absent, uterus was bulky and healthy. Histopathology of resected fallopian tube confirms ectopic pregnancy. Post operative period was uneventful.

Finally, after 5 years patient tried for IVF and successfully got twin baby (Girl, on March,2020).

Discussion

Ectopic pregnancy is a major cause of maternal morbidity and mortality, especially in developing countries where most patients tend to present late with a ruptured form and hemodynamic compromise.¹⁴ Although most patients who have a single ectopic pregnancy do not have another, the burden of recurrence is weighty. Primary prevention of ectopic pregnancies has not been successful in part because of increasing rates of Chlamydial and Gonorrheal infections each year. For successful secondary prevention identification is paramount of modifiable risk factors that predispose to recurrent ectopic pregnancy.

Notably in one study, while evidence of pelvic infection in laparoscopy for treatment of EP was associated with increased risk of REP, the findings of pelvic adhesive or tubal disease did not correlate with patient's previous diagnosis and treatment of Pelvic inflammatory disease (PID).⁹ The history of treatment of PID in this study was based on medical record review or a questionnaire response where the medical record was incomplete. In another study the findings were echoed and again no correlation of REP with a historical diagnosis or PID was noted.¹⁰

Another possible explanation is that salpingitis plays a role in the etiology of initial EP but not in that of recurrent EP.¹¹

Another study shows, patients with REP had a higher incidence of Chlamidial infection as determined by cervical antigen or serum antibody than those who achieved intrauterine pregnancies after an index ectopic pregnancy.¹⁶

Patients with recurrent EP were noted to have a significantly

increased risk of having pelvic surgery. Although an increased risk of surgery was expected as many of the women who had a previous EP were surgically managed. Type of surgery at index pregnancy where the salpingectomy or salpingostomy was not found to be correlated with recurrence.⁶ However in two other studies salpingectomy was found to be associated with a lower risk of REP than salpingostomy.^{17,18} In another case-control study salpingostomy conferred a higher risk of REP with an odds ratio of 7.129.¹⁸

A study showed that in women using only Progesterone pills or Intra Uterine Device (IUD) the chance of the pregnancy being ectopic was increased. This is because the IUD reduces intra-uterine pregnancy by 99.5% and tubal implantation by 95%.¹⁹ In a study done by Miller and Calendar²¹ it was noted that salpingectomy is a treatment of choice. Conservation and repair of tube is unwise even if it appears possible due to danger of recurrence.²¹ About 14.6% cases were presented with intact ectopic and were treated with intramuscular methotrexate injections, this proved to be very effective.²²

In Manjul's et al. study, it was found that ectopic pregnancy was more commonly found among women of low economic status(90%).²³ This might be due to not using contraception, liability to develop infection, or not seeking medical advice, as they are not capable of affording the treatment.

Conclusion

Due to various presentations of ectopic pregnancy, the physician should always be alert and consider ectopic pregnancy when a woman of reproductive age presented at the emergency room or outpatient department with a history of amenorrhea and abdominal pain.

An early and reliable diagnosis avoids the high incidence of maternal morbidity and mortality, can optimize outcome for patients and tubal integrity can be better preserved. Finally preserves the future fertility.

Acknowledgements

The authors would like to thank the patients for their consent for publication of this report.

References

- Kirk E, Bottomley C, Bourne T (2014). "Diagnosing ectopic pregnancy and current concepts in the management of pregnancy of unknown location". *Human Reproduction Update*. 20 (2): 250–61. doi:10.1093/humupd/dmt047. PMID 24101604.
- American College of Obstetricians and Gynecologists. ACOG practice bulletin: tubal ectopic pregnancy. *Obstet Gynecol*. 2018;131(3):e91–e103. [PubMed] [Google Scholar]
- D M. Panelli,¹ C H. Phillips,² and P C. Brady ,Incidence, diagnosis and management of tubal and nontubal ectopic pregnancies: a review *Fertil Res Pract*. 2015; 1: 15 Published online 2015 Oct 15 PMC5424401 PMID: 28620520 doi: 10.1186/s40738-015-0008-z
- G Condous, E Okaro, A Khalid, C Lu, S V Huffel, D Timmerman, Tom Bourne; The accuracy of transvaginal ultrasonography for the diagnosis of ectopic pregnancy prior to surgery ,The accuracy of transvaginal ultrasonography for the diagnosis of ectopic pregnancy prior to surgery; *Human Reproduction*, 2005, 20:5,1404 - 09 <https://doi.org/10.1093/humrep/deh770>
- F Kopani, A Rugia, N Manoku, Ectopic Pregnancy comparison of different treatments, *J.Prenat Med*, 2010 Apr-Jun,4(2),30-34
- Menon S, Sammel M, Vichnin M, Barnhart Barnhart, KT.: Risk Factors for Ectopic Pregnancy: A Comparison Between Adults and Adolescent Women. *J Pediatr Adolesc Gynecol*. 2007;20:181–185. [PubMed] [Google Scholar]
- Piasarska MD, Carson SA.: Incidence and risk factors for ectopic pregnancy. *Clin Obstet Gynecol*. 1999;42:2. [PubMed] [Google Scholar]
- Barnhart KT, Sammel MD, Gracia CR, et al. Risk factors for ectopic pregnancy in women with symptomatic first trimester pregnancies. *Fert Steril*. 2006;20:1. [PubMed] [Google Scholar]
- Skjeldstad MPF, Hadgu A PhD, Eriksson N MD. Epidemiology of repeat ectopic pregnancy: a population-based prospective Cohort Study. *Obstet Gynecol*. 1998;91(1):129–135. doi:10.1016/S0029-7844(97)00603-0 [PubMed] [CrossRef] [Google Scholar]
- Butts S MD, Sammel M ScD, Hummel A CCRC, Chittams J MS, Barnhart K MD, MSCE. Risk factors and clinical features of recurrent ectopic pregnancy: a case control study. *Fertil Steril*. 2003;80(6):1340–44.doi:10.1016/S0015-0282(03)02206-4[PubMed][CrossRef] [Google Scholar]
- Practice Committee of American Society for Reproductive Medicine. Medical treatment of ectopic pregnancy: A committee opinion. *Fertil Steril*. 2013;100(3):638-44. doi: 10.1016/j.fertnstert.2013.06.013. [PubMed: 23849842].
- Arleo EK, DeFilippis EM. Cornual, interstitial, and angular pregnancies: Clarifying the terms and a review of the literature. *Clin Imaging*. 2014;38(6):763-70. doi: 10.1016/j.clinimag.2014.04.002. [PubMed: 25156020].
- Gonzalez N, Tulandi T. Cesarean scar pregnancy: A systematic review. *J Minim Invasive Gynecol*. 2017;24(5):731-8. doi: 10.1016/j.jmig.2017.02.020. [PubMed: 28268103].
- O L Lawani, O B Anozie, and P O Ezeonu; Ectopic pregnancy: a life-threatening gynecological emergency *Int J Womens Health*. 2013; 5: 515–521. Published online 2013 Aug 19. doi: 10.2147/IJWH.S49672 PMCID: PMC3751381 PMID: 23983494
- Joesoef MRM, Westrom L MD, Reynolds G PhD, Marchbanks P PhD, Cates W MD, MPH. Recurrence of ectopic pregnancy: the role of salpingitis. *Am J Obstet Gynecol*. 1991;165(1):46–50. doi:10.1016/0002-9378(91)90221-C [PubMed] [CrossRef] [Google Scholar]
- Kuroda K, Takeuchi H, Kitade M, et al. Assessment of tubal disorder as a risk

- factor for repeat ectopic pregnancy after laparoscopic surgery for tubal pregnancy. J Obstet Gynaecol Res. 2009;35(3):520–24. doi:10.1111/j.1447-0756.2008.00969.x[PubMed][CrossRef] [Google Scholar]
17. Ellaithy M, Asiri M, Rateb A, Altraigey A, Abdallah K. Prediction of recurrent ectopic pregnancy: a five-year follow-up cohort study. Eur J Obstet Gynecol Reprod Biol. 2018;225:70–78. doi:10.1016/j.ejogrb.2018.04.007 [PubMed] [CrossRef] [Google Scholar]
 18. Wang X, Huang L, Yu Y, Xu S, Lai Y, Zeng W. Risk factors and clinical characteristics of recurrent ectopic pregnancy: a case-control study. J Obstet Gynaecol Res. 2020;46(7):1098–1103. doi:10.1111/jog.14253 [PMC free article] [PubMed] [CrossRef] [Google Scholar]
 19. Etuknwa BT, Azuz OO, Peter AI, Ekandem GH, Olaifa K, et al (2012) Ectopic pregnancy: A Nigerian urban experience. Korean J. Obstet Gynecol 55: 309-314.
 20. WHO Task Force (1985) A multinational case-controlled study of ectopic pregnancy. ClinReprodFertil 3: 131-134
 21. Nyong'o AO (1994) Smoking and reproductive health: cigarette smoking as risk factors in ectopic pregnancy. East Afr Med J 75: 32-34.
 22. Belquis AJ, Dikrayat H. Frequency Of Tubal Ectopic Pregnancy And Mode Of Management At Al-Thawra General Modern Hospital. Crit Care Obst Gyne. 2016, 3:1 Published Date: 2017-02-14 DOI:10.21767/2471-9803. 1000145
 23. Brian M, Claren GR (1997) An unusual presentation of bilateral tubal pregnancy. Br J Clin Pray 47: 161-162



Dr. Shirin Akhter, MBBS, FCPS, working as Associate Professor department of obstetrics and gynecology at Dhaka Central International Medical College and Hospital (DCIMCH), Dhaka, Bangladesh. Completed MBBS from Mymensingh Medical College. Worked at Holy Family Red Crescent Medical College Hospital for about 12 years. 4 Scientific Articles were published in different national medical journals.