

## Uterine Artery Pseudoaneurysm after Cesarean Section: Case Report

Afroza Parvin<sup>1</sup>, Monowara Begum<sup>2</sup>, Atiya Huda<sup>3</sup>

---

### Abstract

Uterine artery pseudoaneurysm (UAP) occurs rarely and can develop after various gynecologic or obstetric procedures. The delayed diagnosis of this disease often results in life-threatening hemorrhage. Here is described a case of UAP after cesarean section. The patient visited gynecology outpatient department of AHD 60 days after cesarean section done outside AHD because of abnormal per vaginal bleeding. After her cesarean section she had undergone laparotomy outside AHD for post partum haemorrhage but those papers were not available. From there she was sent to our radiology department for color Doppler TVS examination and here she was diagnosed as a case of UAP using color Doppler ultrasonography. The most frequent cause of UAP is cesarean section, which accounted for 47.4% of all cases. Previous studies show that the definitive diagnosis was made at angiography (41.2%), computed tomography (29.4%), or color doppler ultrasonography (29.4%). Almost all cases (94.1%) were conservatively treated with transcatheter uterine artery embolization. Consideration of UAP in the differential diagnosis is crucial for proper treatment before rupture and to preserve fertility.

### Keywords

Cesarean section, Postpartum hemorrhage, Transcatheter arterial embolization, Uterine artery pseudoaneurysm

### Introduction

A pseudoaneurysm is an extra-luminal collection of blood with turbulent flow that communicates with the parent vessel through a defect in the arterial wall. The development of an arterial pseudoaneurysm is a rare but reported complication of pelvic surgery, vascular trauma during c-section or after uterine curettage. After hematoma formation, there is central liquefaction that leaves a cavity with turbulent blood flow, as a result of persistent communication between the parent artery and the hematoma. The absence of a 3-layer arterial wall lining the pseudoaneurysm differentiates it from a true aneurysm, which is

less common than a pseudoaneurysm.<sup>1</sup>

Pseudoaneurysm of the uterine artery is an uncommon cause of delayed postpartum hemorrhage following caesarean or vaginal delivery and is potentially life threatening. Typically, the lesions are discovered because the patients have symptoms related to delayed rupture of the pseudoaneurysm, causing hemorrhage.<sup>2</sup> A pseudoaneurysm may be asymptomatic, may thrombose, or may lead to distal painful embolization. The risk of rupture is proportional to the size and intramural pressure. Diagnosis is usually based on both Doppler sonography and arteriography.<sup>3</sup>

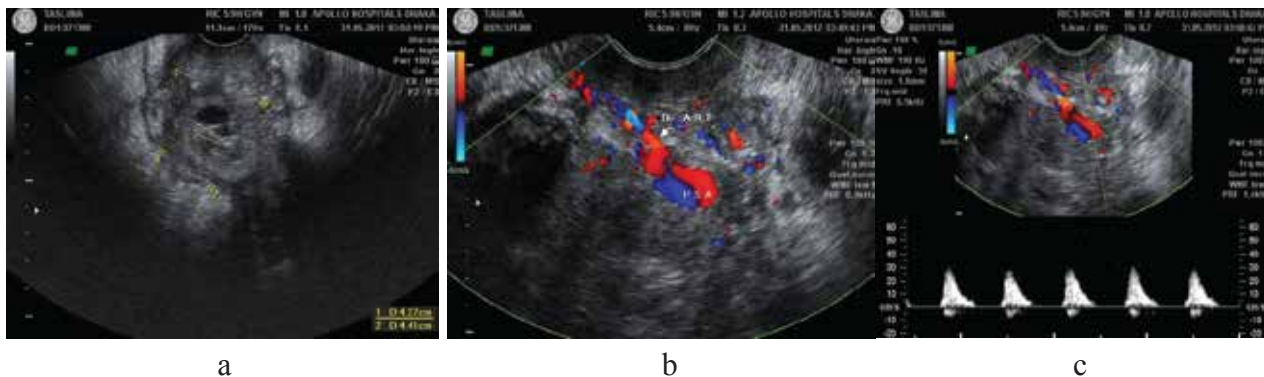
*1. Registrar, Department of Radiology & Imaging, Apollo Hospitals Dhaka 2. Sr. Consultant- Department of Obstetrics & Gynecology, Apollo Hospitals Dhaka 3. Sr. Consultant- Department of Radiology & Imaging, Apollo Hospitals Dhaka*

Transcatheter uterine artery embolization (UAE) has emerged as a highly effective technique for controlling obstetric and gynaecologic hemorrhage, including that from pseudoaneurysms.

We report a case of uterine artery pseudoaneurysm presenting with secondary postpartum hemorrhage 60 days after c-section delivery and managed successfully with coil embolization outside AHD. She came for follow up at Gynaecology OPD of AHD after one month of embolization and she was found to be doing well. A follow up TVS was done at Radiology department and her report was normal.

### Case Report

A 26-year-old, para 2 came to gynaecology department of Apollo Hospitals Dhaka 60 days post operation with symptoms of excessive bleeding per vaginum. She had undergone an elective c-section outside AHD. She was apparently asymptomatic for few days post operation. But she developed post partum haemorrhage and for that she had undergone laparotomy outside AHD but those papers were not available. Then later on she developed excessive bleeding per vaginum. On perabdominal examination, a mass was felt at lower abdomen and on pervaginal examination a mass was felt through left fornix. She was haemodynamically stable.



**Fig: (a)** Gray-scale ultrasound of the pelvis shows a hypoechoic lesion in left posterior lower uterine segment of uterus.

**Fig: (b) + (c)** Color Doppler evaluation of the uterus demonstrates a pulsatile vessel within the hypoechoic area having a donor feeding artery showing yin and yang blood flow pattern.

Transvaginal ultrasonography with color Doppler confirmed a postpartum uterus. There was no evidence of residual placental tissue in the uterine cavity and endometrial thickness was normal. A heterogeneous hypoechoic lesion measuring 53 x 40 x 44 mm [Figure a] was detected in the left posterior lower uterine segment and power Doppler revealed blood

flow within it [Figure b,c]. Color flow Doppler sonography showed yin and yang blood flow pattern within the body of pseudoaneurysm. Concentric layer of mural thrombosis was noted around it.

To preserve the fertility in this young patient, a transcatheter arterial embolization of this pseudoaneurysm was planned. For that she was

sent to another reputed hospital outside AHD where her left uterine artery was selectively embolized with mixture of gelfoam and contrast media followed by 2 stainless steel coils 4 mm in diameter. The right uterine artery was also tortuous and hypertrophied and was embolized with gel foam. Follow-up color Doppler US showed aneurysmal cavity filled with echogenic content with no evidence of blood flow, except for slight lower abdominal and back pain that was managed with analgesics.

### **Discussion**

Postpartum hemorrhage remains one of the major causes of maternal mortality. Secondary postpartum hemorrhage is defined as excessive bleeding starting any time from 24 hours after delivery up to 6 weeks postpartum and most commonly occurring between 8 and 14 days postpartum. Common causes include retained products of conception, subinvolution of the placental bed, and endometritis.<sup>4</sup> Rare causes include pseudoaneurysm of uterine artery, arteriovenous malformations, and choriocarcinoma. When the more common causes have been excluded, pelvic angiography may be performed. Uterine artery embolization can be carried out to control hemorrhage. In 1979, Brown et al. reported the first case of selective arterial embolization used successfully to treat an extrauterine pelvic hematoma after three failed surgical attempts to control the bleeding.<sup>5</sup> Since then, arterial embolization has been used successfully to control postpartum bleeding from uterine atony, placenta accreta, and vulvar and vaginal hematomas. The efficacy and safety of

selective arterial embolization of uterine arteries was evaluated by Pelage et al. in women with delayed secondary postpartum hemorrhage. In their series of 14 women, pseudoaneurysms of the uterine artery were found in 2 women.<sup>6</sup> Immediate resolution of external bleeding was observed after embolization. In this series, no complications related to this invasive treatment were found. Other authors have described complications, including muscle pain and bladder necrosis.<sup>7</sup>

A true aneurysm has all three layers of arterial wall, whereas pseudoaneurysm does not have all the three layers of arterial wall. The differential diagnosis of pseudoaneurysm includes acquired arteriovenous malformations (AVMs), arteriovenous fistulas, and direct vessel rupture. AVMs are characterized by multiple communications of varying sizes between arteries and veins, which can be congenital or acquired. Congenital uterine AVMs are due to abnormality in the embryologic development of primitive vascular structures, whereas acquired AVM's consist of multiple small arteriovenous fistulas between intramural arterial branches and the myometrial venous plexus. Acquired AVM's occur more commonly following D and C, uterine surgery, or trauma to the uterus. Color flow Doppler demonstrates to-and-fro sign in the neck of the pseudoaneurysm and yin-yang sign in the body of the pseudoaneurysm. AVM's are characterized by marked aliasing on color flow Doppler and arterialized venous flow on spectral Doppler evaluation.

In a small series of women, who underwent embolotherapy for obstetric hemorrhage, all 3

women who attempted conception after embolization were successful. Of the 3 women, 2 underwent bilateral uterine artery embolization.<sup>8</sup> Our patient developed a pseudoaneurysm after 60 days of C-section delivery. Treatment was by angiographic embolization of uterine arteries with gelfoam and embolization coils. In a series of women, Rosenthal et al. observed angiographic arterial embolization was shown to be the most useful clinical tool in the management of post-operative vaginal hemorrhage.<sup>9</sup> Angiographic embolization has the advantages of decreased morbidity, ability to localize the bleeding site and provide a more distal occlusion than surgical ligation, and preservation of future fertility compared to hysterectomy. Burchell demonstrated that bilateral internal iliac artery ligation was more effective in reducing the pulse pressure than unilateral ligation.<sup>10</sup> It is possible that the redistribution and redirection of blood or hypoxia-induced neovascularization allows bleeding to occur from the contralateral side after unilateral embolization. Inadequate embolization of a pseudoaneurysm due to extrauterine feeding arteries, such as the internal pudendal artery, ovarian artery, inferior epigastric artery, or contralateral uterine artery leading to embolization failure can occur.<sup>1</sup> Hence, bilateral uterine embolization is safe and more advantageous than unilateral embolization.

### Conclusion

We conclude that in a woman with unexplained vaginal bleeding after C-section delivery, pseudoaneurysm is a potentially life-threatening complication and should be

considered in the differential diagnosis of secondary postpartum hemorrhage. Radiology and Imaging can play a vital role in detecting pseudoaneurysms. Although data are scant, bilateral uterine artery embolization for obstetric hemorrhage appears to have no increased deleterious effect on future fertility and is more effective when compared to unilateral embolization.

### References

1. Kwon JH, Kim GS. Obstetric iatrogenic arterial injuries of the uterus: diagnosis with US and treatment with transcatheter arterial embolization. *Radiographics*. 2002;221:35-46.
2. Langer JE, Cope C. Ultrasonographic diagnosis of uterine artery pseudoaneurysm after hysterectomy. *J Ultrasound Med*. 1999;18:711-14.
3. Hidar S, Bibi M, Atallah R, Essakly K, Bouzakoura C, Hidar M. Pseudoaneurysm of the uterine artery: apropos of 1 case. *J GynecolObstetBiolReprod. (Paris)* 2000;29:621-24.
4. Khong TY, Khong TK. Delayed postpartum hemorrhage: A morphologic study of causes and their relation to other pregnancy disorders. *Obstet Gynecol*. 1993;82:17-22.
5. Brown BJ, Heaston DK, Poulson AM, Gabertet HA, Mineau DE, Miller FJ. Uncontrollable postpartum bleeding: a new approach to hemostasis through angiographic arterial embolization. *Obstet Gynecol*. 1979;54:361-65.
6. Pelage JP, Soyer P, Repiquet D, Herbreteau D, Le Dref O, Houdart E, et al. Secondary postpartum hemorrhage: treatment with selective arterial embolization. *Radiology*. 1999;212:385-89.
7. Sieber PR. Bladder necrosis secondary to pelvic artery embolization: case report and literature review. *J Urol*. 1994;151:422.
8. Stancato-Pasik A, Mitty HA, Richard HM, 3rd, Eshkar N. Obstetric embolotherapy: effect on menses and pregnancy. *Radiology*. 1997;204:791-93.
9. Rosenthal DM, Colapinto R. Angiographic arterial embolization in the management of postoperative vaginal haemorrhage. *Am J Obstet Gynecol*. 1985;151:227-31.
10. Burchell RC. Internal iliac artery ligation: hemodynamics. *Obstet Gynecol*. 1964;24:737-39.

## CME in Apollo Hospitals Dhaka from January to December-2014

S. No.	Date	Topic of CME	Speakers	Department
1	8 <sup>th</sup> January'14	Management of Septic Shock	Dr. Amit Karmakar, Associate Professor, Department of Pulmonary & Critical Care Medicine, California, North state, College of Medicine.	Pulmonary & Critical Care Medicine
2	25 <sup>th</sup> February'14	Management of Chronic Hepatitis & B virus infection	Prof. Dr. Md. Muzibur Rahman Bhuiyan, Sr. Consultant & Coordinator Dept. of Gastroenterology	Gastroenterology
3	30 <sup>th</sup> March'14	Modern Insulin -the ideal insulin for the treatment of Diabetes mellitus	Dr. Abdul Mannan Sarker, Sr. Consultant & Coordinator- Diabetology & Endocrinology	Diabetology & Endocrinology
4	12 <sup>th</sup> May'14	Advanced Devices for management of Colostomy, ICU Patients & other Surgery	Mr. Sangram Bohidar Product & Mar Comm Manager, ConvaTec, India	General & Laparoscopic surgery
5	25 <sup>th</sup> June'14	Mediastinal mass - surgical management	Dr. Nuruddin Mohammad Zahangir, Specialist, Department of Cardio Thoracic Surgery	Cardio Thoracic Surgery
6	29 <sup>th</sup> June'14	Surgery for Mitral Regurgitation	Prof. Dr. CHUA Yeow, Sr. Consultant - Cardio Thoracic Surgery, National Heart Centre, Singapore	Cardio Thoracic Surgery
7	29 <sup>th</sup> June'14	Current Management of OA Knees	Prof. Dr. Tay Boon Keng, Consultant - Department of Orthopedic Surgery	Orthopedic Surgery
8	21 <sup>st</sup> August'14	Spectrum of Interventional Radiology in Clinical Service	Dr. Jagdeep Singh Shekhawat, Consultant-Radiology	Radiology
9	30 <sup>th</sup> September'14	Complications of Diabetes Mellitus & Diabetic Emergency	Dr. Abdul Mannan Sarker Sr. Consultant & Coordinator- Diabetology & Endocrinology	Endocrinology & Diabetology
10	27 <sup>th</sup> November'14	Current Perspective of Hemato - Oncology in Bangladesh"	Dr. Abu Jafar Mohammed Saleh, Consultant-Adult Hematology & Hematopoietic Stem Cell Transplant	Adult Hematology/HSCT
11	11 <sup>th</sup> December'14	Bariatric Surgery	Dr. Sanjay Patolia Consultant and Director-Asian Bariatrics Hospital, Ahmedabad, India	General & Laparoscopic Surgery