

A Case Report on Frontal Osteoma

Molla MR¹, Ferdousi F², Shankar DR³, Karim AKMB⁴

Abstract

A 13 years old boy admitted with the complaint of progressive exophthalmos and gradually decreasing vision on right eye, also occasional headache and deformity on the right fronto-orbital region. Radiological & clinical findings revealed a case of frontal osteoma in the right frontal sinus extending up to right frontal lobe, eroding right roof of the orbit. Complete excision of the tumor mass was possible surgically. Biopsy confirmed a case of osteoma. Below is a discussion on diagnosis & management of frontal osteoma

Keywords

Osteoma, Frontal sinus, Exophthalmos, Headache.

Introduction

Osteomas are benign slow growing osseofibrous neoplasm. They are quite infrequent in the paranasal air sinuses and their occurrence in these locations has been put at 0.43% in early plain sinus radiography series and 3% in the more recent sinus computed tomography survey.^{5,6} The fronto-ethmoidal sinus is the most frequent site in the paranasal sinuses and majority of these are micro-lesions averaging about 5mm in size and hence are usually asymptomatic.^{6,7,8,9} Larger lesions, those up to 30 mm in diameter, are still more infrequent, but are more symptomatic by causing varying nasal/paranasal sinus inflammatory/infective and obstructive symptoms, and occasional intracranial/orbital complications.^{5,7,10,11,12,13,14} Surgical resection is then called for and many of these less than 30mm lesions are safely excised via sundry minimally invasive techniques including external fronto-ethmoidectomy and even endoscopic endonasal methods.^{15,16}

The second to fifth decade of life with a male to female ratio of 2:1 may attribute to the greater exposure of the male gender to trauma and to the large size of their sinuses. Also the mean growth rate is 1.61 mm/year, range of 0.44 to 6.0 mm/year.⁷ The most frequent symp-

tom of osteoma presents with epistaxis as a secondary complication.^{6,7} No chance of malignant transformation is noted.

Case Report

A 13 years old boy presented to our Dental & Maxillofacial Department of Apollo Hospitals Dhaka on 24/05/2015 with progressive exophthalmos with decrease in vision in the right eye and deformity on the right fronto-orbital region for a duration of six months. Ophthalmological examination of the patient revealed visual acuity right eye 6/60 and left eye 6/6 with limitation in upwards gaze.

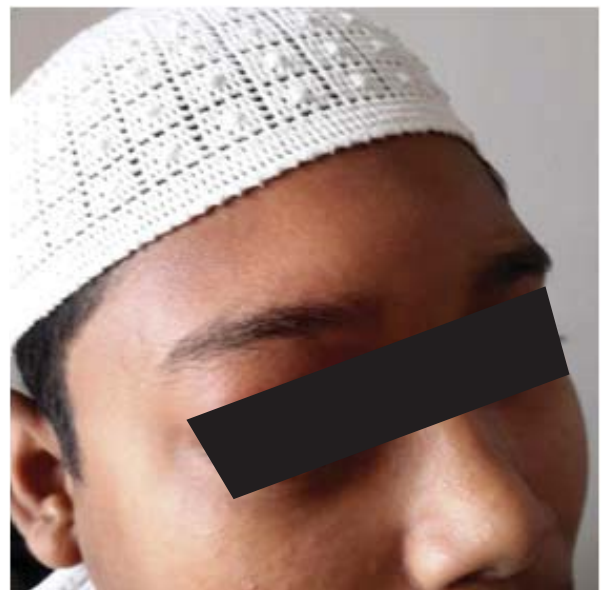

Fig.1: Preoperative view

1. Senior Consultant, Dept. of Dental & Maxillofacial Surgery, Apollo Hospitals Dhaka 2. Registrar, Maxillofacial Surgery, Dept. of Oral & Maxillofacial Surgery, Apollo Hospitals Dhaka, 3. Senior Consultant, Dept. of Neurosurgery, Apollo Hospitals Dhaka 4. Registrar, Dept. of Neurosurgery, Apollo Hospitals Dhaka

CASE REPORT

Computed tomography (CT) revealed a bony mass that probably originated from the right frontal bone and extended to the right frontal sinus, laterally to the orbital space superiorly to the frontal lobe, and medially to the frontal process of the maxilla up to the left frontal sinus. There was no involvement of optic nerve was noted in CT-scan. The patient was referred to neurosurgery for the evaluation regarding any intracranial involvement.

The bony lesion was accessed via a bicoronal

flap incision. The tumor mass was enucleated with a pneumatic drill in a single piece and sent for histopathological examination. After removal of the tumor there is a communication seen with frontal lobe, dura matter was intact which was covered with surgicel. Neurosurgery team was advised to covered the area with surgery. Posterior & floor of the orbit and anterior wall of frontal bone defect was reconstructed by titanium mesh and titanium screws. Follow up cranial CT demonstrated total removal of mass in a single piece intact.

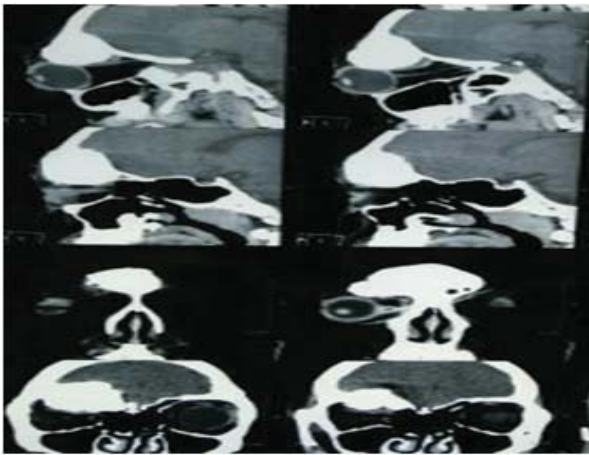


Fig. 2: Pre-operative Ct Scan

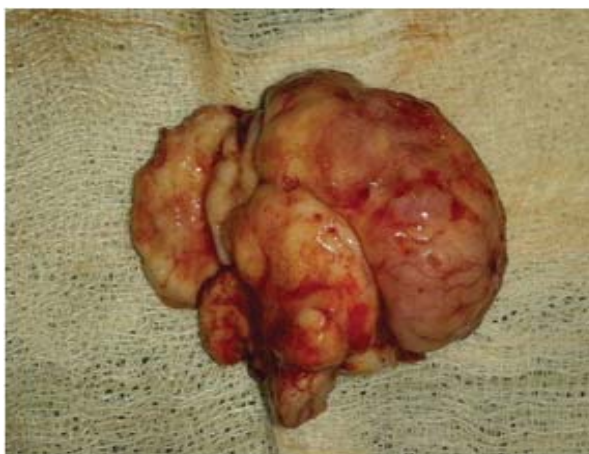
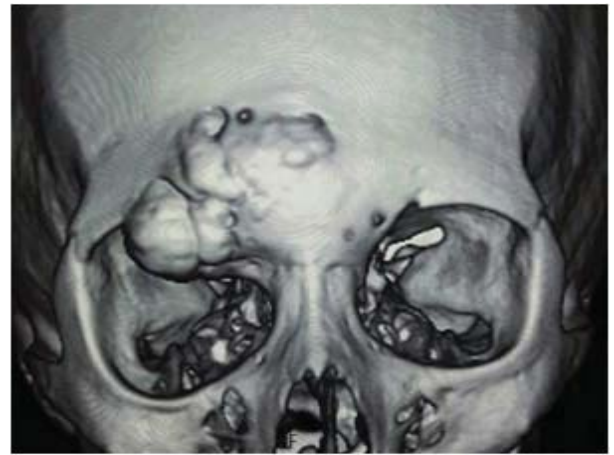
Fig. 3: Excised tumor

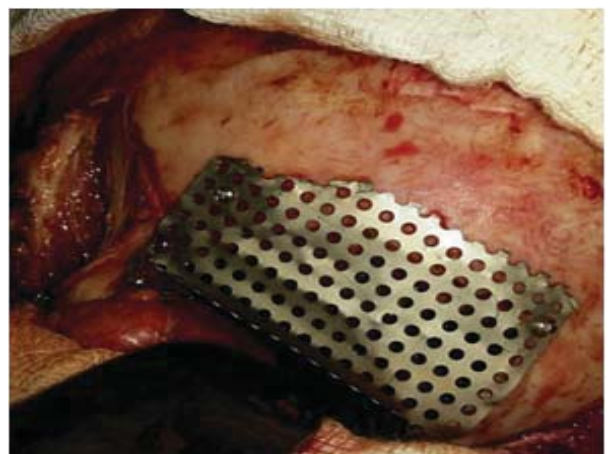


Fig. 4: Reconstruction after removal of tumor

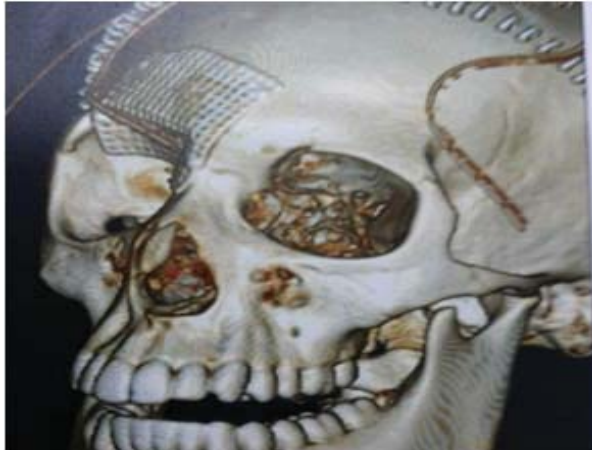

Fig. 5: Post-op CT Scan

Post-operatively on follow-up patient's proptosis and limited upward gaze improved along with right eye visual acuity (from 6/60 to 6/12). Subsequent follow up shows no complications

Discussion

Diagnosis of frontal osteoma is usually by chance, but rarely they can produce exceptional ophthalmological and neurological complications apart from cosmetic

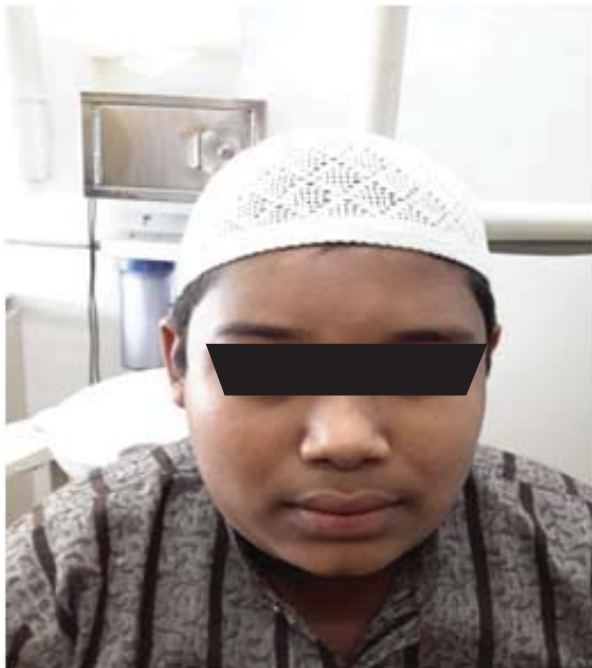

Fig. 6: After 3 months

disfigurement.¹ Etiology of frontal osteoma may be multifactorial. Surgical management should be site and size specific. Here we report a frontal osteoma of size 5*5.5*4.5 cm which is one of the largest reported in literature. The available literature and our own experience suggest that even large osteoma arising in the frontal region can be completely removed surgically with less or no complications. The surgical approach can be variable according to the extent of the of the tumor and patient's considerations for incision. A regular follow-up is necessary for any recurrence in future up to one year after surgery.

Most osteomas are diagnosed after radiological investigations that are carried out for other reasons, but rarely these can produce exceptional ophthalmological and neurological complications apart from cosmetic disfigurement. Most common presentation is headache. Sinusitis and forehead deformity are not frequent.¹ Osteomas originate from the neighboring sinus periosteum. Frequently, the outer periosteal layer separates the mass from the neighboring tissue. The exact etiology of osteoma is unknown. However, traumatic, infectious and developmental origins have been proposed. Osteomas are usually solitary lesions. The accompanying sign and symptoms depends on the size, location and growth direction of the lesion.

In our case, the medial part of the osteoma was consistent with a compact type osteoma radiologically, and the pathological investigations of the specimen confirm the diagnosis of compact osteoma. The lateral part of the lesion was consistent with the spongiose type radiologically

and again the pathological investigation of the specimen confirmed the diagnosis. As the lesion contained both components types, it is referred to as a mixed-type osteoma. Our case had a 6 months history, which was also consistent with a rapid growth of the spongiose component of the osteoma.

Complications secondary to presence of osteomas are rare. However, proptosis, diplopia, decreased visual acuity and frontal deformity may develop with orbital extension of a large osteoma originating from the frontal sinus. Open surgery should be the method of choice in larger and complicated frontal osteomas. Complete surgical excision is curative.

Conclusion

Frontal osteomas can produce exceptional neurological and ophthalmologic complications. Clinical presentation and complications are site and size specific. Even giant frontal osteomas can be safely removed by careful open surgery. A complete excision is curative. A purely endoscopic endonasal approach has the risk of incomplete excision. Post-operative CSF leak, if present, can be managed conservatively, unless too large.

References

1. Watelet JB, Cauwenberge P. Applied anatomy and physiology of the nose and paranasal sinuses. *Allergy*, 1999; 54 (Suppl 57): 14-25.
2. Selva D, White VA, O’Connell JX, Rootman J. Primary bone tumours of the orbit. *Surv Ophthalmol*. 2004; 49:328-42.
- 3 . Dispenza C, Martines R, Dispenza F, Caramanna C, Saraniti C. Frontal sinus osteoma complicated by palpebral abscess: case report. *Acta Otorhinolaryngol Ital*, 2004;

- 24:357-60.
4. Mansour AM, Salti H, Uwaydat S, Dakroub R, Bashshour Z. Ethmoid sinus osteoma presenting as epiphora and orbital cellulites: case report and literature review. *Surv Ophthalmol*, 1999; 413-26.
5. Brunori A, de Santis S, Bruni P, Delitala A, Giuffre R, Chiappetta F. Life threatening intracranial complications of frontal sinus osteomas: report of two cases. *Acta Neurochir (Wien)*, 1996. 138(12): 1426-30.
6. Earwaker J. Paranasal sinus osteomas: A review of 46 cases. *Skeleta Radiol*, 1993; 22(6): 417-23.
7. Bourdial J. Frontal sinus and ethmoidofrontal sinus osteomas. Surgical indications and treatment by controlled abrasion using a drill. *Ann Otolaryngol Chir Cervicofac*. 1972; 89(6): 285-314.
8. Brown LG. Osteoma of the Frontal Sinus. Operation for removal. *Proc R Soc Med*, 1930; 23(4): 514-5
9. Guterberg A, Larsen J, Rohde V. Frontal sinus osteomas complicated by extended intracranial mucocele and cerebral abscess: Neurosurgical strategy of a rare clinical entity. *Cen Eur Neurosurg*, 2009; 70(2): 95-7
10. Bertlett JR. Intracranial neurological complications of frontal and ethmoidal osteomas. *Br J Surg*, 1971; 58(8):607-13
11. Bourgeois P, Fichten A, Louis E, Vincent C, Pertuzon B, Assaker R. Frontal sinus osteomas : neuro-ophthalmological complications. *Neurochirurgie*.2002.48 : 104-8
12. Bushan B, Watal G, Ahmed A, Saxena R, Goswami K, Pathania AG. Giant ivory osteoma of frontal sinus. *Australas Radiol*, 1987; 31(3):306-8
13. Haddad FS, Haddad GF, Zaatari G. Cranial osteomas: Their classifications and management. Report on a giant osteoma and review of the literature. *Surg Neurol*, 1997; 48(2):143-7
14. Jurnila M, Janjanin S, Melada A, Prstacic R, Veselic AS. Large intracranial intradural mucocele as a complication of frontal sinus osteoma. *J Craniofac Surg*, 2010; 21(4): 1126-9
15. Chiu AG, Schipor I, Cohen NA, Kennedy DW, Palmer JN. Surgical decisions in the management of frontal sinus osteomas. *Am J Rhinol*, 2005; 19(2): 191-7
16. Streck P, Zagolski O, Skladzien J, Kurzynski M, Dyduch G. Osteomas of the paranasal sinuses: Surgical treatment options. *Med Sci Monit*, 2007; 13(5):CR244-50