

An Interesting Finding of ‘Hot Clot Artifact’ on 18F-FDG PET/CT scan – A Case Report

Taslima Sifat¹, Sharmin Farhana², Abu Billal³, Biva S. Khan⁴, Raihan Hussain⁵, M. F. Kabir⁶

1. Sr. Specialist,
Department of Nuclear
Medicine & Molecular Imaging,
Evercare Hospital Dhaka
2. Associate Consultant,
Department of Nuclear
Medicine & Molecular Imaging,
Evercare Hospital Dhaka
3. Medical Physicist,
Department of Nuclear Medicine &
Molecular Imaging,
Evercare Hospital Dhaka
4. Sr. Consultant,
Department of Interventional
Radiology & Imaging,
Evercare Hospital Dhaka
5. Sr. Consultant,
Department of Nuclear Medicine &
Molecular Imaging,
Evercare Hospital Dhaka
6. Sr. Consultant and Coordinator,
Department of Nuclear Medicine &
Molecular Imaging,
Evercare Hospital Dhaka

Address for Correspondence:

Dr. Taslima Sifat
Sr. Specialist,
Department of Nuclear Medicine &
Molecular Imaging,
Evercare Hospital Dhaka
taslima.sifat@evercarebd.com

ABSTRACT

18F-fluorodeoxyglucose (18F-FDG) Positron Emission Tomography/Computed Tomography (PET/CT) scan of oncological patients for the evaluation of disease status and treatment response has become a standard procedure of care. Abnormally increased 18F-FDG uptake represents abnormal findings. However, the area of increased uptake is not always associated with pathology. One such condition is the “hot clot artifact” or “pulmonary microembolism” in which there is intense focal FDG uptake in the lung without any corresponding CT-detectable structural lesion. Awareness of this condition is essential because it may cause misinterpretation as lung metastasis. Herein, we present a case showing focal FDG uptake in lung parenchyma without any structural lesion on CT scan, which subsequently resolved in follow-up imaging. Our case strengthens the importance of knowledge of this finding as misinterpretation of this can have a significant effect on patient management.

Key words: 18F-FDG, PET/CT, Hot Clot Artifact, Pulmonary Micro-embolism.

INTRODUCTION

18F-FDG PET/CT scan is one of the effective diagnostic modalities, especially in the field of oncology for the staging, evaluation of treatment response and monitoring of the patients. It enables the physician to get metabolic and morphologic information which is acquired in a single scanning session. Though malignant cells consume glucose at a higher level as compared to normal cell because of their high metabolic activity, there is possibility of FDG uptake by benign pathologies and even by normal cells which may cause false positive findings on PET/CT scan¹. An extensive knowledge of these uptakes (including biodistribution of FDG, physiological variations in its distribution & related clinical histories of patients) and potential “pitfalls” related to the scanning should be retained in mind during the interpretation of the scans². One such pitfall is the “hot clot artifact” or “pulmonary microembolism”^{3,4}. This condition may lead to a false positivity and this may appear due to injection technique¹.

Agglutination of FDG by erythrocytes develops microemboli, which may lead to a transient obstruction of small pulmonary arterioles. In such conditions, areas of focal FDG uptake with high intensity were found in the lung parenchyma on PET images whereas no lesions were found at the same spots on CT image display⁵. It is important to differentiate hot clot artifacts, as because a misdiagnosis of lung metastasis may lead to an inappropriate staging. Follow-up scanning is suggested in cases of doubt.

In this case report, we present a patient who was referred to our department for treatment response of the disease and was found to have focal FDG uptake in the lung parenchyma with no structural abnormality on the CT scan. The follow-up scan was done with special attention being given to the proper injection technique of the radiotracer and images of the chest were acquired under a similar protocol as before.

CASE REPORT

A 51-year-old lady, diagnosed with diffuse large B-cell lymphoma (DLBCL), status post chemotherapy, was scanned for treatment response. Her blood glucose was 8.9 mmol/L (following an overnight fast) before scanning. A whole body PET/CT scan was done about 60 minutes after the intravenous injection of 6.1 mCi of ^{18}F -FDG. The scan was performed from vertex to mid-thigh using a GE Discovery-IQ 5 ring PET/CT scanner with 5 bed positions, and each position lasted 2 min in a two-dimensional mode. Contrast CT scans of the brain, head & neck, chest, abdomen & pelvis were acquired. Breath-hold CT thorax was also acquired. The CT was performed with an x-ray tube voltage peak of 120 kv, 350 mA, a slice thickness of 2.5 mm, and a rotation speed of 7.5 seconds per rotation. PET images were reconstructed with CT-derived attenuation correction using the Ordered-Subset Expectation Maximization (OSEM) software. Semiquantitative analysis of FDG uptake was performed by calculating SUV (standardized uptake value) values corrected for administered dose & patient's body weight. The PET-CT images were reviewed using the automatic PET-CT fusion software on the workstation. A volumetric region-of-interest (ROI) around the outline of the abnormal uptake was placed on the axial PET images using the semi-automatic software. Then SUVmax (maximum standardized uptake value) was automatically calculated by the PET-CT fusion software and the value was recorded from the workstation. In addition to the findings related to her primary disease, a focal high FDG avid (SUVmax – 30.7) area was seen in the upper lobe of the left lung without any obvious CT-detectable lesion (Figure 1). This was suspected to be a FDG embolus (clot).

The follow-up scan was done under similar circumstances, with special attention being given to a proper injection of the radiotracer. The follow-up scan showed no demonstration of the previously noted hypermetabolic activity in the upper lobe of the left lung (Figure 2). The disappearance of the previously noted intense focus of FDG avidity suggesting an artifact. Based on clinical presentation and imaging studies, a final conclusion of the “hot clot artifact” was made.

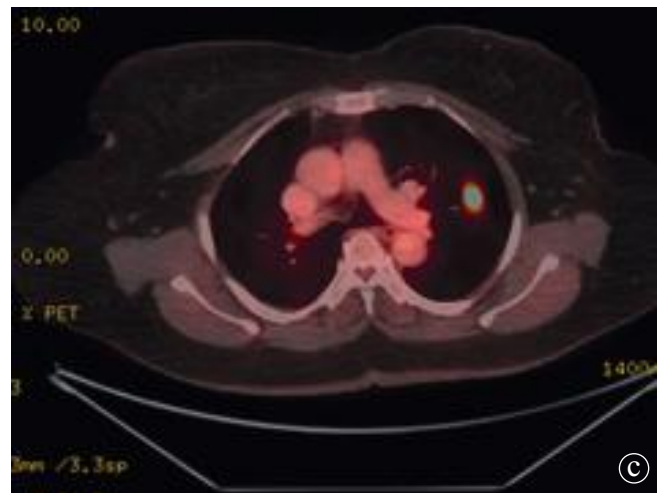
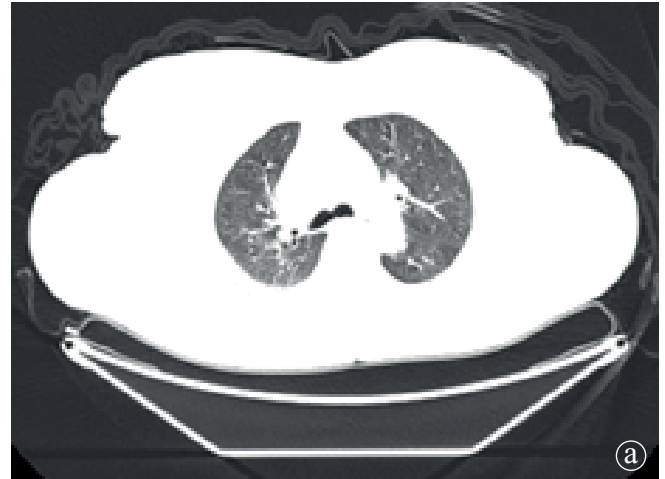


Figure 1: a) CT, b) PET and c) fusion PET/CT axial slices of the initial scan showing a focal high FDG avid (SUVmax – 30.7) area in upper lobe of left lung without any obvious CT detectable lesion.

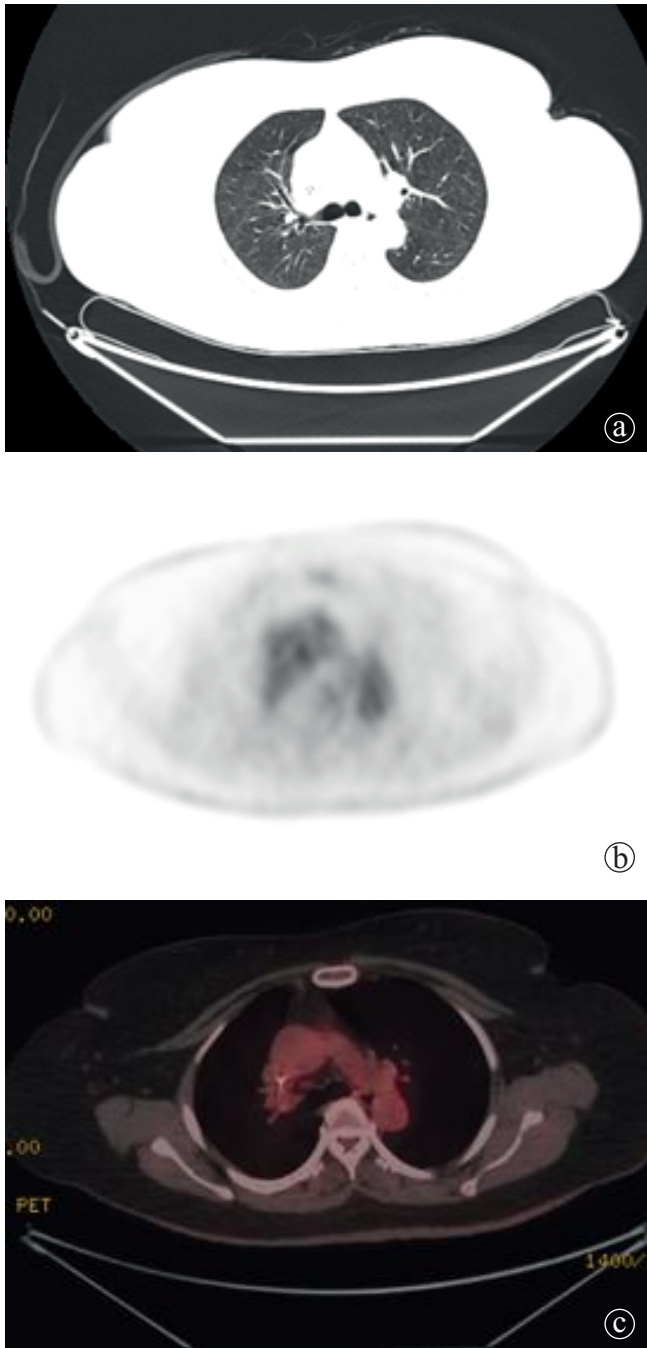


Figure 2: a) CT, b) PET and c) fusion PET/CT axial slices of the follow-up scan showing disappearance of the previously noted hypermetabolic activity in upper lobe of the left lung.

DISCUSSION

Infection, inflammation and metastasis can be the cause of FDG tracer uptake in the lung. All these are invariably associated with structural abnormality on CT scan⁶. Under certain conditions, an area of tracer accumulation in the lung parenchyma may not be associated with any CT abnormality.

This uptake is considered as “hot clot artifact” and may lead to false-positive results if the corresponding CT images are not taken into consideration⁷. And this may be mistaken for pulmonary metastasis, leading to upstaging the disease^{1,4}. The CT portion of the PET-CT is important as it provides information regarding anatomical localization of metabolically active lesions found on PET scan^{1,8,9}.

The underlying mechanism of this artifact is the agglutination of FDG by erythrocytes during FDG injection. Adhesion of FDG to concentrated erythrocytes develops microemboli, which causes occlusive plugs in the pulmonary arterial system and creates the focal FDG uptake with high metabolic activity on PET images¹⁰, but the CT images show no parenchymal nodules. The most common cause of the development of microemboli is blood aspiration into the injector, but paravenous injection and high-speed injection may also be possible causes. The tiny blood clots lodge in the distal capillary lung bed¹.

Mis-registration of PET and CT images is also a reason for the mismatch between the findings on these two modalities. Mis-registration may occur at lung bases, diaphragm and upper abdomen due to breathing movements. Shallow breathing is recommended to achieve optimal image fusion during PET-CT acquisition³.

There are three major points in the diagnosis of a FDG hot clot artifact: 1) Area or multiple areas of focal pulmonary FDG uptake without any corresponding CT findings; 2) High level of metabolic activity in the involved foci, both visually and quantitatively (SUVmax of the lesion must be high); 3) Disappearance of the specific uptake at rescanning with a proper injection technique¹. In this report, we described a focal FDG uptake in lung parenchyma without accompanying lesions on the CT images. The FDG uptake disappeared on the follow-up FDG PET/CT scan. No movement artifact was seen in both instances. The level of FDG uptake was also considerably high in our case with SUVmax – 30.7. This finding was regarded as “hot clot artifact”.

There are some publications regarding FDG hot clot artifact. Ozdemir et al¹. reported on two cases where there were focal and intensely elevated FDG uptakes in lungs without any CT-detectable structural abnormality.

The follow-up scan showed no hypermetabolic activity in the lungs. Similarly, Tokmak⁴, Kumar K⁶, Hussain & Mahmood⁷ and Jahromi & Hoh¹¹ reported on some cases where there was transient visualization of FDG avid abnormalities without any structural lesion which disappeared on follow-up scan.

CONCLUSION

Hot clot artifact or pulmonary microembolism is an uncommon but important condition in which there is F-18 FDG uptake in the lungs without any associated structural lesion. Such abnormality should be considered carefully because it may lead to a false positive diagnosis of pulmonary metastasis and subsequently causes an erroneous staging, which may lead to mistreatment in oncological patients. It is important to identify this cause of false positivity and should give attention to proper injection technique to avoid extravasation or blood aspiration into the injector.

REFERENCES

1. Ozdemir E, Poyraz NY, Keskin M, Kandemir Z, Turkolmez S. Hot-Clot Artifacts in the Lung Parenchyma on F-18 Fluorodeoxyglucose Positron Emission Tomography/CT due to Faulty Injection Techniques: Two Case Reports. *Korean J Radiol* 2014;15:530-3.
2. Kostakoglu L, Hardoff R, Mirtcheva R, Goldsmith SJ. PET-CT Fusion Imaging in Differentiating Physiologic from Pathologic FDG Uptake. *Radiographics* 2004;24:1411-31.
3. Liu Y. Fluorodeoxyglucose Uptake in Absence of CT Abnormality on PET-CT: What is it? *World J Radiol* 2013;5:460-7.
4. Tokmak H. Focal FDG Uptake in Lung Parenchyma Without Structural Alterations on CT. *World J Nucl Med* 2013;12:38-40.
5. Karantanis D, Subramaniam RM, Mullan BP, Peller PJ, Wiseman GA. Focal F-18 Fluoro-deoxy-glucose Accumulation in the Lung Parenchyma in the Absence of CT Abnormality in PET/CT. *J Comput Assist Tomogr* 2007;31:800-5.
6. Kumar K. FDG Emboli on PET/CT scan – A Case Report. *Clin Oncol* 2016;1:1-2.
7. Hussain RP, Mahmood T. The Hot Embolus of 18F-Fluorodeoxyglucose. *World J Nucl Med* 2020;19:438-40.
8. Bikkina P, Kotha S, Ali Z. Abnormal Fluorodeoxyglucose Uptake in Lung Without Structural Abnormality on Computed Tomography. *Indian J Nucl Med* 2017;32:359-60.
9. Chondrogiannis S, Marzola MC, Grassetto G, Zorzi A, Milan E, Rampin L, et al. 18F-FDG PET/CT Lung 'Focalities' Without Coregistered CT Findings: An Interpretative Clinical Dilemma. *Nucl Med Commun* 2015;36:334-9.
10. Ha JM, Jeong SY, Seo YS, Kwon SY, Chong A, Oh JR, et al. Incidental Focal F-18 FDG Accumulation in Lung Parenchyma Without Abnormal CT Findings. *Ann Nucl Med* 2009;23:599-603.
11. Jahromi AH, Hoh CK. FDG Embolism Mimicking Lung Metastasis. *J Clin Images Med Case Rep* 2021;2:1086.