



## Original Article

# Laparoscopic Orchiopexy for the Nonpalpable Testis : *3 Years Experience*

M Nowshad Ali<sup>1</sup>, M Rokeya Khatun<sup>2</sup> S M A Shahid<sup>3</sup>, M Ahmed<sup>4</sup>, Chinmoy Kanti Das<sup>5</sup>

### Abstract

We evaluated the safety and efficacy of laparoscopic orchiopexy to manage a nonpalpable intra-abdominal testis and studied the outcomes. We report our 3 years experience.

#### Patients and methods

Laparoscopic Orchiopexy was performed on 28 children (32 testicular units) for non-palpable intra-abdominal testis between 2010 and 2012. We retrospectively reviewed the medical records. The mean age was 3.4 years (range, 2.5 -11 years). Of the 28 patients, 18 (64.28 %) were on the right, 6 (21.44%) were on the left and 4 (14.28%) of bilateral. The mean follow-up period was 14.8 months (range, 3-36 months). Testicular viability and orchiopexed positioning were evaluated within 1 month and beyond 3 months.

#### Results

Thirty one testes were descended successfully by laparoscopy. The average operative time was  $41.5 \pm 3.8$  min. Primary laparoscopic orchiopexy done in 26 testes. Three of unilateral and 2 of bilateral testicular units underwent one -stage Fowler-Stephens Orchiopexy. One patient needs laparoscopic orchiectomy. At follow-up (mean 14.8 months), one testis atrophied and need orchiectomy. Testicular survival rate was 96.77% (30/31) and all of the testes maintained an adequate size. Twenty six (86.66%) are in an acceptable scrotal position and 4 testes (13.33%) are mid to high in the scrotum without atrophy. There was no recurrent inguinal hernia.

#### Conclusions

Laparoscopic orchiopexy is successful for a nonpalpable intra-abdominal testis with a high testicular survival rate. The low incidence of complications and high success rate underscore the feasibility of this procedure. It is our procedure of choice for the treatment of nonpalpable testis.

**Key words:** non-palpable testis, laparoscopic Orchiopexy, children.

TAJ 2011; 24(2): 70-75

### Introduction

Undescended testis (UDT) is one of the common clinical disorders of childhood, occurring in approximately 3% of full-term newborns, 21% of premature newborns, and 0.8-4% of 1-year-old

boys<sup>1-3</sup>. In the eight week of intrauterine life, the testes arises in the abdominal cavity, and descend through inguinal canal to the scrotum in the third trimester<sup>4</sup>. In 80% of cases of UDT, a testis is palpable in the groin, and in 90% of these boys, it

<sup>1</sup> Associate Professor, Department of Paediatric Surgery, Rajshahi Medical College, Rajshahi.

<sup>2</sup> Assistant Professor, Department of Gynae & Obst, Rajshahi Medical College, Rajshahi.

<sup>3</sup> Assistant Professor, Department of Paediatric Surgery, Rajshahi Medical College, Rajshahi.

<sup>4</sup> Professor, Department of Paediatric Surgery, Rajshahi Medical College, Rajshahi.

<sup>5</sup> Associate Professor, Department of Community Medicin, Rajshahi Medical College, Rajshahi.

is associated with hernia. In these cases, conventional open orchiopexy has been accepted as a standard treatment. In 20% of cases, testis is nonpalpable and among them 20% is absent on exploration<sup>5</sup>. Due to increase risk of malignant transformation and infertility<sup>6-8</sup>, it is important to determine the presence or absence of testis. Accurate preoperative localization of nonpalpable testes has been difficult. CT scan although noninvasive, it is unable in localizing such testes and carries risk of radiation<sup>9</sup>. Sonography and MRI are noninvasive but USG is poor in localizing the nonpalpable testes and the value of MRI has not yet been determined<sup>9</sup> and finally the laparoscopy has become to have the most important role in both diagnostic and treatment of undescended testis<sup>7,8</sup>. Since 1976 when Cortesi and associates first described laparoscopic diagnosis of a nonpalpable testis<sup>10</sup>, this method for diagnosing a nonpalpable testis has been established as the most reliable method. Since 1992 when the first laparoscopic orchiopexy was reported by Jordan et al<sup>11</sup>, laparoscopic orchiopexy has obtained wide popularity with technologic advances. The final goals of orchiopexy are to keep the testes viable to optimal position within the testis. We aimed to evaluate the efficacy and the availability of laparoscopic orchiopexy to manage a nonpalpable intra-abdominal testis in our settings. It was carried out after gaining experience in laparoscopic cholecystectomy, laparoscopic appendectomy and laparoscopic herniotomy. We report our 3 years experience of Rajshahi Medical College Hospital by performing a retrospective review of patient's records concerning testicular viability and orchiopexed positioning.

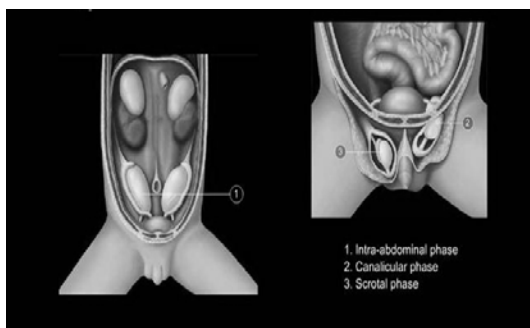


Figure 1: Pathophysiology of Undescended testes.

## Patients and Methods

We reviewed pre and postoperative medical records including clinical results and complications of 28 patients (32 testicular units) who underwent laparoscopic orchiopexy for a nonpalpable intra-abdominal testis between January 2010 and December 2012 in the department of pediatric surgery, Rajshahi Medical College Hospital. The data which is collected contains the following, age of the patients, affected side, location of the testis at the time of laparoscopy, operation performed, operative time, complications and the surgeon who performed the surgery. The age of the children when undergoing the laparoscopic orchiopexy ranged from 2.5 to 11 years. The mean age was 3.4 years. All children had an preoperative ultrasound scan. All were subsequently evaluated laparoscopically. By analyzing the laparoscopic findings, 18(64.28 %) were on the right, 6(21.44%) were on the left and 4(14.28%) of bilateral. The laparoscopies were performed under general anesthesia.

Of 32, 21 testicular units were located within 3 cm of the internal inguinal ring among them one testicle was found atrophied, 5 testicular units (3 of unilateral and 2 of bilateral) were more than 3 cm from the internal inguinal ring, and 6 testicular units were peeping testes. One testis, which was atrophied need orchiectomy. Three unilateral and two of bilateral testes were underwent 1-stage Fowler-Stephens orchiopexy, which was located more than 3 cm from the internal inguinal ring. The remaining 26 patients underwent primary laparoscopic orchiopexy.

**Table I:** Patient characteristic

No of patients	28
No of non palpable testes	32
Mean age (Range)	3.4 (2.5-11) years
Mean follow-up (Range)	14.8 (3-36) months

**Table 2:** No of testicular units (%)

Laterality of intra abdominal testes	
Right	18 (64.28)
Left	6(21.44)
Bilateral	8 (14.28).

**Table 3:** Location of intra-abdominal testes (Laparoscopic finding)

At deep ring/peeping	6 (18.75)
Within 3 cm of deep ring	20 (62.50)
Within 3 cm of deep ring (Atrophied)	1 (3.12%)
Beyond 3 cm of deep ring	5 (15.6)

**Surgical procedure**

All laparoscopic orchiopexy were done under general anesthesia. A stab incision was made in umbilicus through which a Veress needle was inserted and CO<sub>2</sub> was insufflated at a pressure of 10-12 mmHg. A 5 mm laparoscopy port was inserted after enlarging the umbilical stab incision. This port was restricted for the use of a laparoscope with an attached camera that was connected to a television monitor.

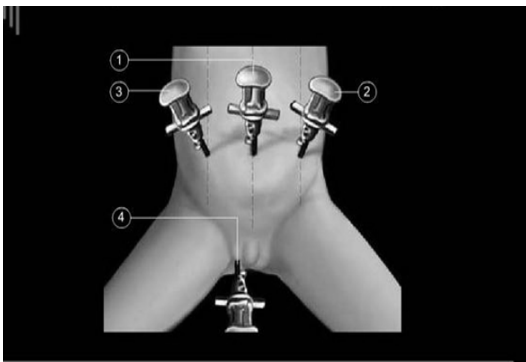


Figure 2: Port position in Orchiopexy.

On laparoscopy specific attention to the landmarks, the location and volume of testes, the length of vas deferens and vessels, the presence of a patent processus vaginalis, and presence of inguinal hernia were determined.

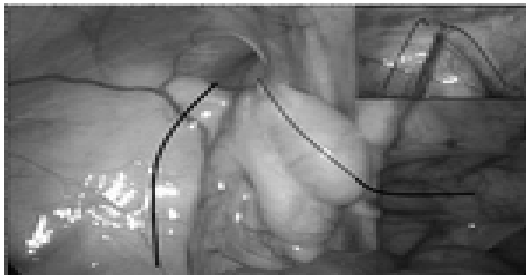


Figure 3: laparoscopic view of UDT

Two additional 3 mm working port were inserted at the lateral border of the rectus muscle in each flank under visual control in order to facilitate the laparoscopic dissection. The port on the side of

UDT was placed at a higher level than the umbilicus and in case of bilateral UDT both ports were placed higher. The child was then placed in Trendelenburg position and the operating table tilted away from the side of the UDT. Further procedure depended upon whether or not the testes were present and their size.

When the testes were found and seemed suitable size, laparoscopic orchiopexy was performed. The gubernaculum of the testes was transected and the dissection was performed alongside the testicular vessels, carefully teasing all the bands with good visual control. Mobilization was carried out up to the aorta and left renal vein or the aorta and venacava depending on the side involved. The vas deferens was also mobilized retaining its blood supply in the adjacent tissue. Practically mobilization of the testis is enough when the testis easily reaches the opposite deep ring.

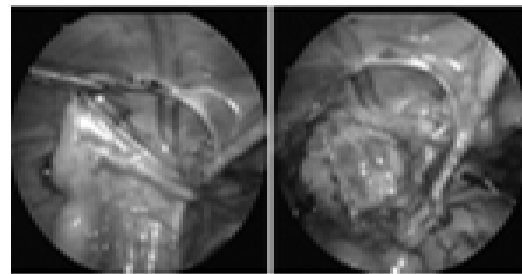


Figure 4: Laparoscopic dissection of UDT

Through a transverse incision made in the scrotum, tip of a long curved artery forceps was guided cephalad in to the peritoneal cavity just medial to the inferior epigastric vessels.

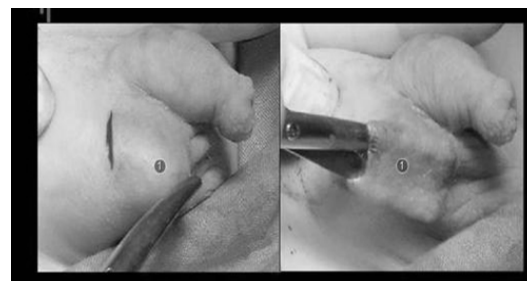


Figure 5: Dartos pouch in Orchiopexy.

Grasping the gubernaculum, the testes were delivered in to the scrotal wound, making sure that there was no twist on the testicular vessels.

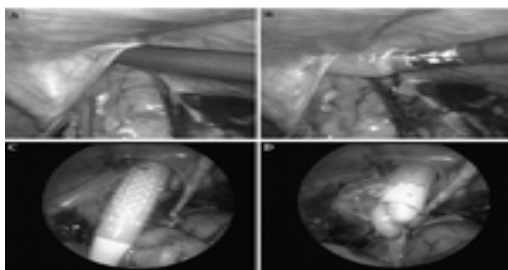


Figure 2: laparoscopic descend down of testis.

The testes were then secured in the extra dartos pouch and the scrotal wound closed with vicryl.

After adequate mobilization when the length is not sufficient testicular vessels are dissected after proper coagulation.

In case of atrophied or severely hypoplastic, it was removed after diathermy of testicular vessels and vas deferens.

The laparoscopy ended in all cases with deflation of peritoneum, suturing of the laparoscopy ports using Vicryl.

## Result

Thirty one testes were descended successfully by laparoscopy. At laparoscopy 6 testes were at the

**Table 4:** Patient's outcome (Beyond 3 months follow-up)

Group	Testes survived	TSR (%)	Position at	Scrotum	Atrophy	Hernia
Total testicular unit (31)	30	96.77	Low scrotum	Mid to high		
PLO (26)	26	100	26	00	00	00
FSLO 1(5)	4	80	00	04	01	00
P value	<0.01	<0.05				

## Discussion

The experience of laparoscopic cholecystectomy, laparoscopic appendectomy and laparoscopic herniotomy has opened the door of laparoscopic management of UDT. Cryptorchidism is the most common disorder of male sexual differentiation and affect about 0.8%-4% of male and 20% of these are non palpable<sup>1-2</sup>. Important long-term sequelae include infertility and testicular tumors. Orchiopexy is thought to decrease the incidence of infertility and allow early detection of tumour. Orchiopexy is recommended at between 6 and 12 months of age as histological damage is thought to occur if delayed<sup>12</sup>. Laparoscopy has been

internal ring or were peeping and the remainder was intra-abdominal. Initially we took significantly longer time for the first 11 patients than the next 17 and the average operative time was 41.5 +/- 3.8 min. Five testicular units underwent 1-stage Fowler-Stephens orchiopexy (3 of unilateral and 2 of bilateral, the distance of them were > 3cm from deep ring). No testicular units underwent 2-stage Fowler-Stephens orchiopexy in this series. The remaining 26 patients underwent laparoscopic orchiopexy without division of any vessels. One patient needs laparoscopic orchiectomy as it was atrophied.

The clinical results within 1 month after the laparoscopic orchiopexy, One testis becomes atrophy and 30 testicular units survived, giving a testicular survival rate (TSR) of 96.77%.

At follow-up (mean 14.8 months) all of the testes maintained an adequate size. 24 of 28 (86%) are in an acceptable scrotal position and 4 testes (14%) mid to high in the scrotum without atrophy or recurrent inguinal hernia.

established as a very useful diagnostic tool in the management of children with non palpable testes<sup>13</sup>. In our study laparoscopically we found all testes in 28 patients who were presented with non-palpable testes. There by it confirmed the accuracy of laparoscopy.

Traditional surgical option of non palpable undescended testes includes a staged orchidopexy<sup>14</sup>, orchietomy or microvascular auto-transplantation<sup>15</sup>. With increasing experience in the usages finer resolution equipment and smaller (pediatric) laparoscopes, a laparoscopic orchiopexy has been shown to be feasible, easier and more effective<sup>16</sup>. In our study a complete laparoscopic orchidopexy was effected on 31

testes. Because of high degree of magnification, laparoscopy gives excellent visualization of testicular vessels up to the origin from the aorta and drainage in to the renal vein and inferior vena cava respectively. All adhesions to the testicular vessels can be divided with precision.

The mean age of the child at presentation was 3.4 years. Although ideal age of orchiopexy is as early as 6 months<sup>12</sup>, it is much higher in this series. It indicates lack of awareness and poor socioeconomic status.

A total 28 patients, incidence of intra-abdominal nonpalpable UDT is higher in right side (64.28% on right, 21.44% on left). It is in conformity with recently published data<sup>17</sup>.

The choice of laparoscopic technique mostly depended on the distance from the internal inguinal ring to the nonpalpable intra-abdominal testis. Among 32, 21 testicular units were located within 3 cm of the internal inguinal ring, 6 testicular units were more than 3 cm from the internal inguinal ring and 5 testicular units showed peeping. We performed, 1 (3.12%) laparoscopic orchiectomy, PLO in 26 (83.87%) and 1 stage FSLO in 5 (16.13%) of 32 testicular units in this study.

One case developed complications within 1 month after the laparoscopic orchiopexy. We performed 1 stage FSLO in a patient with bilateral nonpalpable intra-abdominal testes > 3 cm of the internal inguinal ring, but testicular atrophy was detected in the left testis in the physical examination at the 1 month. It was confirmed by ultrasonography. Subsequently orchiectomy was done after 6 month follow up. At 3 months follow-up, the descended testes are maintained an adequate size. 26 of 29 (86.66%) are in an acceptable scrotal position and 4 testes (13.33%) mid to high in the scrotum without atrophy or recurrent inguinal hernia.

Samadi et al conducted PLO in 70.5% and FSLO in 29.5% of a total of 203 testicular units and reported a success rate of 95%, which was higher than the 76% success rate of open surgery<sup>18</sup>. Lindgren et al did a 6-month clinical follow-up after laparoscopic orchiopexy and reported a success rate of 93%<sup>19</sup>. Lintula et al reported a

success rate of 88% for 19 testicular units undergoing laparoscopic orchiopexy and a success rate of 82% for 18 testicular units receiving open surgery, highlighting the excellent surgical outcomes of the laparoscopic orchiopexy<sup>20</sup>. In our series, 14.8 months after the laparoscopic orchiopexy, the TSR was 96.77% and the rate of fixation in the lower scrotum was 83.87%. These outcomes are similar with those reported studies, and the successful results in this study confirm the clinical significance of laparoscopic orchiopexy for a nonpalpable intra-abdominal testis. We performed one-stage FSLO in 5 testicular units and success rate was 80%. Chang and Franco performed FSLO in 48 testicular units and reported that the success rate of one-stage FSLO was 94.3%<sup>21</sup>. When judged against these figures, the results of the FSLO in the present study were relatively unsatisfactory, but the results were analyzed in only 5 testicular units. We expect improved results in the near future after accumulating experience with FSLO for nonpalpable intra-abdominal testis.

In case of nonpalpable UDT, the reported rate of orchidectomy seems to vary between 14%<sup>2</sup> and 48%<sup>16</sup>. In our series, the orchidectomy rate is 6.25%. Our decision at the time of laparoscopy to carry out orchidectomy was supported by subsequent histopathological result.

## Conclusions

Laparoscopic Orchiopexy certainly avoids a groin or laparotomy incision. It is safe and effective to manage a nonpalpable intra-abdominal testis. It should be method of choice for a nonpalpable intra-abdominal testis.

## References

1. Scorer CG. The descent of the testis. *Arch Dis Child.* 1964; 39:605–609.
2. Levitt SB, Kogan SJ, Engel RM, Weiss RM, Martin DC, Ehrlich RM. The impalpable testis: a rational approach to management. *J Urol.* 1978; 120:515–520.
3. Choi K, Park T, Kim KS. Laparoscopic orchiopexy for intra-abdominal testis: complications and technical aspects. *Korean J Urol.* 2000; 41:420–424.
4. Russell RC, Norman SW, Christopher JK. The testis and scrotum. In: Bailey and Loves Short practice of surgery. 23rd edn. London: Arnold: 2000. pp.1270–83.

5. Z.H.A et al, Laparoscopic orchidopexy: One stage alternative for non-palpable testes, *Ann R Coll Surg Engl* 1996, 78:115-118.
6. Van Savage JU. Avoidance of inguinal incision in laparoscopically confirmed vanishing testis syndrome, *J Urol* 2001; 166:1421-4.
7. Godbole PP Najmaldin AS Laparoscopic orchidopexy in children, *J Endourol* 2001; 15:251-6
8. Tsujihata M, Miyak O, Yashimura k, MATsumiya k, Takahara S, et al. Laparoscopic diagnosis and treatment of nonpalpable testis. *Int J Urol* 2001, 8,692-6.
9. Hinman F. Jr, Localisation and operation for non-palpable testes. *Urology* 1987;30:193.
10. Cortesi N, Ferrari P, Zambarda E, Manenti A, Baldini A, Morano FP. Diagnosis of bilateral abdominal cryptorchidism by laparoscopy. *Endoscopy*. 1976; 8:33-34.
11. Jordan GH, Robey EL, Winslow BH. Laparoendoscopic surgical management of the abdominal/ transinguinal undescended testicle. *J Endourol*. 1992; 6:157-161.
12. Hedinger CC. Histopathology of undescended testes. *Eur J pediatr*. 1982; 139:266.
13. Scott JES. Laparoscopy as an aid in the management of the impalpable testes. *J. Pediatr Surg* 1982; 17:14-16.
14. Fowler R, Stephens FD, The role of testicular vascular anatomy in the salvage of high undescended testes. *Aust NZ J Sur* 1959; 29:92-106.
15. MacMahon RA et al, Result of the use of auto transplantation of the intra-abdominal testis using microsurgical vascular anastomosis. *J paeiatr Surg* 1990; 15:92-96.
16. Froeling FM et al, The non pal-pable testis and the changing role of laparoscopy. *Urology* 1993; 43:222-227.
17. Jhon M Hutson, Undescended tetis, torsion and vericocele, In: *Pediatric Surgery*. 7<sup>th</sup> edn. Philadelphia: 2012. pp. 1003-1019.
18. Samadi AA, Palmer LS, Franco I. Laparoscopic orchiopexy: report of 203 cases with review of diagnosis, operative technique, and lessons learned. *J Endourol*. 2003; 17:365-368.
19. Lindgren BW, Darby EC, Faiella L, Brock WA, Reda EF, Levitt SB, et al. Laparoscopic orchiopexy: procedure of choice for the nonpalpable testis? *J Urol*. 1998; 159:2132-2135.
20. Lintula H, Kokki H, Eskelinen M, Vanamo K. Laparoscopic versus open orchidopexy in children with intra-abdominal testes. *J Laparoendosc Adv Surg Tech A*. 2008; 18:449-456.
21. Chang M, Franco I. Laparoscopic Fowler-Stephens orchiopexy: the Westchester Medical Center experience. *J Endourol*. 2008; 22:1315-1319.

All correspondence to  
**Md. Nowshad Ali**  
 Associate Professor  
 Department of pediatric surgery  
 Rajshahi Medical College  
 Rajshahi, Bangladesh  
 Email : nowshadmd@yahoo.com