


Original Article

Effect of Fenugreek (Methi) on the Thymic Volume in Streptozotocin-induced Diabetic Rats

D K Mondal¹, M M Karim², S Mohal³, B M A Yousuf⁴, K M Shamim⁵

Abstract

Effect of fenugreek (*Trigonella foenumgraecum*) on thymic volume was studied in 30 long Evans rats. Among the total, 10 were treated with only vehicle (non-diabetic control - group A); 10 were treated with streptozotocin only (diabetic control - group B) and 10 were treated with fenugreek (fenugreek treated - group C). Mean relative thymic volumes were 0.222 ± 0.018 ml/100 gm of corresponding final body weight (Mean \pm SEM), 0.147 ± 0.015 and 0.199 ± 0.020 in group A, B and C respectively. In non-diabetic control group the thymic volume was significantly higher ($p=0.005$) than that of diabetic control group. In fenugreek treated diabetic group the volume was also significantly higher ($p=0.05$) from that of diabetic control group and very much nearer to non-diabetic control group ($p=0.398$). Fenugreek may preserve the thymic volume considerably in diabetic rats.

TAJ 2003; 16(1): 1-4

Introduction

Now a days diabetes mellitus is a major health problem. In Bangladesh a high proportion of diabetics are registered to different clinic and institutes, among which only Bangladesh Institute of Research and Rehabilitation in diabetes, Endocrine & Metabolic Disorders (BIRDEM) has registered 1,78,015 cases in 1997, which is more than 15,000 higher than that of previous year. Many of the diabetic patients especially in the rural area have not registered themselves to any diabetic clinic or hospitals and many other still remain undiagnosed.

The oral hypoglycaemics have various side effects and contraindications. In the treatment of diabetes mellitus, has led to scientists to search for alternatives and many natural products indigenous

to various parts of the world. Polyurea has been treated with a large number of herbal products. Some of these are in the usual food list of the people concerned. Scientific studies also revealed the hypoglycaemic properties in many of these herbal products. Among these herbal products fenugreek is a leguminous herb, cultivated in the Indian subcontinent, in the Mediterranean region and in the North Africa.¹ It is also named as 'methi' in this subcontinent which has the hypoglycaemic effect due to its alkaloid 'trigonelline' was reported as early as in 1948 by Fournier, who showed the hypoglycaemic effect in animals², in humans NIDDM^{3,4} and in IDDM patients.⁵

As diabetes mellitus causes decrease in thymic volume^{6,7,8} it may be hypothesized that fenugreek (Methi) being an antidiabetic agent may

¹ Assistant Professor, Department of Anatomy, Khulna Medical College, Khulna.

² Associate Professor, Department of Anatomy, Rajshahi Medical College, Rajshahi.

³ Assistant Professor, Department of Anatomy, Sir Saimullah Medical College, Dhaka.

⁴ Associate Professor, Department of Anatomy, Khulna Medical College, Khulna.

⁵ Professor, Department of Anatomy, BSMMU, Shahbag, Dhaka.

also be used to preserve the thymic volume in diabetes mellitus by minimizing the atrophy of the thymus by inhibiting T-cell death in diabetic rats by improving diabetic state.

Materials and Methods

Fifty eight long Evans rats of either sexes aged 50 to 60 days weighing between 72 to 174 gm were used in this experiment. Among them 10 were treated with vehicle (citrate buffer solution at the pH 4.5) only used as non-diabetic control rats (Group A) and 20 rats were treated with vehicle and Streptozotocin intraperitoneally at a dose of 90mg in 1 ml of citrate buffer solution per kg body wt. On day 1, 20 were found as diabetic, 10 of which were treated as diabetic control group (Group B) and rest 10 (1 died, 1 escaped) were treated with defatted fenugreek (methi) powder at a dose of 1.25gm in 10ml of demineralized water per kg body weight per day orally from day 5 for 8

days and was called as fenugreek treated diabetic group (Group C).

On day 13 all rats were sacrificed and thymus gland was dissected carefully to measure the thymic volume in ml. by water displacement method. A 2 cc syringe was taken and its nozzle was closed with wax. 1cc. of formal saline (i.e. the fixative used for preserving the thymus) was taken in the syringe. Each thymus, dried by soaking with a blotting paper was then submerged in turn in the formal saline. The calibrations of the syringe gave a measure of the volume of the displaced fixative inside and thereby the volume of the thymus. This procedure was performed three times and an average volume was calculated for each thymus.

Results

Table-1 shows the thymic volume on the day of sacrifice of the rat (on day 13 from STZ/Vehicle injection). The thymic volume was estimated in ml.

Table-1: Volume of the thymus on the 13th day

Group	Number of rats	Volume of the thymus	
		Absolute (ml)	Relative (ml per 100 gm of corresponding final body weight)
		Mean \pm SEM	Mean \pm SEM
A (Nondiabetic control)	10	0.27 \pm 0.03	0.222 \pm 0.018
B (Diabetic control)	10	0.19 \pm 0.02	0.147 \pm 0.015
C (Fenugreek-treated diabetic)	8	0.27 \pm 0.02	0.199 \pm 0.020

P value : A vs B = 0.005*, B vs C = 0.053, A vs C = 0.398

In the non-diabetic control group the mean absolute thymic volume was 0.27 \pm 0.03 ml. In diabetic control group the mean absolute thymic volume was 0.19 \pm 0.02 ml and in fenugreek treated diabetic group the mean absolute thymic volume was 0.27 \pm 0.02 ml.

Expression of thymic volume per 100 mg of corresponding final body weight (on day 13 shown in Table-2) could assess whether any change in the thymic volume was merely related to the change in body weight or there was also specific change in the thymic volume relative to body weight. Figure-1 shows the differences among the three groups of rat in this respect. The values shown in Tables and their statistical analyses reveal that the thymic volume relative to the final body weight in the

diabetic control rats was significantly ($p=0.005$) lower than that in the nondiabetic control rats. On the other hand, the mean of values in the fenugreek treated diabetic rats was significantly higher ($p=0.053$) than that in the diabetic control rats but similar to the value in the nondiabetic control rats ($p=0.398$).

Table-2: Final body weight of different groups of rat.

Group	Number of rats	Final body weight on 13th day (gm) Mean \pm SEM
A (Nondiabetic control)	10	120.50 \pm 7.54
B (Diabetic control)	10	134.60 \pm 5.67
C (Fenugreek-treated diabetic)	8	130.75 \pm 5.56

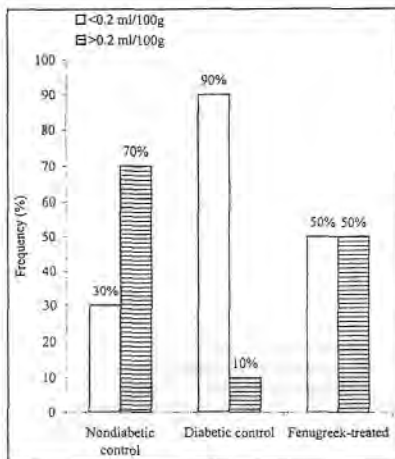


Fig. 1: Thymic volume relative to final body weight (expressed in millilitre/100 gm of body wt on day 13)

Discussion

In this study, Streptozotocin-induced diabetes in rats was associated with a marked reduction in thymic volume. Drugs and pathological conditions impairing insulin production and secretion by pancreatic β -cells caused diabetes mellitus, which results in lymphocytes depletion in thymic cortico-medullary junction. Atrophy of the rat thymus gland occurs after the onset of both drug induced and genetically determined diabetes mellitus. This atrophy is due to loss of thymocytes from the gland.⁶⁻⁹

Chatamara et al., has found that, histologically the cortex of the thymus was clearly reduced in width by the third day after the induction of diabetes with STZ. By seventh day, these changes were pronounced with thickening of connective tissue matrix with some degree of hyaline change of fibrous tissue. By the ninth day the cortex was greatly reduced. After twentieth day there was no clear distinction between cortex and medulla.⁶

In has found in STZ-treated rat thymus that, the width of the cortex obviously became narrower

and the cortical lymphocytes near the cortico-medullary junction appeared to be reduced selectively.⁷

Warley and Morris showed that due to atrophy, the thymus got one third of the weight of the control animals within 10 days. Marked degeneration occurred in the cortical region.⁸

Tabata et al., has also found that in their histologic findings, the cortical region of the thymus of diabetic rat was obviously reduced in size. Cortical lymphocytes present in the vicinity of the cortico-medullary junction appeared to be reduced selectively. Similar changes was not seen in insulin-treated diabetic rats.⁹

In diabetic rat the thymus was severely atrophic. Cortex and medullar was markedly reduced in width and thymocytes were depleted. The cortico-medullary boundary was ill defined and there was fibrosis of the medulla. Insulin and Insulin-like growth factor are responsible to minimize the cortical lymphocyte death in the cortico-medullary junction.¹⁰ Islam MN. has also observed that fenugreek can act against streptozotocin-induced diabetes to prevent reduction of size of pancreatic islets in addition to reduction of blood glucose level. He even suggested possible regeneration of β -cell with fenugreek treatment of STZ-induced diabetes in rats. As defatted fenugreek powder has been used as the antidiabetic agent in this experiment, it has found that the diabetic condition of the rats has improved with possible regeneration of the β -cell of the pancreas to resume the insulin production as in normal condition.¹¹

In case of diabetes mellitus there will be a massive thymocyte death at the onset of the disease. Potassium level is known to be reduced in uncontrolled diabetes as ion fluxes are dependent on insulin. Potassium is required for the correct functioning of RNA in thymocytes. Insulin can potentiate DNA synthesis in lymphocytes. Hence lack of insulin in diabetes mellitus, where it is spontaneous or drug induced like STZ, will cause gross lymphocytic depletion.¹²

In this study, it is found that in non-diabetic control group the mean relative thymic volume is significantly higher than that of the diabetic control group ($p=0.005$). Again in fenugreek treated diabetic group the mean relative thymic volume was significantly higher than that of the diabetic group ($p=0.053$) and more or less similar to the non-diabetic control group ($p=0.398$). So it is comparable to the other studies.⁶⁻¹⁰ From this study it may be concluded that defatted fenugreek preserve the thymic volume by minimizing the cortical lymphocyte death near the cortico-medullary junction in the diabetic rat thymus by the possible regeneration of the β -cell of the pancreas to resume insulin production as in normal condition.

Conclusion

Defatted fenugreek showed a tendency of acting against the lowering tendency of thymic volume in diabetes mellitus. However, further investigations are recommended for establishing fenugreek as a safe, useful effective against lowering the thymic volume as well as antidiabetogenic agent.

Acknowledgements

We would like to express my heartfelt gratitude to my respected teacher Prof. M.A. Hai Fakir, the then Head of the Dept. of Anatomy, IPGMR (at present BSMMU), Dhaka for his valuable suggestions during my study period.

We are also grateful to my teacher Professor Dr. Harun ar Rashid the then Head of the Dept. of Anatomy, IPGMR (at present BSMMU), Dhaka, for his valuable suggestions during my study period.

We are grateful to Dr. Liaquat Ali, Professor, Biochemistry, BIRDEM & Dr. Begum Rokeya, Associate Professor, Pharmacology, BIRDEM for supplying Streptozotocin, rats and other logistic supports.

References

1. Sharma RD. Effect of fenugreek seeds and leaves on blood glucose and serum insulin responses in human subjects. *Nutr Res* 1986; 6:1353-64.
2. Mishkinisky J, Joseph B, Sulman FG, Goldschmid AL. Hypoglycaemic effect of trigonelline. *Lancet* 1967; 2:1311-2.
3. Madar Z, Abel R, Samish S, Arad J. Glucose lowering effect of fenugreek in non-insulin dependent diabetes. *Eur J Clin Nutr* 1988; 42:51-4.
4. Sharma RD, Raghuram TC. Hypoglycaemic effect of fenugreek seeds in non-insulin dependent diabetic subjects. *Nutr Res* 1990; 10:731-9.
5. Sharma RD, Raghuram TC, Rao NS. Effect of fenugreek seeds on blood glucose and serum lipids in type-I diabetes. *Eur J Clin Nutr* 1990; 44:301-6.
6. Chatamara K, Deniel PM, Kendal MD, Lam DKC. Comparison of histological changes in the thymus of fasted, streptozotocin diabetic and genetically diabetic rats with evidence that the enlarged adrenals in diabetes are not the cause of the atrophy in diabetic animals. *J Physiol* 1985; 353:130.
7. Kinoshita Y, Tabata T, Kimura S, Toyakawa T, Okuno Y, Fujii S. Further study on the maturational impairment of the thymic lymphocytes in streptozotocin-induced diabetic rats from the view of peripheral lymphoid organs. *Cell Mol Biol* 1987; 33:387-95.
8. Warley A, and Morris IW. Concentration of elements in dying thymocytes from the thymus gland of diabetic rats. In: scanning microscopy 1988; 2:2227-32.
9. Tabata T, Okuno Y, Fujii S, Kimura S, Kinoshita Y. Maturational impairment of thymic lymphocytes in streptozotocin-induced diabetes in Rats. *Cell Immunol* 1984; 89:250-8.
10. Binz K, Joller P, Froesech P, Binz H, Zapf J, Frosesch ER. Repopulation of the atrophied thymus in diabetic rats by insulin-like growth factor I. *Proc. Natl. Acad. Sci. USA*, May 1990; Vol 87:3690-4.
11. Islam MN. Histological and biochemical effects of spirulina and *Trigonellatoenumgraecum* (fenugreek) on streptozotocin-induced diabetic rats (thesis), Dhaka: Univ of Dhaka, 1997.
12. Kendal MD. Anatomical and physiological factors influencing the thymic microenvironment. *Thymic update* 1988; 29-65.

All correspondence to:

D K Mondal

Assistant Professor,

Department of Anatomy,

Khulna Medical College, Khulna.