



## Case Report

# Recurrent episodes of vomiting and hyperpigmentation---Addison's disease, a case report.

MB Uddin<sup>1</sup>, F Zaman<sup>2</sup>, KI Jahan<sup>3</sup>, MH Tarafder<sup>2</sup>, A Hossain<sup>4</sup>, F Rahman<sup>5</sup>,

### Abstract

Addison's disease can remain unrecognized for a longtime until acute adrenal insufficiency is precipitated by an acute stress. Addison's disease usually presents with non-specific symptoms like fatigue, nausea, vomiting, hyperpigmentation and generalized weakness. These symptoms are most often ignored or misinterpreted with other more common diseases. This is the major reason that this disease is under-diagnosed. Therefore, to establish a diagnosis high index of suspicion is needed. We are reporting a case of 10 years old boy who presented with recurrent episode of severe vomiting and generalized weakness. This kind of presentation of Addison's disease is rather unusual and mainstay of diagnosis is clinical based.

TAJ 2016; 29: No-2: 66-69

### Introduction

Addison's disease has an incidence of 0.8 per million and a prevalence of 40-110 per million in USA and European countries.<sup>1</sup> Endocrinal disorders remain undetected in the early part of their presentation, especially in developing countries due to lack of awareness amongst clinicians as well as limited facilities for special investigations. It occurs in all age groups and affect men and women equally. The two most common causes of Addison's disease are autoimmune adrenalitis and tuberculosis. Other causes include invasion of glands by neoplastic cells, CMV virus HIV, hemochromatosis, amyloidosis, hemorrhage (Water House Frederickson's syndrome) and surgical removal of glands. The symptoms of adrenal insufficiency usually develop gradually with chronic fatigue, muscle weakness, loss of appetite, nausea, vomiting, and diarrhea. In about 50% of cases,

blood pressure is low and falls further in erect posture, causing dizziness or fainting. Skin changes are also common with the areas of hyperpigmentation, more on exposed parts of the body. Addison's disease can cause irritability and depression because of salt depletion, resulting in craving for salty foods. The combination of autoimmune disorder and Addison's disease is described as polyglandular autoimmune disorders, type I (PGA I) and type II (PGA II). In PGA I, there is associated hypothyroidism and mucocutaneous candidiasis and in PGA II there are hypo- or hyper-thyroidism, type I diabetes mellitus, primary ovarian or testicular failure and pernicious anemia.<sup>3</sup>

<sup>1</sup> Associate. Professor. Dept. of Pediatrics. Pabna Medical College.

<sup>2</sup> Asstt. Registrar. Dept. of pediatrics. Rajshahi Medical College.

<sup>3</sup> Lecture, Dept. of Biochemistry Rajshahi Medical College.

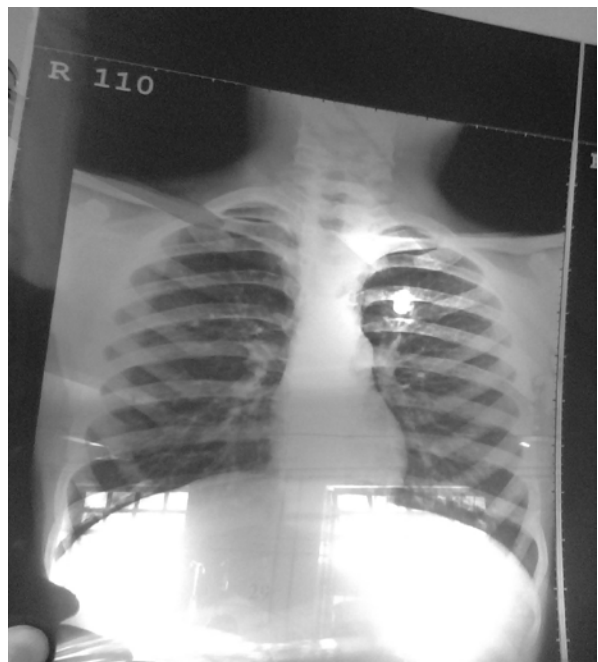
<sup>4</sup> Associate Prof. of Pediatrics, Rajshahi Medical College.

<sup>5</sup> Junior consultant (Deputation), Rajshahi Medical College Hospital.

**Case report:**

Mahfu, 10 years old boy male, muslim, boy of a middle class family, 2nd issue of a non consanguineous parents hailing from Chapai Nawabgonj admitted in this hospital with the complaints of vomiting and abdominal pain for last 5 days. He had also history same type of episodes in milder form for the last 2 years. Each episodes occurred at 3-4 months interval, lasted for about 7 days. He also developed progressive weakness and blackening of the skin for last 2 years. No history of fever, rash, cough, contact with TB patients or taking any offending drugs. On examination Patient was conscious, cooperative, ill looking, eyes were shrunken, temp. 99<sup>o</sup>F, resp. rate-22/ min. Pulse-102/ min. dehydrated, increased pigmentation of the skin of the whole body specially palm, sole, lips and face. Abdomen was non tender, no organomegaly found. He attained his milestones at appropriate age. He had weight= 22.5 kg, 73% of NCHS median. Height= 129 cm, 72% of NCHS median. His vitals showed a significant postural drop from 90/60 mmHg in

lying position to 75/50 mmHg in standing posture. His Hb level was 16.5 g/dl, showing normocytic normochromic blood picture. Fasting blood sugar was 5.4 mmol/L, serum sodium 124 mEq/L and potassium 6.8 mEq/L. Chloride 85.00 mmol/L. PCO<sub>2</sub>=23.00 mmol/L. X-Ray chest revealed microcardia. His ultrasonography and CT scan of abdomen were normal. No calcification or any other abnormality was seen in adrenal glands. Mantoux test was negative. **ECG shown Tall peaked T wave. Serum ACTH was: >1250.00 pg/ml. S. Cortisol: 3.22 microgm/dl.** Thyroid function tests were normal. Above features strongly consistent with Addison disease. After extensive workup no definite etiology could be detected in this patient. He was treated with Inj. Hydrocortisone 100 mg i.v 6 hourly for 48 hours and his hyponatraemia was corrected by 0.9% NaCl saline by i.v. then he was treated oral tab. Hydrocortisone 10 mg. with this drug therapy, after 6 weeks patient gained 5 kg weight. He is now able to walk, even run and there is no postural drop. Severity of hyperpigmentation is reduced. He is looking healthy and cheerful, and at present he is on a maintenance dose of 5 mg in the morning and 2.5 mg in the evening.



**CXR shows microcardia.**

### Discussion:

Thomas Addison (1855) first described the clinical features of primary adrenal insufficiency, which may result from a variety of pathological processes.<sup>4</sup>The most common cause of Addison disease is autoimmune destruction of the glands. Most patients have antiadrenal cytoplasmic antibodies in their plasma; 21-hydroxylase (CYP 21) is the most commonly occurring autoantigen.<sup>5</sup> Furthermore primary adrenal insufficiency may also be caused by disorders in the main enzymes involved in steroidogenesis or by X-linked adrenoleukodystrophy, by a mutation in ABCD1 gene that may induce death of adrenocortical cells.<sup>6,7</sup> An inherited pathology characterized one of the most important signs of Addison's disease is cutaneous and mucosal hyper pigmentations related to ACTH melanogenesis action. Pigmentation can be homogeneous or blotchy, it does not depend on gender or race. It may involve skin, oral cavity, conjunctiva and genitalia. It is more evident in areas exposed to the sun and under mechanical

stimulation: palmar creases, knuckles, flexural areas, areolas of nipples, scars and genital mucosa. Brown patches of gingival, vermilion border of the lips, buccal mucosa, palate and tongue may represent the first signs of Addison's

disease.<sup>8</sup>A medical history of the symptoms is often sufficient to raise a suspicion of Addison's disease. Quite often the first clue is from the abnormal laboratory tests, like hyponatraemia, hyperkalaemia, hypoglycemia, eosinophilia, neutropenia and hypercalcemia.<sup>9,10</sup> The most specific test for diagnosis is ACTH stimulation

(Synacthen) test. In the short or rapid, stimulation test, measurement of cortisol in blood is repeated 30 and 60 minutes, after an intravenous injection of synthetic ACTH. The patient with adrenal insufficiency responds poorly or do not respond at all. Sometimes a long ACTH stimulation test is required to determine the secondary cause of adrenal insufficiency.<sup>11,12</sup>Since all of the manifestations of Addison's disease are caused by the lack of cortisol and aldosterone, the treatment is to replace these with similar steroids. Cortisol is

usually replaced orally by hydrocortisone tablets and aldosterone is replaced by an aldosterone like synthetic steroid, fludrocortisone (Florine) tablets. The doses of each of these medications are adjusted according to the individual's response and any co-existing medical condition. Response may be seen clinically by observing blood pressure, postural drop, reduction in the hyperpigmentation and bio-chemically may be seen by improvement in the imbalance of the serum electrolytes, blood sugar and serum renin. In emergencies or during surgery, hydrocortisone must be given intravenously.<sup>13,14</sup> Patients with Addison's disease should be taught to treat minor illnesses with extra salt and fluids. A person who has adrenal insufficiency should always carry identification card, stating his or her condition, with full address & contact numbers. As long as the proper dose of replacement medication is taken every day, an Addisonian can have a normal crisis-free life.<sup>15</sup>

### Conclusion:

Addison's disease can remain unrecognized for a longtime until acute adrenal insufficiency is precipitated by an acute stress. Addison's disease usually presents with non-specific symptoms. These symptoms are most often ignored or misinterpreted with other more common diseases. This is the major reason that this disease is underdiagnosed. Therefore, to establish a diagnosis high index of suspicion is needed.

### References:

1. Ganapati M. Endocrine disorders remain undetected untreated in India. *BMJ* 1999; 318: 216. Sharma et al. *Journal of Medical Case Reports* 2010, 4:60.
2. An Unusual Presentation of Addison's Disease—A Case Report.  
Sandeep Choudhary 1, Anwer Alam1, Vivek Dewan 1, Dinesh Yadav1, and N.K. Dubey. *IPGIMER & Dr RML Hospital, New Delhi, India.* 2011; 20 (3), 57-60.
3. Unusual presentation of Addison's disease. Zaman Shaikh, Muhammad Umar, Mehwish Nisar. *Pak J Med Sci May - June 2007 Vol. 23 No. 3 475-478.*
4. *Annals of African Medicine.* Vol. 2, No. 2; 2003: 85-87. Addison's disease: a case report. C. O. Alebiosu and O. Odusan.

5. Nelson Textbook of Pediatrics. 19<sup>th</sup> edition. Kliegman, Staton, St. Geme, Schor & Behrman.
6. Arlt W, Allolio B. Adrenal insufficiency. Lancet 2003; 361: 1881-93. Martin Martorell P, Roep BO, Smit JW.
7. Autoimmunity in Addison's disease. Neth J Med 2002; 60: 269-75.
8. The Open Dermatology Journal, 2009, 3, 3-6 3. Oral Pigmentation as a Sign of Addison's Disease: A Brief Reappraisal. Alessandro Lanza, Inam Heulfe, Letizia Perillo, Antonio Dell'Ermo<sup>2</sup> and Nicola Cirillo.
9. Fitzgerald AP. Chronic adrenocortical insufficiency', Endocrinology. In: Current medical diagnosis and treatment 2006 (45th editions), Lange Medical books /McGraw Hill, Medical Publishing division. New York. 2006; pp 1174-76.
10. Sid haye RA. 'Addison's disease'. Medline pulse encyclopedia, (www.medlineplus.gov), Article no. 000378, 6:2004.
11. Chrouisios GP. 'Information of endocrine and metabolic diseases'. NIH publications, (www.endocrine.niddk.nih), 2004; pp 04-3054, 6:
12. NHS encyclopedia. Addison's diseases, articles no 7, (www.nhsdirect.nhs.uk) section 2006; 13589:4.
13. Mayo's Clinical staff, 'Addison's Diseases Overview', (www.mayoclinic.com), Reg. no DS00361, 6: 2006.
14. Greenspan FS. 'Diseases of Adrenocortical Insufficiency'. 'Basic and Clinical Endocrinology (fifth edition), Appleton and Lange. Resident Medical PrenticeHall International 1997; pp:337.
15. Besser GM., 'Adrenal Cortex', Fundamental of Clinical Endocrinology (fourth edition) Churchill Livingstone, Edinburgh London, 1982; pp: 171-72.

All corresponds to  
**Md. Belal Uddin**  
Associate. Professor  
Dept. of Pediatrics  
Pabna Medical College.