



## Case Report

# Ileo-caecal Tuberculosis Associated with Hepatic Involvement-A Case Report

S M K Nahar Begum<sup>1</sup>, M Azizul Hoque<sup>2</sup>, M Khalilur Rahmen<sup>3</sup>, A K Pramanik<sup>4</sup>, S Shafiqul Alam<sup>5</sup>

### Abstract

This is the case history of a 36 year old male who presented with fever, diarrhoea, weight loss with tenderness in the right hypochondrium and right ileac region. This was finally diagnosed as an interesting case of ileo-caecal tuberculosis with associated hepatic involvement.

TAJ 2007; 20(1): 60-63

### Introduction

Tuberculosis is one of the most common and well documented infectious diseases, with a vast majority of clinical manifestations. Abdominal tuberculosis is defined as infection of the peritoneum, hollow or solid abdominal organs with *Mycobacterium tuberculi*.<sup>1</sup> It can involve any part of the gastrointestinal tract and is the sixth most frequent site of extra-pulmonary involvement. The peritoneum and the ileo-caecal region are the most likely sites of infection and are involved in the majority of the cases.<sup>2</sup>

On the other hand tuberculosis of the liver is a rare condition and till 1977 only 90 cases were reported in the world literature.<sup>3</sup> Since then some more cases have been added by various workers.<sup>4,5</sup> Multiple sites in the same patient may be involved and our case is a good example of involvement of Liver along with the GI tract.

Tuberculous bacteria reach the gastrointestinal tract via hematogeneous spread, ingestion of infected sputum, or direct spread from infected

contagious lymph nodes via lymphatics. The gross pathology is characterized by transverse ulcers, fibrosis, thickening and stricturing of the bowel wall. Tuberculosis of Liver is quite common in millitary tuberculosis which occurs via generalized hematogeneous or lymphohematogeneous route.<sup>1</sup> The concomitant presence of hepatic as well as ileocaecal tuberculosis can be explained by extension into Liver through direct spread from colon or via hematogeneous /lymphohematogeneous route. The clinical presentation of abdominal tuberculosis can be acute, chronic or acute on chronic. Most of the patients have constitutional symptoms of fever, pain, diarrhoea, constipation, weight loss, anorexia and malaise.<sup>2</sup>

### Case Report

A 36 year old male presented at a private clinic of Rajshahi district with complaints of dull upper abdominal pain, diarrhoea, fever with chills and rigor and occasional vomiting. The onset is gradual with increasing weakness and deterioration of general health. He was non-

<sup>1</sup> Assistant Professor, Department of Pathology, Islami Bank Medical College, Rajshahi.

<sup>2</sup> Associate Professor, Department of Medicine, Rajshahi Medical College, Rajshahi.

<sup>3</sup> Professor, Department of Surgery, Rajshahi Medical College, Rajshahi.

<sup>4</sup> Associate Professor, Department of Surgery, Islami Bank Medical College, Rajshahi.

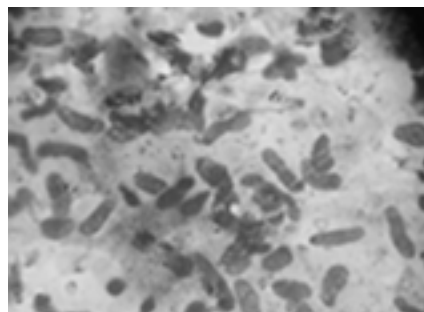
<sup>5</sup> Consultant Sonologist, Hepta Health Care; Rajshahi.

smoker, non-alcoholic and had no major illness in the past. On clinical examination the patient was looking pale and had a moderate rise of temperature.

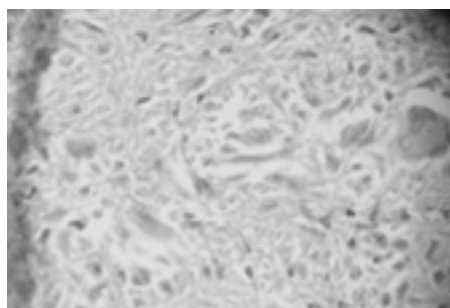
Investigation showed hemoglobin 10.8 gm/dl, total leukocyte count 5,000/dl (Polymorphs 66%, Lymphocytes 28%, Eosinophils 04%, Monocytes 2%), Sedimentation rate 30 mm/1<sup>st</sup> hour, urine and stool examination normal. HIV test was negative. Chest skiagram and Liver function tests were within normal limit. Ultrasonogram of Liver showed an inhomogeneous predominantly hypoechoic mass measuring 6.9X5.6 cm. is seen in the left lobe of the Liver. A provisional diagnosis of hepatic neoplasm is made. On the next day aspiration of the hepatic mass was done. About 4 ml. of thick haemorrhagic material is aspirated. The smears revealed polymorphs, lymphocytes, plasma cells and few clusters of regenerating hepatocytes. No granuloma or malignancy was seen. The lesion was cytologically described as a healing abscess; not otherwise specified. On continuous deterioration of general condition in spite of adequate conservative treatment, patient was admitted to Rajshahi Medical College Hospital. A second Ultrasonogram was done. In addition to the hepatic mass, a uniform and concentric bowel wall thickening was seen in the ileocaecal region. Ascending colon was also diffusely thick. The case was again referred for ultrasound guided FNAC of the Ileo-caecal mass. Aspirates were taken from multiple sites. The smears showed collections of epithelioid histiocytes against caseous necrotic background. Degenerating polymorphs, macrophages and occasional Langhan's giant cells were seen (Fig-2). Diagnosis of Tuberculosis was made and anti-tubercular therapy was started immediately including initial 2 months of rifampicin, isoniazid, pyrazinamide and ethambutol.

To confirm the diagnosis and to eradicate the disease locally patient was advised for surgery within one month of chemotherapy. On laparotomy numerous small nodules were seen in the terminal ileum, the whole of the caecum and part of

ascending colon. A hard nodular mass measuring 2X2 cm. was seen in the left lobe of the liver. Few small nodules were seen in the right lateral surface of the right lobe. No enlarged mesenteric or periportal lymph node was seen. Right hemicolectomy was done and an incisional biopsy was taken from the hepatic lesion in the left lobe. Histopathological features of both the specimen were consistent with Tuberculosis (Fig-3).



**Fig. 1:** Photomicrograph of FNA smears from the ileocaecal mass. MGGX650



**Fig. 2:** Photomicrograph of histological section from the hepatic lesion. H&EX300

The patient was seen after 5 months on follow up. He was asymptomatic and had gained 4 kg weight. Colonoscopy was performed which showed normal mucosa upto the ileocaecal junction. Check ultrasonogram revealed a normal study.

## Discussion

Tuberculosis was declining gradually but has shown a reverse trend after the appearance of the AIDS epidemic, making tuberculosis a global health problem once again. Both the incidence and severity of abdominal tuberculosis are expected to increase with increasing incidence of HIV infection. Liver involvement in tuberculosis,

though common both in pulmonary and extra-pulmonary tuberculosis, is usually clinically silent<sup>6</sup>. Occasionally, local signs and symptoms may be prominent in hepatic tuberculosis, and may constitute the initial or sole presenting feature of the disease. Tuberculosis of the G I tract most commonly affects caecum with approx. 85% of patients having disease at this site.<sup>7</sup> Other common sites in order of frequency are ascending colon, jejunum, appendix, duodenum, esophagus, sigmoid colon and rectum.<sup>8</sup>

Isolated involvement of Liver is a very rare occurrence.<sup>9</sup> The clinical diagnosis of hepatic tuberculosis had always been difficult.<sup>10</sup> In our case patient first presented with the hepatic illness. The associated ileo-caecal involvement was noticed later on. The hepatic lesion was ultrasonologically suggested to be neoplastic one. A healing abscess with internal calcifications may mimic a low density tumour by ultrasonography and computed tomography<sup>11</sup>. Though cytological diagnosis was a healing abscess, a confirmatory diagnosis of tuberculosis was finally made by surgical biopsy. A problem in the tissue diagnosis of local hepatic tuberculosis is the high rate of false negative results with needle biopsy technique.<sup>12</sup> The ileo-caecal lesion was however cytologically diagnosed as of tuberculous type. Our case is a unique example of involvement of liver along with the colon. And such an involvement has occurred in absence of any discernible tuberculous lesion in chest X-ray. Chest X-ray show concomitant pulmonary lesions in less than 25% of cases of abdominal tuberculosis.<sup>13</sup> Evidence of tuberculosis in a chest X-ray supports the diagnosis but a normal chest X-ray does not rule it out.<sup>14</sup> Cytology and histopathology are the established mode of diagnosis of abdominal tuberculosis without the need for demonstrating AFB and/or culturing tubercle bacilli.<sup>15</sup>

Differential diagnosis from Crohn's colitis and hepatic involvement by Crohn's disease, may at times, however be difficult even with experienced observers.<sup>16</sup> In such cases response to treatment aids in final diagnosis.<sup>17</sup> In our case diagnosis of

tuberculosis was made in preference over Crohn's disease because of several points. First of all, caseation necrosis was found in both the hepatic and the intestinal lesions. Secondly fissures or fistulas were never encountered throughout the illness or during follow up and finally Crohn's disease is very rare in our subcontinent. Also the dramatic response of the patient to anti-tubercular treatment was also suggestive of the disease.

Another important differential diagnosis could be intestinal lymphoma since ileo-caecal region is a common site for lymphoma. But the associated hepatic involvement does not support the diagnosis and also lymphoma was excluded by the investigative procedures.

The most common complication of ileo-caecal tuberculosis is obstruction due to narrowing of the lumen by hyperplastic caecal tuberculosis.<sup>2,18</sup> Our case was free from any obstructive symptom. Mesenteric lymph node involvement is also very common with ileo-caecal tuberculosis.<sup>2</sup> No nodal involvement was seen in our case. Tuberculous involvement of Liver may occasionally involve the gall bladder causing obstructive jaundice which was not the case in our patient. Though there was no obstructive phenomenon, a surgery was done here firstly to confirm the cytological diagnosis, secondly to explore the hepatic pathology and finally for the fact that our patient had an intense urge to get rid of the lumps as earlier as possible.

## References

1. Sharma M P & Bhatia Vikram. Abdominal Tuberculosis. *Indian J Med Res* October 2004; 120: 305-315.
2. Bhansali S K. Abdominal tuberculosis. Experiences with 300 cases. *Am J Gastroenterol* 1977; 67: 324-337
3. Rab S M & Beg M Z: Tuberculous liver abscess. *Brit J Clin Pract* 1977; 31:157-158.
4. Jain V K, Mathur K C, Chadda V S and Lodha S K . Tuberculous liver abscess (A case report). *Indian J Chest Dis & Allied Sci* 1981; 23:97-99.
5. Siwach S B & Srivastava S C. Tuberculous abscess of the liver. *Ind J Chest dis & Allied Sc* 1978; 20:145-147.

6. Reynolds T B, Campra J L, Peters R L, Hepatic granulomata. In Zakim D, Boyer T.D. editors. *Hepatology - A textbook of liver disease*, 2nd ed. W.B. Saunders, Philadelphia 1990:1098.
7. Bhargava D K. The place of colonoscopy. *Ind J Surg* 1983; 45: 150-164.
8. Grobich SL. Tuberculosis of the gastrointestinal tract in Sleisenger MH Fordan J S editors. *Gastrointestinal disease*. Philadelphia: WB Saunders Co 1993; 39:213-220.
9. Hirsch C. Tuberculosis of Liver, A study of 200 cases. *South African med J* 1964; 39:587.
10. Leader S A. Tuberculosis of liver and gall bladder with abscess formation. A review and case report. *Ann Int Med* 1952; 37:594-606.
11. Sheen-Chen S M, Chen M C, Hu TH, Eng H L, Chen WJ et al. Computed tomography and angiography in hepatic tuberculosis mimicking liver tumour. *Int J Tuberc Lung Dis*. September 2001; 5(9):876-878.
12. Oliva A, Duarte B, Jonasson O, Nadimpalli V. The nodular form of local hepatic tuberculosis. *J Clin Gastroenterol* 1990; 12:166.
13. Vij J C, Malhotra V, Chowdhury V, Jain N K, Prasad G, Chowdhury et al. A clinicopathological study of abdominal tuberculosis. *Indian J Tuberc* 1992; 39:213-220.
14. Kapoor V K, Chattopadhyay TK, Sharma L K. Radiology of abdominal tuberculosis. *Australas Radiol* 1988; 32:365-367.
15. Shah S, Thomas V, Mathan M et al. colonoscopic study of 50 patients with colonic tuberculosis. *Gut* 1992;33:347-351.
16. Hoon J R, Dockerty MB, Pemberton J. Ileocaecal tuberculosis including a comparison of this disease with non-specific regional enterocolitis and non-caseous tuberculated enterocolitis. *Int Abstr Surg* 1950; 91:417-440.
17. Anand B S. Distinguishing Crohn's disease from Intestinal tuberculosis. *Natl Med J India* 1989;2:170-175.
18. Bhansali S K, Sethna J R. Intestinal obstruction: a clinical analysis of 348 cases. *Indian J Surg* 1970; 32:57-70.

All correspondence to:  
**S M K Nahar Begum**  
 Department of Pathology,  
 Islami Bank Medical College,  
 Rajshahi.