



Case Report

Precocious Puberty- A Case Report

K Kabiruzzaman Shah¹, N Begum Laz², A B Siddique³, F U Ahmed⁴

Abstract

Appearance of secondary sexual development before the age of 9 in a male child and before the age of 7 in a female child is called precocious puberty. When the cause of precocious puberty is premature activation of the hypothalamic-pituitary axis, it is called central or complete precocious puberty, if ectopic gonadotrophin secretion occurs in boys or autonomous sex steroid secretion occurs in either sex it is called incomplete precocious puberty. [Here we are reporting a 5 year old girl with central precocious puberty.

TAJ 2008; 21(1): 83-86

Introduction

Puberty is the process by which sexually immature persons become capable of reproduction.¹ Puberty usually occurring during adolescence, is when kids develop physically and emotionally into young men and women. Usually this starts to happen no earlier than about 7 to 8 years of age for girls and 9 yrs for boys (average age is about 10 yrs for girls and 12 yrs for boys).² Pubertal change occur largely as the result of maturation of hypothalamic pituitary gonadal axis. Puberty may truly precocious, if stimulus for such change is due to early hypothalamic pituitary activity.³ On the other hand precocious puberty is puberty that begins before age 8 yrs for girls and before 9 yrs for boys.⁴ Isolated sexual precocity of unknown etiology carries no increased risk of mortality, however, distinguishing between children with idiopathic CPP and rare patient with a CNS, adrenal or ovarian tumor is important because the latter group may be at risk for tumor related complication. Children with precocious puberty

may be stressed because of physical and hormonal changes; they are too young to understand.⁵ Going through puberty early can also be difficult for a child emotionally and socially. For example, girls with precocious puberty may be confused or embarrassed about physical changes such as getting their periods or having enlarged breasts well before any of their peers.⁶ Not only that precocious puberty cause the child to become an object of adult sexual interest.⁷

In our country precocious puberty children are suffered more, their family members are also suffered both psychologically and emotionally. Here we described a child of precocious puberty.

Case report

A female child of about 05 yrs old having bilateral enlargement of breast, mild acne and H/O per vaginal bleeding for more than 01 years was referred by Prof and head of the paediatric Department Dr. A B Siddiqui FRCP (UK), FAAP (USA) for USG and hormonal analysis in centre

¹ Assistant Professor, CNMU, Rajshahi.

² Medical Officer, CNMU, Rajshahi.

³ Professor and Head, Department of Paediatric, Rajshahi Medical College Hospital, Rajshahi.

⁴ Director, CNMU, Rajshahi.

for Nuclear Medicine and Ultrasound (CNMU), Rajshahi. USG showed ovaries were prominent (right ovary- 2.1 x 0.9 cm and left ovary- 1.8 x 1.0 cm) and follicles were present in each ovarian parenchyma, uterus was measuring about 4.8 x 1.2 cm (L x AP).

Serum T₃ T₄ & TSH levels were normal but other hormone levels were abnormally high i.e., very high FSH, LH, Prolactin, Testosterone, and progesterone level. Then Brain Scan was performed which revealed no evidence of intracranial mass. After that patient was advised for brain CT at CNMU, Rajshahi. CT scan showed a space-occupying lesion in the right fronto-parietal lobe. Then Patient was sent to Prof. K.K. Barua in Dhaka for better management. Further investigation i.e. MRI of the brain, Serum Beta - hCG levels etc were done. Finally the patient diagnosed as a case of central precocious puberty.

Medication was given to reduce the hormonal level and advised Radiotherapy for brain tumor, unfortunately the party was too poor to continue the therapy and treatment.

Discussion

The frequency of precocious puberty in girl and boy largely depends on the age, which the condition is considered precocious.⁸ A 2003 review of trends in timing of puberty around the world show no clear trend toward earlier puberty in Northern Europe, but earlier mean age of menarche has been reported in some southern European countries and other warmer part of the world.⁹ An interesting and still unexplained finding is the high incidence of precocious puberty in girls adapted in to Western Europe from underdeveloped countries.¹⁰

Herman-Giddens et al reported on the incidence of breast and pubic hair development by age and race in 17,000 girls age and 3- 12 yrs. They used the establish definition that or pubic development in girls was precocious before age 8 yrs and estimated that approximately 8 % of white and 25 % of back girls in USA.¹¹

Abnormalities of pubertal development can be divided in four major categories-

1. Precocious puberty.
2. Delayed puberty.

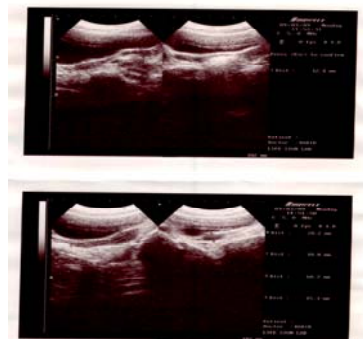
3. Asynchronous pubertal development and
4. Hetero-sexual pubertal development.¹²

If the history, physical examination and laboratory data suggest that a child exhibits easy and sustained evidence of pubertal maturation, the clinician must differentiated central precocious puberty (CPP) from precocious pseudo puberty. CPP, which is gonadotropin dependent, is the early maturation of entire hypothalamic pituitary gonadal axis, with full spectrum of physical and hormonal changes of puberty.¹³

The onset of puberty is causes secretion of high amplitude pulses of gonadotropin- releasing hormone (GnRH) by the hypothalamus. High – amplitude pulses of GnRH cause pulsatile increases in the pituitary gonadotropin- luteinizing hormone (LH) and Follicle stimulating hormone (FSH). Increase LH levels stimulates production of sex steroid by testicular leydig cells or ovarian granulosa cell. Pubertal levels of androgen or estrogens cause physical changes of puberty, including breast development in girls and penile enlargement in boys. These levels also mediate the pubertal growth spurt. Increased FSH level cause enlargement of the gonads in both sexes and eventually promotes follicular maturation in girls and spermatogenesis in boys.¹⁴

Here in this case RIA of different hormones levels are high. FSH level- 2.78 IU/L (Normal- < 1.16IU/L), LH level- 8.03IU/L (Normal-up to 1.91 IU/L), Prolactin 637 mIU/L (Normal - < 460 mIU/L), Progesterone level- 75.0 ng/mL (Normal up to 35 ng/mL), & Testosterone level- 6.95ng/mL (Normal 2.3ng/mL).

So this was a case of true precocious puberty.



Picture I – Ultrasonography – prominent ovaries and uterus.

In case of true precocious puberty about 90 % cases are idiopathic and 10 % cases are due to organic brain diseases including brain tumors (hypothalamic gliomas, astrocytoma, ependymoma, germinomas and hamartomas), encephalities, meningitis, hydrocephalous, head injury, tuberous sclerosis and neurofibromatosis.¹⁵

In this case the precocious puberty was due to organic brain disease, CT shows intra-cranial SOL in right fronto-parietal region (brain tumor).

In a series of more than 200 patients evaluate at a single medical school- CPP occur 5 times more in girl than boy. Idiopathic CPP occurred 8 times more often. Here the case was central precocious puberty.¹⁶

In girl the first and most obvious sign of early puberty is breast enlargement, which may initially be unilateral. Pubic and axillary hair may appear before, at about the same time or well after the appearance of breast tissue. Menarche is a late event and doesn't usually occur until 2 to 3 years after onset of breast enlargement.¹⁷ In our case the baby was present with breast enlargement and fine pubic hair, H/O starting menarche at the age of 3 yrs, cycle was regular but sometime flow was heavy. Child became lethargic during that period.

The onset of puberty is normally triggered by the hypothalamus. It signals the pituitary gland to release hormone that stimulate ovaries in girls and testicle in boys to make sex hormone. Sometime precocious puberty stems from a structural problem in the brain such as tumor) or problem in the ovaries or thyroid gland that triggered the onset of puberty ahead of schedule. In about 5 % of the boys precocious puberty is inherited but less than 1 % of girls have inherited the condition.¹⁸

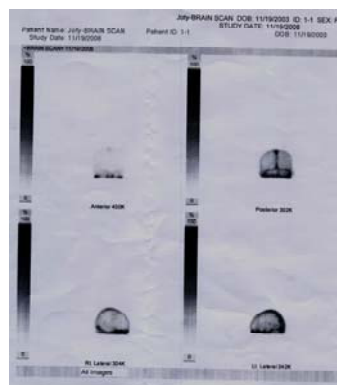In our case there was no family history of such type of problem, she suffered from structural brain problem.

Ultrasound scanning of the adrenals and ovaries, CT of the adrenals may be indicated to confirm clinical suspicious.¹⁹ CNS image studies of these otherwise healthy 6-8 years old girls usually revel no structural abnormality. In 2003 a study of 200 girls in France found abnormal brain image

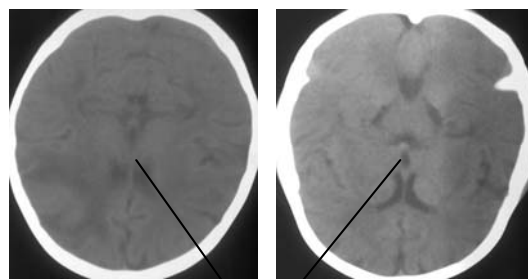
findings in 2% girls whose onset of puberty was between age 6-8 years and in 20% of girls whose onset of puberty was before 6 yrs²⁰. In 2003 a smaller study from the UK reported abnormal findings in 15% of 67 girls.²¹ CNS abnormality associated with precocious puberty includes the followings-

1. Tumor (e.g.- astrocytomas, gliomas, germ cell tumors secreting human chorionic gonadotropin [HCG]),
2. Hypothalamic hamartoma,
3. Acquired CNS injury caused by inflammation, surgery, trauma, radiation therapy or abscess.
4. Congenital anomalies (hydrocephalus, arachnoids cyst).²²

Here ultrasound of the child showed prominent and well developed ovaries and uterus, few small SOL in liver. CT scan of brain reveals brain tumor in right fronto-parietal lobe. MRI of brain and hormonal analysis were also done. Finally diagnosed as a case of CPP.



Picture –II Isotope Brain scan.



Picture- III – Brain CT (Right fronto-parietal lesion)

Conclusion

Once it is diagnosed the goal of treating precocious puberty is to halt or even reverse sexual development and stop the rapid growth and bone maturation. Depending upon the cause there are two approaches of treatment. –

- i) Treating the underlying cause or disease such as tumor.
- ii) Lowering the high levels of sex hormones with medication.²³

Usual treatment of precocious puberty has been administration of medroxy- progesterone acetate (100~200 mg I/M every 2 to 4 weeks).²⁴

Currently approved hormone treatment is with gonadotropin releasing hormone agonist. In some cases, treatment of an underlying health problem can stop the precocious puberty from progressing.²⁵

In this case the patient's was two poor to continue the medications and therapy. Now a days with development of diagnostic procedure and invention new drugs it is much more easier then past to diagnosed and treated the such type of complicated health problems.

References

- 1, 3. David Muram MD, 1987; Pediatric & Adolescent Gynecology, Martine L Pernal & Ralph Benson, Current Obstetric & Gynecology Diagnosis and Treatment, 6th edition, Prentice – Hall international, Inc, USA, 31.771-72.
- 2, 6, 10, 18, 23, 25
http://kidshealth.org/parent/medical/sexual/precocious_us.html, Steven Dowshen, MD.01-08-2008.
4. [http:// www nichd.nih.gov/health/topics/precocious puberty.cfm](http://www.nichd.nih.gov/health/topics/precocious/puberty.cfm) 15-01-2007.
- 5,8,13,14,16,17 and 22.
http://emedicine.medscape.com/article/9240002-Overview_precocious_puberty, Paul-B-Kaplowitz,MD, 28-09-2007.
7. [http:// en.wikipedia.org/wiki/precocious_puberty](http://en.wikipedia.org/wiki/precocious_puberty), 21-02-2009.
9. Parent AS, Teliman G, Juul, et al, The timing of normal puberty and the age limits of sexual precocity: Variations around the world, secular trends and changes after migration, *Endocr Rev*, Oct, 2003; 24(5): 668-93.
11. Herman –Giddens ME, Slora EJ, Wasserman RC, et al, Secondary sexual characteristics and menses in young girls seen in office practice: A study from the pediatric research in office setting network. *Paediatrics Ap*, 1997; 99(4): 505-12.
- 12, 15,19,24,25. Robert,W,Rebar, The ovaries , James. B.Wyngaaden & Lloyd.H.Smith, Jr., MD. CECIL Text Book of Medicine, WB Saunders international edition, Harcourt Brace Javanovica.Inc, 1988; XVI: 237, 1428-9.
20. Chalumeau M, Chemaitilly W, Trivin C, et al, Central Precocious puberty in girls: An evidence –based diagnosis tree to predict central nervous system abnormality *pediatrics*, Jan 2002; 109(1): 61-7[Medicine].
21. Ng SM, Kumar Y, Cody D, et al. Cranial MRI Scans are indicated in all girls with central precocious puberty, *Arach Dis Child*, May 2003; 88(5): 414-8.

All correspondence to:
M Kabiruzzaman Shah
Assistant Professor
CNMU, Rajshahi