



Review Article

Andropause: The Male Climacterium

M Rizaul Kabir¹, M A Al-Amin², M Afsar Siddique³

Abstract

Andropause is a clinical condition characterized by a partial deficiency of androgens in blood and/or a decreased sensitivity in target tissues. This state of hypogonadism leads to a decline of physical energy, an altered state of well-being, a sexual dysfunction and various metabolic alterations. These issues may have deleterious effects on muscle mass, bone density, lipid profile and eventually cognitive functions. The diagnosis of andropause depends mainly on clinical features and laboratory investigations. Awareness about this condition may help to diagnosis it earlier.

TAJ 2008; 21(1): 87-92

Introduction

Andropause or Partial androgen deficiency in the aging male (PADAM) is the male climacterium in men around the age of 50yrs. As beginning of menopause ends the reproductive life of female, the male reproductivity also become meager with the emergence of Andropause.

In practice, there are patients who are middle aged happily married men, have children, gradually lose interest in sex, have not made sex with his wife for months. Some of these patients develop a kind of sexual laziness noticeable in their relationship with wife. Some others may have some erections but the basic problem is the loss of libido. Psychological fatigue, a loss of interest in sex, a loss of attraction towards wife, depression, anxiety & stress at work or at home are the accompanying features of these patients. Some of these patients lose interest in works, has less initiative ness and low self esteem. These are the patients of Andropause- the male climacterium.

Anatomy of penis

The anatomy of the male genitalia is very complex; however, for the purposes of discussion of erectile function, the corpora cavernosa are the main structures. These two columns of erectile tissue in the shaft of the penis are surrounded by the tunica albuginea and separated by an incompetent septum composed of fibers. The fibers interweave with the inner layer of the tunica albuginea. A third erectile body, the corpus spongiosum, is located on the ventrum of the corpora cavernosa and contains the urethra.

The sensation of the glans penis is mediated via the dorsal nerves of the penis, which are branches of the pudendal nerve. Erectile function is controlled both parasympathetically and sympathetically. The parasympathetic input is excitatory in function. The parasympathetic nerves adjacent to the prostate gland (nervi erigentes) coalesce in the hilum of the penis and penetrate into the corpora cavernosa. The sympathetic input is an extension of the thoracolumbar plexus and is inhibitory in function.

¹ Assistant Professor, Department of Dermatology, Rajshahi Medical College, Rajshahi.

² Professor & Head, Department of Dermatology, Rajshahi Medical College, Rajshahi.

³ Assistant Professor, Department of Dermatology, Rangpur Medical College, Rangpur.

Arterial inflow

To the deep structures of the penis is dependent on the deep internal pudendal vessels via the common penile arteries. These branches provide vascularity to the deep structures as well as the glans penis. The venous outflow from the penis is a bit more

complex and has been divided into three separate systems: (1) superficial, consisting of the superficial veins, (2) intermediate, consisting of the emissary, circumflex, and deep dorsal veins, and (3) deep, consisting of the hilar and cavernosal veins.

Sexual function in the male Consists of the following FIVE phases

- 1. Libido ❑ The psychogenic preparatory phase which precedes and accompanies erection and is termed libido.
- 2. Erection ❑ Erection itself, which is a parasympathetic reflex passing through the nerves erigens.
- 3. Ejaculation ❑ The following ejaculation mediated by the hypogastric nerve.
- 4. Orgasm ❑ Orgasm, which like libido is a Cortical process and.
- 5. Detumescence ❑ During which blood flows away from erectile tissue and the erection reflex is inhibited.

Dysfunction of the first four phases Constitutes diminished Potency in the broadest sense of the term.

efferent Spermatic cord to retrograde, ejaculation the reflex are remaining normal.

Ejaculatory failure (aspermia / or hypospermia) on the other hand may be due to occlusion of the

Impotence

usually means complete erectile dysfunction which is sometimes associated with loss of libido.

Mechanism of Sexual functions and their disorders

Phase	Mechanism	Dysfunction
1. Libido	P Psychogenic	Loss of libido
2. Erection	V(Arterioles of the erectile tissues) N (Parasymp)	1. Partial Erectile dysfunction (e.g. also) due to malformation of penis) 2. Complete Erectile dysfunction (impotence) 3. Painful Erection
3. Ejaculation	M N (motor)	1. Premature ejaculation 2. Retrograde ejaculation 3. No ejaculation (in lesions of spinal cord) 4. Painful ejaculation (in prostatitis)
4. Orgasm	P (Psychogenic)	Psychogenic Anorgasm
5. Detumescence	V, n	1. Priapism

- m ➤ muscular (bulbocavernose muscle.)
- n ➤ Neurological (Spinal cord, Peripheral nerves)
 - motor
 - Parasympathetic (Cortical)
 - Vascular (arterioles of erectile tissues)

Physiology of an erection

The basic physiology of an erection can be described by a simplistic model that presumes a single lacunar space as the entire corpora. The helicine artery drains into the lacunar space. The lacunar space is bounded by the intracavernosal smooth musculature and lined with endothelial cells. Exiting from the lacunar space are one or more venules that coalesce to become a subtunical venule, which then drains through the tunica albuginea as the emissary vein.

When the penis is flaccid, the intralacunar smooth muscle is in a contracted state; the tonus is maintained by norepinephrine (alpha stimulation). With stimulation of the cavernous nerve (alpha blockade), active relaxation of the cavernosal smooth muscle occurs. The lacunar space and the helicine arteries dilate, the subtunical venules are compressed physically and possibly neurologically, and the emissary veins are constricted physically. In short, the lacunar space becomes a large vascular "sink" into which blood

rapidly flows and becomes trapped, thereby elevating the pressure within the lacunar space to that of mean arterial pressure.

Relaxation of cavernosal smooth muscle is initiated by the following neurotransmitters: (1) acetylcholine, (2) vasoactive intestinal polypeptide (VIP) via the VIP-ergic system, (3) prostaglandin via the prostacyclin system, and (4) nitric oxide

Male sexual activity is a very complex holistic function of human body which is the subject matter of Andrology- 'the science of male reproduction'. The main androgenic hormone- the testosterone orchestrate the main role here like 'Selim in Mughal-E-Azam'.

Testosterone Production: Testosterone, the main androgenic hormone is synthesized and secreted by Leydig cells of the testes. This production is regulated by a negative feedback system involving the hypothalamus and the pituitary. The testes produce 0.24 μ mol/day of testosterone.

Testosterone is metabolized to dihydrotestosterone (DHT) by 5α -reductase. Most of the circulating testosterone (80%) is bound to sex hormone binding globulin (SHBG). The remaining is bound to albumin and other plasma-proteins. Only 2% of total testosterone is free and is bioactive. There is a diurnal variation in serum testosterone level in young men, which is highest at about 08.00 hours and lowest in the late afternoon.⁵ Testosterone secretion begins in utero with a peak in the male fetus at 12 weeks. The second peak occurs after birth. From this time until puberty, the level is low and equal to the female. At puberty, there is a pulsatile secretion of luteinising hormone (LH) leading to maturity of the Leydig cell resulting in increased testosterone synthesis.

Testosterone and its target organs: Testosterone affects many bodily systems, has its target organs like brain, skin haematopoiesis, calcium homeostasis, bone mineralization, lipid and carbohydrate metabolism, muscle trophicity, male sexual organs and sexual activity.

i) Brain: Testosterone has specific functions on brain. It affects cognitive functions like libido and

mood. In a recent study, it has shown that testosterone improves positive mood parameters like friendliness, sense of well being and energy and decreases the negative parameters like anger, sadness, nervousness and irritability.

In another earlier study, it was observed that hypogonadal men suffered more in depression, anger, fatigue and confusion than did normal men. Clinicians agreed on this point that improvement in mood might be related with improvement in sexual functioning.

2) Skin : Skin - the organ of beauty and self-gratification' is affected by testosterone. The normal hair growth, sebum production and male pattern baldness are due to optimum functioning of testosterone. Body hairs fall and sebum production decreases causing xerosis in patients with lower testosterone level.

3) Muscle trophicity: several studies in elderly men have evaluated the effect of testosterone on body fat, muscle mass and strength. It was shown that testosterone administration increases muscle protein synthesis, muscle strength and mRNA concentration of intramuscular somatomedin-1 in elderly men. In hypogonadal elderly men, there occurs decrement in muscle mass and strength and increment in central body fat.

Hair: Testosterone acts in the synthesis of proteins in hairs. These proteins act as building blocks in anabolism.

Kidney: In kidney, Testosterone stimulates the production of Erythropoietin.

Bone and Bone marrow: Testosterone plays an important role in maintaining bone mass density. It accelerates linear growth of bones and closure of epiphyses. Testosterone also stimulates the stem cells in proper functioning of bones.

Hypogonadism is a well-established cause for male osteoporosis. Vertebral bone loss in men (aged 30 to 80yrs) rates 1.2 to 2% per year. The hip fracture rate in men increases dramatically after the age of 60yrs and doubles with each decade thereafter.

Male sexual function: Testosterone is the main sexual hormone of human body. It is responsible for normal growth and functions of penis, testes and prostate gland. Testosterone is also responsible for normal spermatogenesis, spontaneous erections, normal libido and ejaculations, Kwan et al reported that men's erectile events per day, mean duration of events, and penile rigidity, arousal, sexual desire, orgasm and satisfaction depends on testosterone replacement in elderly.

Haematopoiesis: Over the last 3 decades, there are numerous studies showing the beneficial effect of androgens in the treatment of primary anemia and bone-marrow failures. It is a general observation that hemoglobin concentration increases in boys at puberty along with an increase in testosterone level. Adult man also have higher haemoglobin and red cell counts than to adult woman. With age haemoglobin and haematocrit (HcT) values decline and mild anemia is prevalent in elderly man.

It would be clear from the above discussion that the testosterone has many bodily functions on its target organs like brain, skin, liver, kidney, haematopoietic systems, calcium homeostasis, bone mineralization, lipid and carbohydrate metabolism, muscle trophicity, male sexual organs and sexual activity. With the advancement of age and gradual decline of testosterone, there appears clinical features in some of the aged males which are related with impairment of androgenic activity of testosterone in its target organs. Considering all the points in view, Andropause was defined by international society for the study of the ageing male (ISSAM) in December' 1997 as follows:

Consensus definition of Andropause Adopted by ISSAM IN December, 1997

"Andropause is a Clinical Condition Characterized by a Partial deficiency of Androgens in blood and/or a decreased genomic Sensitivity in target tissues. This state of hypogonadism leads to a decline of physical energy, an altered state of well-

being, a sexual dysfunction and various metabolic alterations. These issues may have deleterious effects on muscle mass, bone density, lipid profile and eventually cognitive functions"

The following signs & symptoms of Andropause were observed and adopted by Tremblay & Morales on July 1998.

Signs & Symptoms of Andropause:

A. Vasomotor and Nervous Symptoms:

1. Hot flushes similar to those of menopause
2. Episodes of sweating
3. Insomnia
4. Nervousness

B. Mood disorders and Cognitive functions.

1. Irritability and lethargy
2. Decreased sense of well being
3. Lack of motivation
4. Low mental energy
5. Difficulties with short-term memory
6. Depressive symptoms
7. Low self esteem
8. Unusual fright

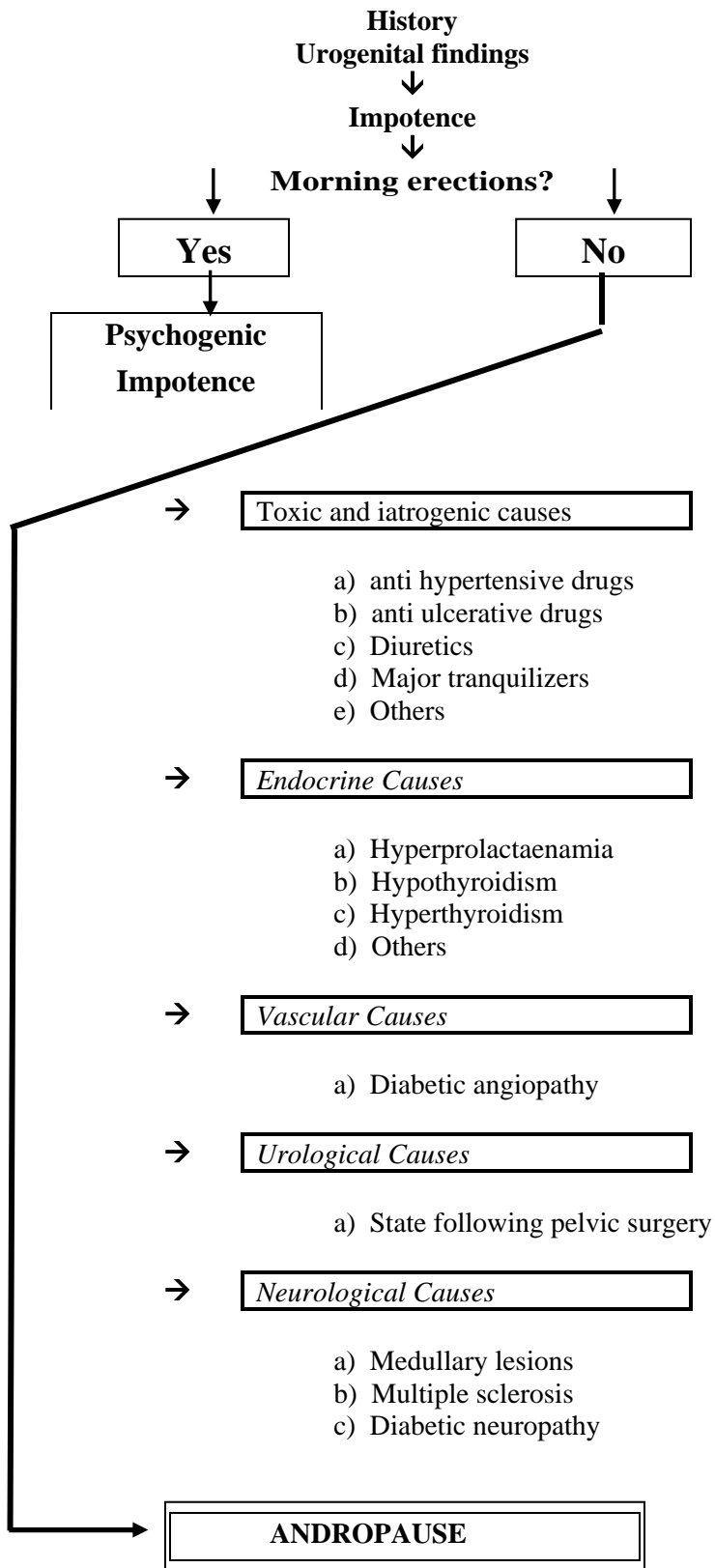
C. Masculinity / Virility

1. Decreased vigor and physical energy.
2. Diminished muscle mass and strength,
3. Loss of sexual body hair
4. Abdominal obesity

D. Sexuality.

1. Decreased interest or desire for sex.
2. Reduction of sexual activity
3. Poor erectile function
4. Limited quality of orgasm,
5. Weakness of ejaculation
6. Reduced volume of ejaculate

Diagnosis: The diagnosis of Andropause depends mainly on clinical features and laboratory investigations. The patient presents with the feature of impotence. The diagnosis must be much earlier if one follows the following diagnostic tree.



The Canadian Andropause Society Canada recommended the following treatment Schedule for a patient of Andropause.

Recommendation for Management of Andropause patients by Canadian Andropause Society, Canada.

1. Patients receiving Supplemental Testosterone therapy should have a clear indication for it, based on clinical symptoms and physical manifestations of hypogonadism.
2. Serum Testosterone level, haematocrit level, lipid profile, prostatic antigen (PSA) and other relevant investigation to done.
3. Digital rectal examinations for Testosterone replacement therapy.

4. Prostatic cancer, Breast cancer and sleep Apnea are Absolute contraindications for Testosterone replacement therapy.
5. Testosterone replacement therapy should be continued on a long-term basis.
6. initially, patients should have a flow-up after three months with prior attention to
 - a. Critical assessment of response to therapy
 - b. Digital rectal examination
 - c. PSA (> 4ng / ml, refd. to urologist)

Then the patient should be followed-up on six-monthly basis. Currently available Testosterone preparation-

Administration	Generic name	Recommended Schedule
Inject able	Testosterone cypionate	100-150mg IM every 02 wks
	Testosterone enanthate	100-150mg IM every 02 wks.
Oral	Testosterone undecanoate	160-200mg Per day
Dermal	Testosterone patches	12.2mg Per day

Conclusion

Andropause is relatively common but commonly overlooked clinical condition. Early diagnosis and treatment improves the sense of well-being, sexual function and prevent the metabolic, skeletal, and other complications of andropause.

References

1. Oddens BJ, Vermeulen A, Androgens and the aging male, (proceedings of a Workshop organized by the International Health Foundation) Geneva, December 1995.
2. The medical Post, February 10, 1998, Organon, The Netherlands.
3. Tremblay RR, Morales A, A Canadian practice recommendation for screening, Monitoring and treating men affected by andropause or partial androgen deficiency. The Aging Male, Vol. 1 No.3 July 1998, 1: 213 – 218.
4. Aboseif SR, Breza J, Lue TF, et al. Penile venous drainage in erectile dysfunction: anatomical,

radiological and functional considerations. Br J Urol 1989; 64(2): 183-90.

5. Carrier S, Brock G, Kour NW, et al. Pathophysiology of erectile dysfunction. Urology 1993; 42(4):468-81.
6. Giuliano FA, Rampin O, Benoit G, et al. Neural control of penile erection. Urol Clin North Am 1995;22(4):747-66.
7. Hauri D, Spycher M, Bruhlmann W. Erection and priapism: a new physiopathological concept. Urol Int 1983;38(3):138-45 .
8. Hellstrom WJ, Monga M, Wang R, et al. Penile erection in the primate: induction with nitric-oxide donors. J Urol 1994;151(6):1723-7 .
9. Krane RJ, Goldstein I, Saenz de Tejada I. Impotence. N Engl J Med 1989;321(24):1648-59 .
10. Breza J, Aboseif SR, Orvis BR, et al. Detailed anatomy of penile neurovascular structures: surgical significance. J Urol 1989;141(2):437-43 .
11. Lue TF, Tanagho EA. Physiology of erection and pharmacological management of impotence. J Urol 1987; 137(5):829-36.

All correspondence to:
 M Rizaul Kabir
 Assistant Professor
 Department of Dermatology
 Rajshahi Medical College, Rajshahi.