



Case Report

Primary Segmental Colonic Tuberculosis: A Case Report

M M Haque¹, A B Siddique², S M Badruddoza³, M R Amin⁴,
M G Rahman⁵, M Z Hasan⁶, M J Abedin⁶, M Takbirul Islam⁴

Abstract

Tuberculosis is known to involve any segment of gastrointestinal tract. While tuberculosis of the small bowel is common, isolated primary tuberculosis of the large bowel is quite uncommon. We report two cases of isolated colonic tuberculosis, successfully treated with primary resection.

TAJ 2004; 17(1) : 52-54

Introduction

Intestinal tuberculosis is a diagnostic challenge, especially when active pulmonary infection is absent. It may mimic many other abdominal diseases. Tuberculosis of colon forms only 3 to 4% of intestinal tuberculosis. Tuberculosis of the colon tends to be segmental and usually obstructive symptoms dominate. However the diagnostic challenge is highly accentuated when isolated colonic segments are involved with tuberculosis. Here we present two cases of primary colonic tuberculosis.

Case 1

A 30 years old housewife was admitted into surgery unit, RMCH in November 2004 with complaints of pain in the left upper and mid abdomen for two years, intermittent abdominal distension, low grade fever, alteration of the bowel habit, anorexia and weight loss for 1 year. There was no history of pulmonary tuberculosis or contact with a known to have tuberculosis.

On examination the patient was found to be anaemic and dehydrated. An ill-defined, smooth, non-tender, freely mobile, intra-abdominal mass measuring approximately 10cm x 8cm was detected in the left hypochondriac and lumbar region. With a clinical suspicion of carcinoma of sigmoid colon, the patient was investigated. The barium enema X-ray of colon showed stricture of the large bowel at splenic flexure.

At operation a firm mass at about 7.5-cm x 5-cm was found in the wall of the splenic flexure of colon. The small bowel and the surrounding structures were entirely free of disease.

A left hemicolectomy was carried out and continuity was established by colocolic anastomosis. The excised specimen showed one stricture with thickened wall. There was minimal, superficial ulceration of the mucosa at the stricture site. Histopathological diagnosis was tuberculosis of the colon (Fig. 1).

¹ Associate Professor, Department of Surgery, Rajshahi Medical College, Rajshahi.

² Assistant Professor, Department of Surgery, Rajshahi Medical College, Rajshahi .

³ Associate Professor, Department of Pathology, Rajshahi Medical College, Rajshahi .

⁴ Intern doctor, Department of Surgery, Rajshahi Medical College Hospital, Rajshahi .

⁵ Assistant Registrar, Department of Surgery, Rajshahi Medical College Hospital, Rajshahi .

⁶ Indoor Medical Officer, Department of Surgery, Rajshahi Medical College Hospital, Rajshahi .

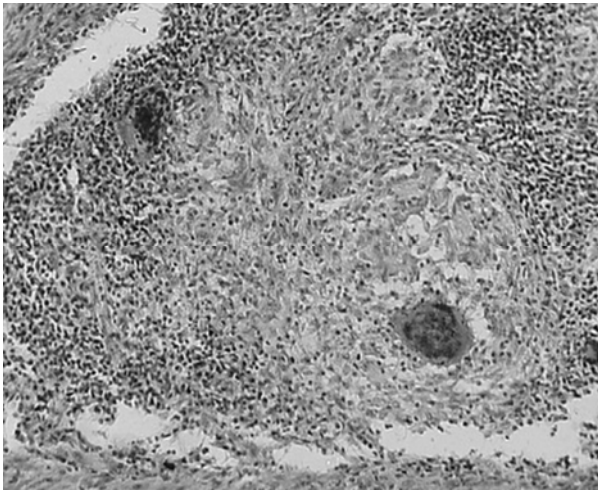


Fig. 1: Photomicrograph of colonic tuberculosis (Case-1)

Postoperative recovery was uneventful. On discharge the patient was put on multiple drug anti-tuberculous treatment (Rifampicin, INH, Ethambutol, Pyrazinamide).

Case 2

A 34 years old male patient was admitted into surgery unit, RMCH on 1st December 2004 with the complaints of low-grade fever with night sweating and gradual weight loss for 3 years, pain in the lower right abdomen for 3 months. The patient complained of constipation, abdominal distension and vomiting for 2 days. There was no history of anorexia, alteration of bowel habit or bleeding per rectum. On examination there was a mass in the right hypochondriac and lumbar region with signs of intestinal obstruction. There was no history of pulmonary tuberculosis or contact with known to have tuberculosis.

The patient was subjected to colonoscopy two weeks back in another institution. Colonoscopy revealed a large irregular growth in the hepatic flexure of colon (Fig. 2). Biopsy material was taken endoscopically and it was consistent with tuberculosis histologically. The patient had been treated with antituberculous regimen for last two weeks.

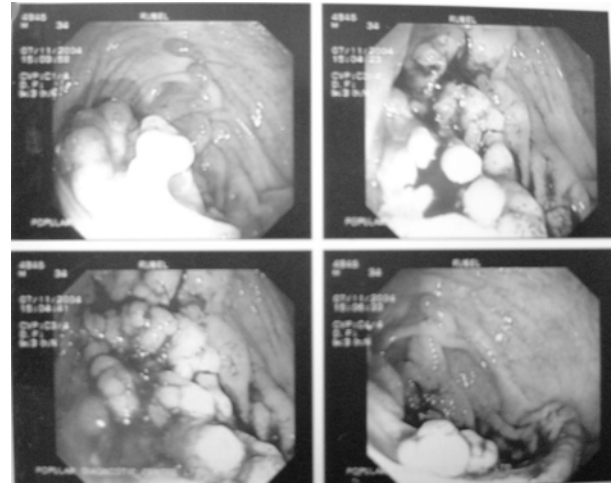


Fig. 2: Endoscopic photograph of colonic tuberculosis (Case-2)

After resuscitation and preparation the patient had been subjected to emergency operation. On laparotomy a large growth was seen in the hepatic flexure of colon. Right hemicolectomy was done. Resected specimen was sent for histopathological examination. The colonic lesion was found to be tuberculosis. There was no such lesion in the ileum on histopathology. Postoperative period was uneventful. The patient was placed on antitubercular drugs and had been discharged home. Patient had gained 5 kg of weight after 5 months of follow up.

Discussion

Tuberculosis of the ileocaecal region is a common entity ⁽²⁾. The apparent affinity of the tubercle bacillus for lymphoid tissue and areas of physiologic stasis facilitating prolong contact between the bacilli and the mucosa may be the reason for ileum and caecum being the most common sites of the disease. But isolated tuberculous lesions of the colon without involvement of the small bowel are rare ⁽¹⁾. About 3% of all patients with abdominal tuberculosis have isolated colonic tuberculosis ⁽³⁾. However, our cases had extensive colonic tuberculosis without any pulmonary lesion. Tuberculosis of the colon tends to be segmental and obstructive symptoms dominate ⁽⁴⁾. Both the forms, ulcerative and hyperplastics may be seen in the colon. Ulcerative lesions give rise to fibrous strictures. The patients complains of abdominal pain, diarrhoea,

intestinal colic and later on presents with signs of intestinal obstruction⁽¹⁾. Our first patient presented with alternating diarrhoea and costipation and probable pre-operative diagnosis was malignant lesion of the sigmoid colon. This case illustrates that the diagnosis of colonic tuberculosis requires a high index of suspicion. Our second patient presented as with obstructive lesion.

The diagnosis of isolated colonic tuberculosis can be quite difficult since there are no specific clinical presentations. One of our patients had presented with right upper quadrant pain and signs of intestinal obstruction.

Resection is the treatment of choice since hyperplastic lesions rarely respond to chemotherapy⁽¹⁾. For isolated tuberculosis of the colon, local colonic resection is adequate. But in our first case we performed a left Hemicolectomy with apprehension of carcinoma colon.

In the absence of pulmonary or ileocecal involvement, colonic tuberculosis may be difficult to differentiate from neoplasm or Crohn's disease by symptomatic and radiological means. Colonoscopy and biopsy can, however, establish the diagnosis and prevent operative intervention⁽⁵⁾. Breiter and Hajjar reported that antituberculous chemotherapy produced remarkable symptomatic, radiographic and endoscopic improvements and averted exploratory laparotomy⁽⁵⁾. This report emphasized the importance of colonoscopic biopsy as a useful diagnostic modality in Colonic tuberculosis. In our second case after histological confirmation of diagnosis with colonoscopic biopsy antituberculous treatment had been started. But the patient failed to respond and developed acute intestinal obstruction due to post-chemotherapeutic fibrosis. We had to operate the patient on an emergency basis.

Tuberculosis of the colon should be suspected in patients suffering from chronic abdominal pain

and weight loss^(6,7). Both the patients had the history of some degree of abdominal pain and weight loss. However this is not possible to differentiate from malignant lesion of colon.

Conclusion

Primary segmental colonic tuberculosis is a rare condition and poses great difficulty in diagnosis. High index of suspicion, supported by radiological and colonoscopic investigations may lead to a diagnosis of colonic tuberculosis. However, laparotomy followed by tissue biopsy may only lead to a definitive diagnosis. Segmental resection with colocolic anastomosis followed by antitubercular chemotherapy is the standard treatment of choice in colonic tuberculosis.

References

1. Deodhar SD, Pated VC, Bharucha MA, Vora IN. Primary tuberculosis of the large bowel (a case report). *J Postgrad Med* 1986; 32:161-2,160A.
2. Singh V, Kumar P, Kamal J, et al. Clinicocolonos-copic profile of colonic tuberculosis. *Am J Gastroenterology* 1996; 91:565-68.
3. Palmer KB, Patil DH, Basran GS, Riordion JF, Silk DB. Abdominal tuberculosis in urban Britain. A common disease. *Gut* 1985; 26:1296-1305.
4. Sane SY, Nimbkar SA. Carcinoma colon with tuberculosis. *J Postgrad Med* 1980; 26:199-200.
5. Breiter JR, Hajjar JJ. Segmental tuberculosis of the colon diagnosed by colonoscopy. *Am J Gastroenterology* 1981; 76:369-73.
6. Marshall JB. Tuberculosis of the gastrointestinal tract and peritoneum. *Am J Gastroenterology* 1993; 88:989-99.
7. Villanueva Saenz E, Martinez Hernandez Magro P, Fernando Alvarez-Tostado Fernandez J, Valdes Ovalle M. Colonic tuberculosis. *Dig Dis Sci.* 2002; Sep; 47 (9):2045-8.

All correspondence to:
M. Manzurul Haque
Associate Professor,
Department of Surgery,
Rajshahi Medical College,
Rajshahi.