



Case Report

A Case of Kikuchi's Disease Presenting with Fever and Lymphadenopathy

Khan MMR¹, M K Rahman¹, P M Basak², K Khanam³, B K Pal⁴
M J Islam⁵, F A Khan⁵, M M Newaz⁵, H S Das⁶

Abstract

Kikuchi's disease is a rare, benign, self-limiting disorder, characterized clinically by fever and regional lymphadenopathy. Histopathologic features of lymph nodes in Kikuchi's disease are characteristic and permit differentiation of this benign condition from lymphomas, systemic lupus erythematosus and infectious lymphadenopathies. We report a female patient presenting with fever and tender cervical lymphadenopathy. An excisional biopsy of the lymph node revealed lymphadenitis, consistent with Kikuchi's disease.

TAJ 2012; 25: 81-83

Introduction

Kikuchi's disease was initially described in Japan.^{1,2} It mainly affects young female and is clinically characterised by tender regional lymphadenopathy, fever, and occasional systemic involvement. The lymphadenitis in Kikuchi's disease reveals characteristic histopathologic features of coagulative necrosis and karyorrhectic debris.³ Differential diagnosis includes lymphoma and lymphadenitis associated with systemic lupus erythematosus (SLE), and certain infectious aetiologies, which share similar clinicomorphologic features.⁴ Kikuchi's disease is a rare and possibly an under-diagnosed condition, with an excellent prognosis.

Case Report

Mrs. Shahana a 22- years old female hailing from Naogaon presented with fever, malaise, anorexia,

and swelling in neck and face for 4 weeks duration. Her other symptoms included headache, nausea, vomiting and sore throat. There was no history of a cough, chest pain or joint symptoms. She had been well until the onset of her current illness. Personal and family history was unremarkable.

Examination revealed a temperature of 102°F, pulse 108 beats per minute, and blood pressure of 110/70 mm Hg. There were multiple, tender, mobile lymph nodes in the both posterior cervical and submandibular regions, with the largest node measuring approximately 3 cm x 4 cm. There were no lymph nodes elsewhere and she had no hepatosplenomegaly. The rest of the clinical examination was unremarkable.

Laboratory work up revealed a haemoglobin of 10.4 g/dl, white blood cell count of 4000/ μ l,

¹ Associate Professor, Department of Medicine, Rajshahi Medical College, Rajshahi.

² Assistant Professor, Department of Medicine, Rajshahi Medical College, Rajshahi.

³ Assistant Professor, Department of Pathology, Rajshahi Medical College, Rajshahi.

⁴ Medical Officer, Department of Nephrology, Comilla Medical College Hospital, Comilla.

⁵ Assistant Register & IMO, Department of Medicine, Rajshahi Medical College Hospital, Rajshahi.

⁶ Indoor Medical Officer, Department of Paediatrics, Rajshahi Medical College Hospital, Rajshahi.

platelet count of 3,00,000/ μ L), ESR-100 mm 1st hour. Inflammatory markers were elevated with C-reactive Protein 12mg/L. Patient had normal values of urea, creatinine and urinalysis. Antinuclear factor, double stranded DNA were negative. Chest X-ray was normal and Mantoux test showed no induration or erythema at 48 hours. Ultrasound abdomen did not reveal any abnormality.

Excisional biopsy of the cervical lymph node was performed and a histopathologic examination revealed -“Irregularly demarcated pale zone composed of necrosed area with karyorrhectic debris and reactive

lymphoid tissue. It also reveals plasma cells and absence of neutrophils. No malignant cells were seen. These findings were consistent with a histological diagnosis of Kikuchi’s Lymphadenitis.”

Based on a clinico-pathologic correlation, a diagnosis of Kikuchi’s disease was made and patient was treated with only symptomatic treatment by paracetamol 500 mg three times daily, fexofenadin 120 mg twice daily and Domperidon 10 mg three times daily. Patient was discharged from the hospital and advised to come for follow up after 3 weeks.

Her temperature settled after 2 weeks and size of lymph nodes return to normal within 3 weeks.

Discussion

Kikuchi’s disease also known as histiocytic necrotising lymphadenitis was originally reported in young Japanese females in 1972, by Kikuchi¹ and Fujimoto and colleagues.² The classic findings of Kikuchi’s disease are lymphadenopathy and fever.³ Kikuchi’s disease affects all ethnic groups with a higher prevalence among the Japanese and other Asian people Most of the patients are young adults, below the age of 40 years. In general, a female preponderance has been reported with a female to male ratio of 4:1.³ The onset of Kikuchi’s disease is usually acute or subacute with fever and regional lymphadenopathy which is mostly cervical; in a previously healthy young adult.³⁻⁵



Figure.1

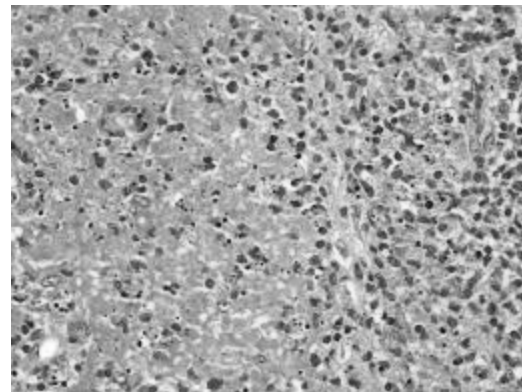


Figure.2

Fig.1: The Patient

Figure.2: Irregularly demarcated pale zone composed of necrosed area with karyorrhectic debris and reactive lymphoid tissue. It also reveals plasma cells and absence of neutrophils. No malignant cells.

Enlarged lymph nodes range from 0.5 to 4 cm in size and are tender and painful. Other anatomic sites of lymphadenopathy are involved in 2% to 40% of patients. Involvement of mediastinal, peritoneal and retroperitoneal regions is uncommon. Less frequent symptoms such as fatigue, arthralgia, joint pains, nausea, vomiting, anorexia, and sore throat have been reported in 2-7% of patients. Weight loss and night sweats, though rare, have also been observed.⁹ Extra-nodal involvement in Kikuchi’s disease is rare and has been documented in skin, bone marrow, myocardium and central nervous system.^{3, 4}

Cutaneous manifestations, mostly non-specific and variable in nature, have been reported in 16-40% of patients with Kikuchi's disease.⁷ In a recent review the most common manifestation was a rash, followed by erythematous macules and patches, erythematous papules and plaques and erythematous macules and papules.⁷

Apart from these, malar erythema, oral ulcers, pruritus, alopecia, photosensitivity, conjunctival injection and scaling have also been observed in a smaller number of patients. Hepatosplenomegaly is relatively common; while neurologic involvement has been documented in form of isolated case reports of aseptic meningitis, acute cerebellar ataxia, and raised intracranial tension secondary to cervical venous obstruction.⁶ Systemic symptoms are found more frequently in patients with extra nodal involvement. Various laboratory abnormalities that have been reported include leucopenia, elevated erythrocyte sedimentation rate, anaemia, elevated aminotransferases, elevated lactate dehydrogenase and thrombocytopenia. Anti nuclear antibody (ANA) is positive in about 7% of patients.^{6,7} Diagnosis of Kikuchi's disease is based on histopathologic examination. The histologic differential diagnosis of Kikuchi's disease includes lymphadenitis associated with systemic lupus erythematosus, lymphoid malignancies, infections like tuberculosis, infectious mononucleosis, syphilis and rarely sarcoidosis and adenocarcinoma. The course and treatment of Kikuchi's disease differs dramatically from these disorders, hence they should be excluded before a diagnosis of Kikuchi's disease is made.

Recognition of Kikuchi's disease is thus crucial and it merits active consideration especially in young patients with cervical lymphadenopathy and fever.

References

1. Kikuchi M. Lymphadenitis showing focal reticulum cell hyperplasia with nuclear debris and phagocytosis. *Acta Hematol Jpn* 1972; 35: 379-380.
2. Fujimoto Y, Kozima Y, Hamaguchi K. Cervical necrotizing lymphadenitis: a new clinicopathologic agent. *Naika* 1972; 20:920-927
3. Kuo TT. Kikuchi's disease (histiocytic necrotizing lymphadenitis). A clinicopathologic study of 79 cases with an analysis of histologic subtypes, immunohistology and DNA ploidy. *Am J Surg Pathol* 1995; 19:798-809.
4. Mathew LG, Cherian T, Srivastava VM, Raghupathy V. Histiocytic necrotizing lymphadenitis (Kikuchi's disease) with aseptic meningitis. *Indian Pediatr* 1998; 35:775-7
5. Dorfman RF, Berry GJ. Kikuchi's histiocytic necrotizing lymphadenitis: an analysis of 108 cases with emphasis on differential diagnosis. *Semin Diagn Pathol* 1985; 5:329-345.
6. Hutchinson CB, Wang E. Kikuchi-Fujimoto Disease. *Arch Pathol Lab Med* 2010; 134:289-293.
7. Bosch X, Guilabert A, Miquel R, Campo E. Enigmatic Kikuchi-Fujimoto disease: A comprehensive review. *Am J Clin Pathol* 2004; 122:141-152
8. Atwater AR, Longley BJ, Aughenbaugh WD. Kikuchi's disease: Case report and systematic review of cutaneous and histopathologic presentations. *J Am Acad Dermatol* 2008; 59:130-136
9. Chaitanya BN, Sindura C. Kikuchi's disease. *J Oral Maxillofac Pathol* 2010; 14:6-9
10. Hudnall SD. Kikuchi-Fujimoto Disease. Is Epstein-Barr virus the culprit? *Am J Clin Pathol* 2000; 113:761-764

All correspondence to
P M Basak
Assistant Professor
Department of Medicine
Rajshahi Medical College
Rajshahi, Bangladesh