



Case Report

A Case of Renal Cell Carcinoma (RCC) Presenting with Polycythemia and Stroke

I Mahmood¹, M K Rahman², M M Rahman Khan², M M H Chowdhury²,
A K M Shahabuddin³, P M Basak³, M A Hasan⁴, F Ahamed⁴

Abstract

We report a case of middle aged man who presented with stroke with right sided weakness. Later on, routine investigations reveal erythrocytosis on complete blood count and left renal mass on USG of abdomen. Further investigations correlate the above scenario with renal cell carcinoma.

TAJ 2009; 22(2): 248-250

Introduction

Renal cell carcinoma account for 90-95% of malignant neoplasm arising from the kidney. The incidence of renal cell carcinoma continues to rise. The male to female ratio is 2:1. Incidence peaks between the ages of 50-70yrs. Many environmental factors have been investigated as possible contributing causes, the strongest association is with cigarette smokes [account for 20-30%]. A spectrum of paraneoplastic syndrome has been associated with these malignancies including erythrocytosis, hypercalcaemia, nonmetastatic hepatic dysfunction and acquired dysfibrinogenemia. Erythrocytosis is noted at presentation in only about 3% of patient.

Case report

The patient named Md. Shahidul Islam, aged 48 yrs, married, muslim, businessman smoker, hypertensive, diabetic hailing from Charjhikra, Chorghat, Rajshahi has been suffering from weakness of right side of body for 6 months. At

the onset when he was gossiping on an evening, he suddenly felt fullness of head and weakness in his right side. The evolution of paresis of right side of body was completed within 6 hours. The patient complained of headache and vertigo at the beginning of the attack but neither he lost consciousness nor there had any difficulty in speech. The patient also said that the weakness was mostly marked in right upper limb. There was no history of fever, head injury, palpitation, chest pain, breathlessness.

On examination his lower palpebral conjunctiva was congested bilaterally. pulse-84/min, regular, BP-110/80 mm of Hg (on antihypertensive drug). The neurological examination reveals he is oriented properly, muscle tone was increased, muscle power is 4/5 in upper and lower limbs, tendon reflexes were exaggerated (right side). Cerebellar function tests, cranial nerves and sensory modalities were intact. There was no deviation of mouth in any side. The gait was

¹ Associate Professor, Department of Medicine, Rajshahi Medical College, Rajshahi.

² Assistant Professor, Department of Medicine, Rajshahi Medical College, Rajshahi.

³ Registrar, Department of Medicine, Rajshahi Medical College Hospital, Rajshahi.

⁴ Assistant Registrar, Department of Medicine, Rajshahi Medical College Hospital, Rajshahi.

normal. Fundoscopy was normal. Other systems reveal no abnormality.

On investigation, Hb-21.5gm/dl, ESR-01mm in 1st hour, RBC- 8.9×10^{12} , PCV-64%, MCV-72fl, MCH-29pg, MCHC-34gm/dl. PBF-Polycythemia with neutrophilic Leucocytosis, FBS-7.9mmol/l, PPBS-14.8mmol/l, CUS-nil, Urine RME-albumin-++, S.creatinine-1.1mmol/l, ECG-NAD, S.electrolyte-Na-136.7mmol/l, K-4.85 mmol/l, Cl-107.0 mmol/l, Lipid profile-Total cholesterol-101.0mg/dl, HDL-27.0mg/dl, LDL-44.0mg/dl, Triglyceride-149.0mg/dl, Thyroid function test-Normal, CXR-Normal, USG of whole abdomen-There is a multi-septated cystic structure, measuring about 8.2x7.5 cm seen in left hypochondriac region close to the upper pole of left kidney and spleen but separated from them. CT scan of brain-Left sided cerebral infarcts, CT scan of abdomen-Left renal neoplasm

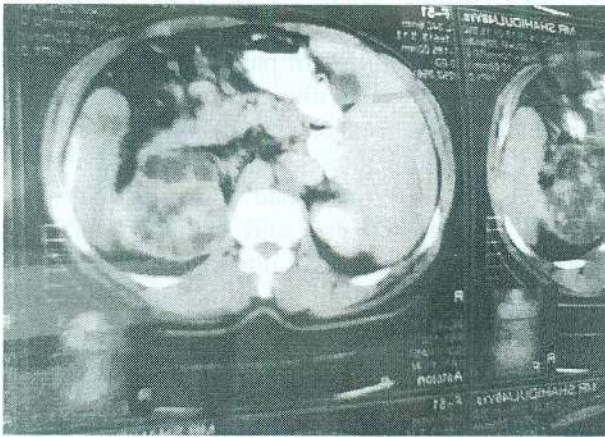


Fig. CT scan of abdomen shows left renal neoplasm.

Discussion

Polycythemia has been noted in 1%–8% of cases of RCC. In these patients, elevated serum red blood cell concentrations are believed to be mediated by erythropoietin (EPO), a glycoprotein that induces differentiation of erythrocyte colony-forming units in the bone marrow to promote red blood cell production. Under normal physiological conditions, EPO is produced by peritubular renal interstitial cells in response to local tissue hypoxia. However, in RCC, EPO production occurs in the tumor cells themselves. In fact, ectopic EPO production is found in 66% of RCC cases, making

this neoplasm the leading cause of ectopic EPO production. In addition to neoplastic cellular production of EPO, perineoplastic cells in RCC may also contribute to total EPO levels secondary to local tumor compression and resultant tissue hypoxia.

Although two thirds of RCC patients have elevated EPO levels, only 8% experience erythrocytosis. There is evidence to suggest that tumor cells may produce an inactive form of EPO. Polycythemia can cause arterial and venous cerebral thrombosis. The most likely mechanisms are hyperviscosity and impaired cerebral blood flow. Hyperviscosity occurs as a result of an increased packed cell volume, and cerebral blood flow has been found to decrease when red cell volume rises. The Framingham study indicates that the risk of stroke and the hemoglobin level are directly related. Moreover, an increased hematocrit has been associated with decreased reperfusion and increased infarct size following an acute ischemic stroke.

References

1. en-van der Kaa CA, van Lin EN, Osanto S, de Mulder PH (February 2008). "[Guideline 'Renal cell carcinoma']" (in Dutch; Flemish). *Ned Tijdschr Geneeskd* **152** (7): 376–80. PMID 18380384.
2. Rini BI, Rathmell WK, Godley P (May 2008). "Renal cell carcinoma". *Curr Opin Oncol* **20** (3): 300–6. doi:10.1097/CCO.0b013e3282f9782b (inactive 2009-06-26). PMID 18391630.
3. "Renal Carcinoma or hypernephroma". <http://www.renalcancer.com/>. Retrieved 2010-03-31.
4. Motzer RJ, Bander NH, Nanus DM (September 1996). "Renal-cell carcinoma". *N. Engl. J. Med.* **335** (12): 865–75. doi:10.1056/NEJM199609193351207. PMID 8778606. <http://content.nejm.org/cgi/pmidlookup?view=short&pmid=8778606&promo=ONFLNS19>.
5. "Renal Cell Cancer". <http://www.cancercompass.com/renal-cell-cancer-information/symptoms.html>. Retrieved 2010-03-31.
6. "Renal Cell Carcinoma". <http://www.omnimedicalsearch.com/conditions-diseases/renal-cell-carcinoma-symptoms.html>. Retrieved 2010-03-31.

7. "Kidney Cancer Symptoms (Renal Cell)". <http://cancer.about.com/od/kidneycancerrenalcell/a/kidneysymptoms.htm>. Retrieved 2010-03-31.
 8. Reuter VE, Presti JC (April 2000). "Contemporary approach to the classification of renal epithelial tumors". *Semin. Oncol.* **27** (2): 124-37. PMID 10768592.
 9. Cotran, Ramzi S.; Kumar, Vinay; Fausto, Nelson; Nelson Fausto; Robbins, Stanley L.; Abbas, Abul K. (2005). *Robbins and Cotran pathologic basis of disease*. St. Louis, Mo: Elsevier Saunders. pp. 1016. ISBN 0-7216-0187-1.
 10. van den Berg E, Storkel S . Kidney: Renal cell carcinoma. Atlas Genet Cytogenet Oncol Haematol. June 2003.
 11. American Cancer Society. Cancer facts & figures 2007. American Cancer Society; 2007.
 12. Lipworth L, Tarone RE, McLaughlin JK (December 2006). "The epidemiology of renal cell carcinoma". *J. Urol.* **176** (6 Pt 1): 2353-8. doi:10.1016/j.juro.2006.07.130. PMID 17085101.
 13. "Renal cell carcinoma". <http://www.nlm.nih.gov/medlineplus/ency/article/000516.htm/>. Retrieved 2010-03-31.
 14. "Symptoms of kidney cancer". http://www.medicinenet.com/kidney_cancer/page3.htm#symptoms/. Retrieved 2010-03-31.
 15. "Renal Cell Carcinoma". <http://www.omnimedicalsearch.com/conditions-diseases/renal-cell-carcinoma-tests-diagnosis.html>. Retrieved 2010-03-31.
- "Clear-cell Carcinoma, Hypernephroid Tumour, or Hypernephroma". <http://www.britannica.com/EBchecked/topic/497921/renal-carcinoma>. Retrieved 2010-03-31.

All correspondence to:
I Mahmood
 Associate Professor
 Department of Medicine
 Rajshahi Medical College, Rajshahi.