



Case Report

Primary Malignant Melanoma of the Tonsil : A Case Report

S M Badruddoza¹, S Naz²

Abstract

Malignant melanoma is a neoplasm of melanocytes. Primary malignant melanoma of the oronasal region is rare. When it does occur, it is difficult to manage, and the prognosis is not good. The current case was a 48 years old male patient who presented with history of sore throat, pain in left tonsillar region, hemoptysis with difficulty in swallowing. Clinical examination revealed a blackish ulcerated polypoid mass in the left palatine tonsil. Left sided tonsilectomy was done. Histopathological examination revealed primary malignant melanoma of the tonsil.

TAJ 2009; 22(2): 279-281

Introduction

Malignant melanoma is a neoplasm of melanocytes or of the cells that develop from melanocytes. Once consider an uncommon disease. The annual incidence of melanoma has increased dramatically over the last few decades¹. Primary malignant melanoma of the oronasal region is rare. Malignant melanoma of the head and neck is a rare and threatening disease. Approximately 20 % of melanomas occur in the head and neck region, with 6.3 % occurring in the mucous membranes. The incidence of oronasal malignant melanoma compared with the incidence of this tumor over the entire body is low². The first reported case of tonsillar metastasis from cutaneous malignant melanoma was in 1912 by Schmidt. Since then 24 cases of tonsil metastasis from a cutaneous malignant melanoma have been reported. The other reported sites include the nasopharynx, larynx, lip, pharyngeal wall, gingiva, nasal cavity, pyriform fossa, palate and maxillary sinus. The presenting commonest symptom was

pain followed by dysphagia¹. The reason for presenting this case are the fact of being a rare finding and the importance of early diagnosis as the oropharyngeal examination is not routinely done by clinicians. It should be necessary for early diagnosis of primary malignant melanoma of oronasal region. The prognosis of primary malignant melanoma of oronasal region is not good. So, early diagnosis and redical surgical management appear to offer the best hope of curing the disease.

Case study

The current case was a 48 years old male presented clinically with history of sore throat, pain in the left tonsillar region, difficulty in swallowing and hemoptysis. He first came to the ENT out patient department at Rajshahi Medical College Hospital. Clinical examination revealed a blackish ulcerated polypoid mass in the left palatine tonsil with bleeding from the left tonsillar region. Then he was admitted in the ENT

¹ Professor, Department of Pathology, Rajshahi Medical College, Rajshahi.

² Lecturer, Department of Pathology, Rajshahi Medical College, Rajshahi.

Department of Rajshahi Medical College Hospital and left sided tonsilectomy was done. Histopathological examination of resected biopsy specimen revealed malignant melanoma of the tonsil. The cellular atypia with enlarged cells containing hyperchromatic nuclei with prominent nucleoli are noted with melanin pigment in some of them.

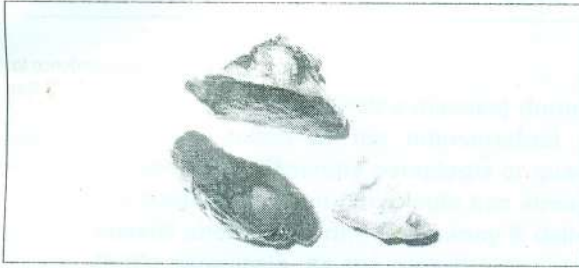


Fig 1 : Gross appearance of the tumour

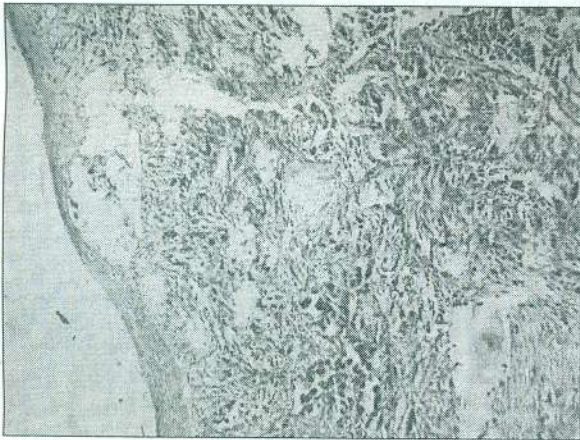


Fig 2: Histological section showing pleomorphic tumour cells with melanin pigments (H&E X 400)

Discussion

Melanoma is a tumor caused by the proliferation of atypical melanocytes located in the basal layer of the epithelium of skin⁵. The origin of a malignant melanoma in a mucous membrane is quite similar to that of a melanoma on the skin, as the melanocytes undergo malignant changes. The changes in the junctional layer are the dominant feature in the histogenesis².

The histogenesis of these tumors arising from the mucosa of the mouth, nasal cavity, oesophagus, rectum and the vagina is the junctional changes in

the lining epithelium⁴. Primary mucosal malignant melanoma of the head and neck is an uncommon lesion and comprise approximately 8 % of all melanoma cases that occur in this region. The prognosis of mucosal malignant melanoma (MM) of head and neck region especially in the oral cavity is poor³. Mucosal lentiginous melanomas (MLMs) develop from the mucosal epithelium that lines the respiratory, gastrointestinal and genitourinary systems. Noncutaneous melanomas commonly are diagnosed in patients of advanced age. When compared to cutaneous melanomas MLMs appear to have a more aggressive course, although this may be because they commonly are diagnosed at a later stage of disease than the more readily apparent cutaneous melanomas¹. In the oral cavity, metastasis to the palatine tonsil is very rare as tonsils do not have afferent lymphatics and any metastasis to the tonsil suggests hematogenous dissemination³. Spread via the systemic circulation or Batson's paravertebral venous plexus may account for involvement of the tonsillar region¹. To differentiate the primary and metastatic MM, detailed histopathological examination is required. The most histopathological finding of an intraepithelial neoplastic component (junctional activity) in the overlying or adjacent lateral mucosa. However in metastatic melanoma the mucosa is intact³. In our case, the medical history of the patient and the histological findings of overlying ulcerated mucosa in surgical specimen gross sections, we evaluated the lesion as primary malignant melanoma of the tonsil. The prognosis of tonsillar and mucosal MM metastasis is different than the cutaneous melanomas. So, it is important to perform detailed examination in tonsillar masses especially the ones with the previous melanoma history.

References

1. Rashed MM. Primary malignant melanoma of the tonsil. General organization for Teaching Hospitals & Institutes; Cairo- Egypt. htm [dmonarashed@hotmail.com]

2. Dass A, Ramandeep S, Virk, Hundel H, Mohan H. Malignant melanoma of the mucous membrane of the head and neck: three case reports. From the Department of Otolaryngology-Head and Neck surgery, Government Medical College and Hospital, Chandigarh, India. htm [virkdoc @ hotmail. com].
3. Emir H, Kaptan ZK, Tuzuner A, Akgedik S. A rare case of metastatic tonsillar malignant melanoma. The internet journal of Otorhinolaryngology 2008; Vol > (2).
4. Rao TVK, Khan MA, Ramachary V. Malignant melanoma of the tonsil. Indian journal of Otolaryngology; March 1977; Vol 29 (1) : 41
5. Ferreira LM et al. Tonsillar melanoma metastasis. Brazilian Journal of Otorhinolaryngology; November/December 2006 : 72 (6) : 851.

All correspondence to:
S Naz
Lecturer
Department of Pathology
Rajshahi Medical College, Rajshahi