



## Case Report

# Transumbilical Single Incision Two-Port Laparoscopic Assisted Appendectomy: Early Experience in Paediatric Patients

M A Nowshad<sup>1</sup>, A Mostaque<sup>2</sup>, S M A Shahid<sup>3</sup>, H K Emrul<sup>4</sup>

### Abstract

Laparoscopic appendectomy considered as superior alternative to open appendectomy. Usual laparoscopic appendectomy is performed with the three port system. In this study, we performed a unique single transumbilical incision two-port laparoscopic assisted appendectomy with the aim to reduce postoperative port site complication as well as improving cosmesis and patients satisfaction. From January 2010, 32 patients were admitted with clinically diagnosed acute appendicitis and were randomly assigned to single Transumbilical incision two-port laparoscopic assisted appendectomy.

Transumbilical single incision two-port laparoscopic assisted appendectomy was attempted in all patients (9 males and 23 females) with an average age of 9.2years. Transumbilical single incision two-port laparoscopic assisted appendectomy was successfully completed in 31 patients. In one patient, another additional port required due to severe adhesion of the appendix. Mean operation time was 25.2 minutes (range, 17-38), and mean post operative hospital stay was 1.5days (range 1-2). Postoperative complications (local pericaecal abscess) occurred in one case that was treated conservatively. Transumbilical single incision two-port laparoscopic assisted appendectomy appears to be a feasible and safe technique for the treatment of acute appendicitis in the paediatric setting. It allows nearly scar less abdominal surgery. The true benefit of the technique should be assessed by randomized controlled trials.

TAJ 2009; 22(2): 289-294

### Introduction

Laparoscopic surgery is becoming a popular treatment option for appendicitis because it offers various benefit like better visualization, reduction of negative appendectomy, reduces postoperative pain and port site complication, decrease hospital stay and improve cosmesis<sup>1-3</sup>.

In 1987, Schriber first reported laparoscopic appendectomy for the treatment of acute

appendicitis<sup>4,5</sup>. Since then several variation in laparoscopic appendectomy have been performed<sup>6</sup>. Single incision laparoscopic surgery has been described since late 1990 and beginning with appendectomy. In recent year several technical refinement have been proposed and performed to achieve further improvement in postoperative outcome<sup>7</sup>. To perform laparoscopic appendectomy most of the conventional procedure need 3 or 4 incision and complicated steps were required<sup>6,8</sup>. In

<sup>1</sup> Assistant Professor, Department of Paediatric Surgery, Rajshahi Medical College Hospital, Rajshahi.

<sup>2</sup> Professor, Department of Paediatric Surgery, Rajshahi Medical College Hospital, Rajshahi.

<sup>3</sup> Assistant Professor, Department of Paediatric Surgery, Rajshahi Medical College Hospital, Rajshahi.

<sup>4</sup> Assistant Registrar, Department of Paediatric Surgery, Rajshahi Medical College Hospital, Rajshahi.

order to reduce the number of incision and port, operative time, post operative pain, port site complication and also to increase simplicity, early mobilization, early return to normal activities, improve cosmesis as well as patients compliance single incision laparoscopic appendectomy is the attractive alternative to conventional multi port laparoscopic appendectomy<sup>6,7,9,10</sup>.

In Transumbilical single incision two-port laparoscopic assisted appendectomy, through a single incision on umbilicus (10mm) two trocar (5&3mm) are introduced and after laparoscopic skeletalization of appendix, it is brought out through umbilical port<sup>5,8</sup> and appendectomy is then completed out side the abdominal wall, using conventional technique<sup>5,6,8</sup>. Single incision laparoscopic assisted appendectomy is new technique that has now been used in many centres as golden standard for appendectomy<sup>11</sup>.

In this paper we are presenting our first experience and assess the feasibility of using Transumbilical single incision two-port laparoscopic assisted appendectomy to treat appendicitis in the paediatric population.

### Patients and Methods

From January 2010, Transumbilical single incision two-port laparoscopic assisted appendectomy was planned for 32 patients that were admitted in paediatric ward with right lower abdominal pain suggestive of acute appendicitis. All patients were evaluated clinically and undergone laboratorial examination. Exclusion criteria were as follows 1) Alvarado score <7. 2) Patients with complicated appendicitis with generalized peritonitis.3) Appendicular lump or abscess formation, 4) Any contraindication for general anesthesia. Patients received prophylactic antibiotics intravenously at the induction of anesthesia, and after surgery patients were administered two or three further doses of parenteral antibiotics. All patients underwent surgery after obtaining informed written consent. In this study all operation were performed by qualified laparoscopic surgeon.

### Operative technique

The umbilical region is kept clean preoperatively. The surgeon and the assistant stood on left side of the patient with the monitor placed on the opposite side. After general anesthesia, access was gained

via 1cm intraumbilical incision (Figure 1) with prolene stay suture on either side of the incision. After creating pneumoperitoneum with pressure between 8-10 mm of Hg, by veress needle, a 5mm trocar was inserted at the upper edge of the incision.

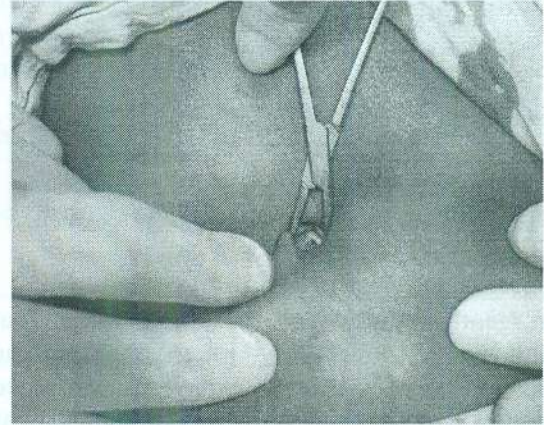


Fig. 1: Small incision through umbilicus

A 5 mm 30 degree laparoscope was used to complete a full laparoscopy. After that another 3 mm trocar was inserted through the fascia at the lower edge of the incision. (Figure 2)

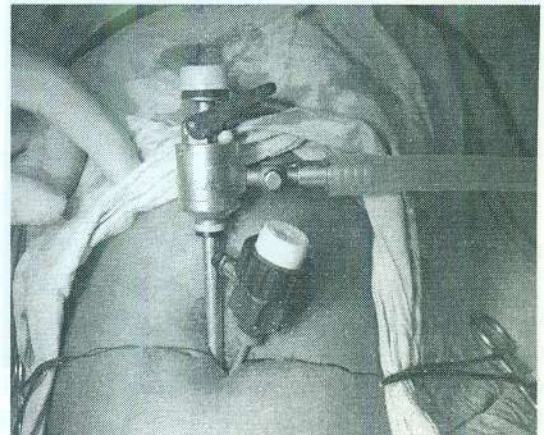


Fig. 2: Two trocar through single incision

The operating table was tilted to 30 degree trendelenburg position and rotated up to 40 degree on left side to allow adequate exposure. Then by laparoscopic grasping or non crushing Babcock forceps was introduced in to the abdomen and right lower abdominal quadrant was explored (Figure 3). The appendix was identified, located and tip of the appendix was grasped (Figure 4)

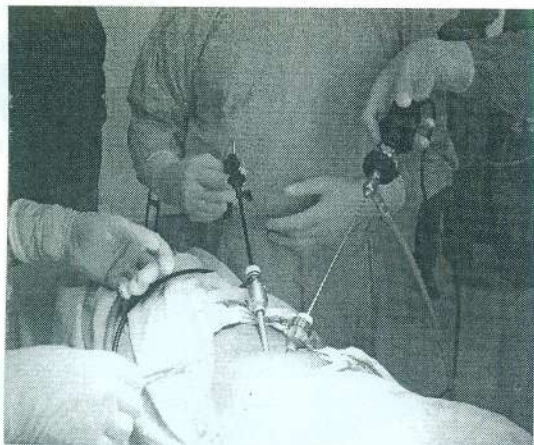


Fig. 1: Laparoscopic appendectomy is going on

and gently moves towards the umbilicus and subsequently delivered through the umbilical wound (Figure 5). During exteriorization process the intra peritoneal pressure was brought down to zero by allowing the gas to leak out. Coalescence of both trocar sites in one incision allows less difficult extraction of appendix.

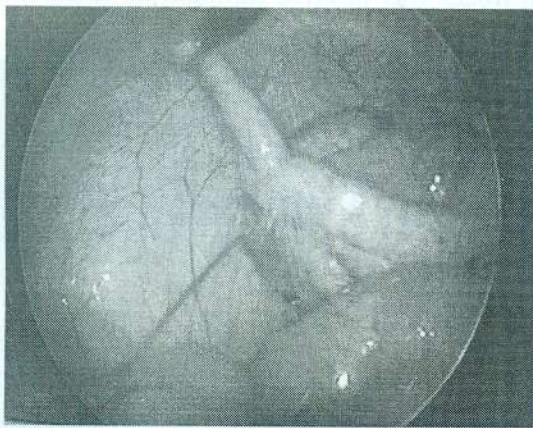


Fig. 4: Tip of the appendix was grasped.

Once the appendix was visible through umbilical incision, it is grasped by the traditional atraumatic forcep before laparoscopic forcep was released (Figure 6). An extracorporeal appendectomy was then easily performed under direct vision.

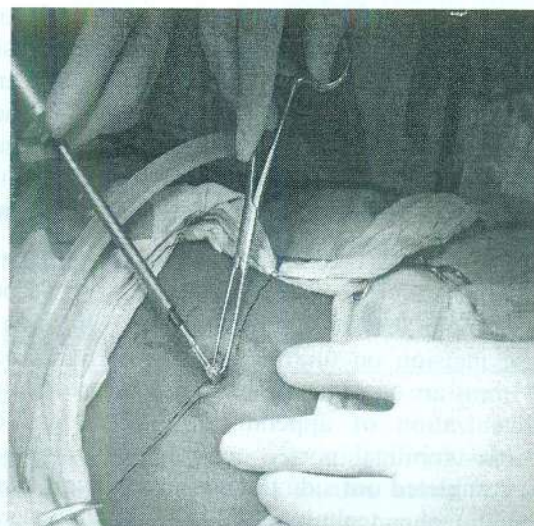


Fig. 5: Appendix is delivering through umbilicus.

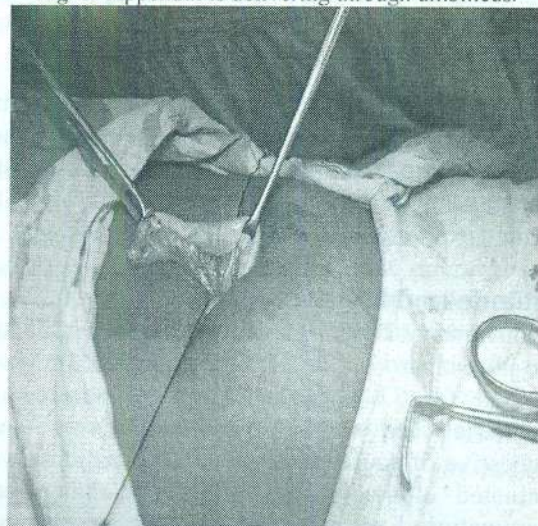


Fig. 6: Extracorporeal vision of appendix.

Then appendiceal stump was drooped back in to the peritoneal cavity.

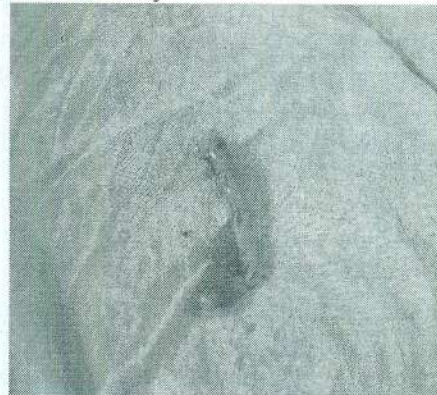

Fig. 7: Appendix after appendectomy

If necessary, a brief reinsufflations of the abdomen may be done for final inspection, peritoneal toileting and suction. Wound was closed in layers by vicryl.

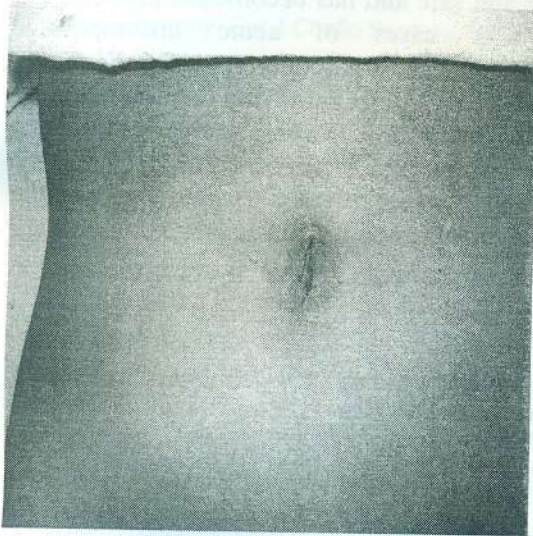

Fig. 8: Immediate postoperative scar

## Result

Transumbilical single incision two-port laparoscopic assisted appendectomy was attempted in 32 patients. There was 9 male and 23 female with an average age of 9.2 years (range, 4-13). Pathologic examination showed acute appendicitis in 27 cases (84.3%) and gangrenous appendicitis in 3 cases (9.3%). Two cases (6.2%) revealed normal appendix. The various position of appendix were as follows; pelvic type 16 cases (50%), retrocolic type 12 cases (37.5%), paracolic type 3 cases (9.3%) and post ileal type in 1 case (3.2%).

Transumbilical single incision two-port laparoscopic assisted appendectomy was successfully done in 31 cases (96.8%). in 1 case (3.2%), the operation was converted to the conventional three port laparoscopic appendectomy due to adhesion.

Mean operation time was 25.2 minute (range. 17-38) and mean postoperative hospital stay was 1.5 days (range, 1-2). There was no intra-operative complication. Twenty patients (62%) were discharged within 24 hours and 12 (38%) within

48 hours after operation. All patients were brought back to follow-up clinic at the end of week, then at 4 and 8 week. Post operative complication, localized pericaecal abscess, occurred in 1 (3.2%) case and treated successfully with conservative treatment. There was no wound infection or any episode of small bowel obstruction occurred in any patients. The operative findings, operative time and other clinical detail are shown in Table 1.

Table 1: showing different findings in this series

Variables	Number	
No. of patients (32)	Male	9 (28.1%)
	Female	23 (79%)
	M:F	1:2.5
Age	Average	9.2 years
	Range	4-13 Years
Position of appendix	Pelvic	16 (50%)
	Retrocaecal	12(37.5%)
	Para colic	3(9.3%)
	Post ileal	1(3.2%)
Condition of appendix	Appendicitis	31(96.8%)
	Normal	1(3.2%)
Operation time	Average	25.2 minutes
	Range	17-38 minutes
Hospital stay	Average	1.5 days
	range	1-2 days
Complication	yes	1(3.2%)
	no	31(96.8%)

## Discussion

Since beginning of laparoscopic appendectomy, there has continued to be a debate because of its higher cost, longer operating time<sup>12, 13</sup> and the fact that the combined length of the three incisions required for trocars equal the length of an open appendectomy incision. On the other hand, the open appendectomy, by virtue of its small incision, is a form of minimal access surgery. But several studies have demonstrated that the laparoscopic appendectomy resulted is an excellent exploration of the abdominal cavity, less pain, shorter hospital stay, early return to normal activity, less surgical site infection and better cosmesis<sup>1-3</sup>.

We restricted the incision to the umbilicus for better cosmesis. In our experience 96.8%

appendectomies were completed by using two trocars through single incision. There was a good correlation between preoperative diagnosis and post operative findings. In fact the number of normal appendices was low (6.2%).

The possibility of exploring abdominal cavity is one of the advantages of laparoscopy. Laparoscopy is not only useful for the identification and easier management of an ectopic appendix<sup>8,14</sup>, but also to discover associated extra-appendicial lesion. In 2 cases of normal appendix we looked for any ovarian pathology, gut adhesion or Meckel's diverticulum that might be the cause of right lower abdominal pain. Postoperative recovery was excellent in our series. We started oral feeding after 12 hours of operation in all cases. Hospital stay was shorter and all patients were discharged within 24-48 hours. One patient that developed pericaecal abscess was attended at follow-up clinic with fever that was treated conservatively.

Transumbilical single incision two-port laparoscopic assisted appendectomy patients showed a more rapid return to normal work. On average the children were able to return to unrestricted activities 7 days after operation. This advantage is unique because of no trocar was inserted in to the abdomen through the muscles.

Last but not least, from an aesthetic point of view the transumbilical incision was particularly very difficult to visualize at follow-up clinic. This is an obvious advantage, especially for the adolescent females.

However, there are few major difficulties with this new technique. As instrument and camera are inserted through the same incision, the ability to triangulate the instrument around the target is lost. External instrument clashing is another problem. In our experience this led to an initial significant increase in the operation time. With increasing exposure to the technique, operating time have been reduced significantly and are now very similar to the average time taken for an standard laparoscopic appendectomy. Further instrumental improvements may help to reduce operating in future.

## Conclusion

We reported our initial experience of Transumbilical single incision, two-port laparoscopic assisted appendectomy and it is feasible and safe and has become the procedure of choice for cases of acute uncomplicated appendicitis. Laparoscopic exploration of abdominal cavity may be carried out in all patients with suspected acute appendicitis. Our study shows that it is a viable alternative to open surgery and conventional three trocar laparoscopic technique for the treatment of acute uncomplicated appendicitis.

## References

1. Nguyen NT, Zainabadi K, Mavandadi S, Paya M, Stevens CM, Root J, Wilson SE. Trends in utilization and outcomes of laparoscopic versus open appendectomy. *Am J Surg* 2004;188:813-820.
2. Chung RS, Rowland DY, Li P, Diaz J. A meta-analysis of randomized, controlled trials of laparoscopic versus conventional appendectomy. *Am J Surg* 1999;177:250-256.
3. Champault A, Polliand C, Mendes da Costa P, Champault G. Laparoscopic appendectomies: Retrospective study of 2074 cases. *Surg Laparosc Endosc Percutan Tech* 2008;18:168-172.
4. Schrieber JH. Early experience with laparoscopic appendectomy in women. *Surg Endosc* 1987; 1: 211-216
5. Akir S, Takemaru, Hideak M, Hiroshi T, & Rie I. One port laparoscopic assisted appendectomy in children with appendicitis: Experience with 100 cases. *Pediatric endosurgery and innovative Technique*; 2001:4940; 371-377.
6. Konstadoulakis MM, Gomatos IP, Antonakis PT, et al. Twotrocar laparoscopic-assisted appendectomy versus conventional laparoscopic appendectomy in patients with acute appendicitis. *J Laparoendosc Adv Surg Tech A* 2006;16:27-32.
7. Eile C, Amaud D, Adriana T, Nada H, Ivan R & Andrew G. Single incision laparoscopic appendectomy for acute appendicitis: A preliminary Experience. *Sur Endosc*, 28<sup>th</sup> January, 2010;930,2794.
8. Valla JS, Ordorica Flores RM, Steyaert H, Merrot T, Bartles AM, Breaud J, Ginier C, Cheli M. Umbilical one-puncture laparoscopic-assisted appendectomy in children. *Surg Endosc* 1999; 13: 83-85

9. Andre C, Omar A, Sanjay P, Ara D & Paraskevas P. Single incision laparoscopic surgery for acute appendicitis: Feasibility in Pediatric patients: *Diag & Therap Endosc*:2010;2020;294958.
10. Estour E, Laparoscopic appendectomy, part 1, the extraabdominal or 'out' laparoscopic appendectomy: *Eur J Coelio Surgery*,1;67-71.
11. Varlet F, Tardieu D, Limonne B, Metafiot M, Chavrier Y. Laparoscopic versus open appendectomy in children. Comparative study of 403 cases. *Eur J Pediatr Surg* 1994; 4: 333-337
12. Katkhouda N, Mason RJ, Towfigh S, Gevorgyan A, Essani R. Laparoscopic versus open appendectomy: A prospective, randomized, double-blind study. *Ann Surg* 2005;242:439-448; discussion, 448-450.
13. Little DC, Custer MD, May BH, Blalock SE, Cooney DR. Laparoscopic appendectomy: An unnecessary and expensive procedure in children? *J Pediatr Surg* 2002;37:310-317.
14. El Goneimi A, Valla JS, Limonne B, Valla V, Montupet P, Chavrier Y, Grinda A. Laparoscopic appendectomy in children: Report of 1397 cases. *J Pediatr Surg* 1994; 6: 786-789

All correspondence to:

**M Nowshad Ali**

Assistant Professor

Department of Paediatric Surgery

Rajshahi Medical College Hospital, Rajshahi