



## Case Report

### Precocious Puberty : A Case Report

Hasina Akhtar<sup>1</sup>, Kaberi Guha<sup>2</sup>, Ziban Nahar<sup>3</sup>

---

#### Abstract

A 3-year-old girl was brought to Department of Obstetrics and Gynecology for breast development and excessive vaginal discharge. Her medical history and family history were unremarkable. From investigations she was diagnosed as a case of precocious puberty. This case report emphasized how this condition should be evaluated and how the girl was managed.

TAJ 2008; 21(2): 177-179

---

---

<sup>1</sup> Assistant professor, Department of Obstetrics & Gynecology, Rajshahi Medical College, Rajshahi.

<sup>2</sup> M.S, Obs & Gynae Thesis part, Rajshahi Medical College, Rajshahi.

<sup>3</sup> Resident Surgeon (Obstetrics and gynecology), Rajshahi Medical College Hospital, Rajshahi.

## Introduction

Puberty results when pulsatile secretion of gonadotrophin releasing hormone is initiated and the hypothalamic pituitary gonadal axis is activated. Cross sectional data obtained in the 1960's led to designation of the normal age range of pubertal onset at the age between 8 and 13 years in girls<sup>1</sup>. Pubertal development classified as precocious when it occurs before the age of 7 years in all other girls.

Other definition of precocious puberty is reserved for girls who exhibit any secondary sex characteristics before the age of 8 or menstruate before the age of 10<sup>2</sup>. The onset of puberty is marked by breast development in girls. Tanner stage 2 breast development means appearance of the breast bud marks the onset of pubertal development<sup>3</sup>. The most common mechanism of progressive precocious puberty is the early activation of pulsatile gonadotrophin releasing hormone secretion which results in maturation of hypothalamo-pituitary ovarian axis which activates maturation of hormone responsive tissue such as breasts, bones, pubic hair and endometrium. These girls have normal ovulation, menses and reproductive capacity<sup>4</sup>. Peripheral or gonadotrophin independent puberty is recognized including gonadal and adrenal tumour. For evaluation of patient with precocious puberty we should address several questions: Is pubertal development really occurring outside the normal temporal range?

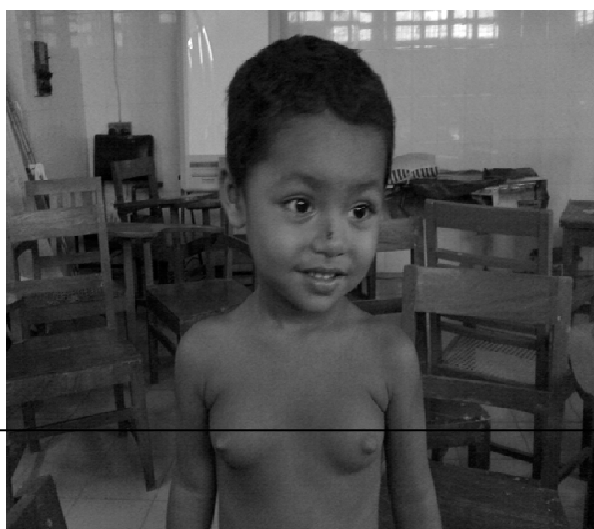
What is the underlying mechanism? Is pubertal development likely to progress and if so, would this impair the child's normal physical and psychosocial development?

## Case report

A 3-year-old girl was admitted in Rajshahi Medical College Hospital with the complaints of enlargement of breast for one year and per vaginal discharge for one year. According to the statement of patient's mother her child was alright one year back. Her milestones of development were normal. But she noticed that breast was enlarging gradually. Her mother also noticed that the girl

was suffering from whitish discharge per vagina. But the discharge was not offensive and not associated with any itching. She had no history of birth injury, head injury, encephalitis, headache or seizures.

General physical examination of the patient was within normal limit. Her height was 81 cm, her weight 14kg and skin pigmentation absent. But examination of breast revealed that her both the breast was enlarged and firm in consistency. Nipple and areola were developed. No discharge was present. Axillary and pubic hair was sparse.



On per abdominal examination no palpable lump was present. Hormonal assessment was done in this patient serum estradiol and LH level was elevated and which was within pubertal range. Pelvic ultrasound scan showed uterus was enlarged for age i.e. uterine volume >2.0ml or length >34mm. Endometrium was thickened. In this scan both the ovaries are almost adult size.

The basic investigations to confirm or to exclude some pathological lesions; X-Ray hand and wrist for bone age. In this patient bone age was greater than chronological age. MRI of brain was done to exclude intra cranial lesion. After getting all the investigations we came to conclusion this girl suffered from precocious puberty which is central or constitutional. After counseling with the patient's guardian we started our treatment. We prescribed GnRH agonist, Inj. Decapeptyl 3. 75

mg every 4 weeks. Now she is 3 years old. The drug is to be continued for 11 years of her age. After giving treatment follow up was done after one month. At that time she developed menstruation which remains for 2 days. Pelvic and axillary hair increases. But when she came after 2 months her breast size decreases and menstruation not appeared. We advised the guardian to come every month for taking inj. GnRH agonist up to 11 years of her age.

## Discussion

In the case described, we have found advanced breast development, pubic and axillary hair development. Her height was within normal limit. She had excessive vaginal discharge and at one time the patient had menstruated. Evidence of possible causes of precocious puberty was sought by means of thorough history taking and careful examination. In her personal history and family history nothing contributory was noted. Level of sex steroid should be determined. In girls, serum estradiol level is highly variable but low sensitivity for diagnosis of precocious puberty<sup>5</sup>. Random measurement of luteinizing hormone has been proposed. In one study randomly measured value 0.3 IU per liter and above were reported to be 100% specific<sup>6</sup>.

In our case serum estradiol and LH level were elevated. A reference atlas such as the one by Greulich to evaluate the effect of sex steroid on epiphyseal maturation. The bone age is greater than chronological age<sup>7</sup>.

Bone age is greater than chronological age is also in this case. A study showed that to perform GnRH agonist stimulation test to further evaluate the activation of gonadotrophin axis and the potential for progression of puberty<sup>8</sup>. There are no facilities in our institution for GnRH agonist stimulation to see the progression of puberty. Several reports showed that MRI scan did not show any CNS lesion in approximately 92% of girls<sup>9</sup>. These girls also have no abnormalities on MRI. Most common mechanism of progressive or central precocious puberty is the early activation of pulsatile gonadotropin releasing hormone which may result from hypothalamic tumour or lesion

but in most cases remain unexplained<sup>10</sup>. Several reports showed that constitutional type is the commonest but rare is to be kept in mind. However in our patient from history with various investigations we come to conclusion this is a case of precocious puberty central type. In open label, non comparative longitudinal studies, the use of GnRH agonists consistently resulted in the regression or stabilization of pubertal symptoms<sup>11</sup>.

There are many options of medication medroxy progesterone acetate, cyproterone acetate and letrozole. Pubertal manifestation generally reappears within months after GnRH agonist treatment has been stopped. With a mean time to menarche of 16 months. Long term fertility has not been fully evaluated but preliminary observations are reassuring<sup>12</sup>.

The availability, approved use, recommended dosages of depot GnRH agonist vary throughout the world. We use inj. Triptorelin 3.75mg every 4 weeks up to 11 years at her age. Prognosis of this patient is good. No such side effect of drug detected in this patient.

## References

1. Vottero A et al. Final height in girls with central idiopathic precocious puberty. *J Clin Endocrinol Metab* 2006; 91: 1284 – 7.
2. Eugster ex et al. Tamoxifen treatment for precocious puberty. *J Pediatr* . 2003; 143 : 60 - 6.
3. Caral Jeen et al. Precocious puberty. *N Engl J Med*. 2008; 358: 2366 - 77.
4. Lahlon et al. Pharmacokinetics and pharmacodynamics at GnRH agonist *J Pediatr Endocrinol Metabolism* . 2000; 137:723 – 37.
5. Neely et al. Two year result of treatment with depot euprolide acetate for central precocious puberty. *J Pediatr*. 1992; 121: 634 - 40.
6. Jaranill et al. Treatment at central precocious puberty by subcutaneous injection of leuprorelin *J Clin Endocrinol Metab*. 2002; 87: 4111 – 6.
7. Klein et al. Increased final height in precocious puberty after long term treatment with LHRH agonist. *J Clin Endocrinol Metab*. 2001; 86: 4711 – 6.

8. Palmert MR et al. Analysis of growth and body composition in 110 patients with central precocious puberty. *J Clin Endocrinol Meta* .1999; 84: 4480 – 8.
9. Heger S et al. Long term GnRH agonist treatment for female central precocious puberty. *Molceel Endocrinol* .2006; 254 – 255: 217 – 20.
10. Tinam LE et al. Vs findings of adenexal torsion in children and adolescents. *Pidatr rediol*. 2007; 37: 1013 – 9.
11. Pectaside et al. Granulosa tumour of the ovary. *Cancer Treat Rev* .2008; 34: 1-12.
12. Wilson DM et al. Serum luteinizing hormone rises within minutes after depot Leuprolide injection. *Pediatrics*. 2002; 109: F 30.

All correspondence to:  
**Hasina Akhtar**  
Assistant Professor  
Gynecology & Obstetrics  
Rajshahi Medical College  
Rajshahi.