



## Original Article

# Topical Isotretinoin in Acne Vulgaris

M Moksedur Rahman<sup>1</sup>, M Abdullah<sup>2</sup>, M Moazzem Hossain<sup>3</sup>, M A Siddique<sup>4</sup>, M Nessa<sup>5</sup>,  
M K Rahman<sup>6</sup>, Khan MMR<sup>6</sup>, M Zillur Rahman<sup>7</sup>, S M A Taher<sup>8</sup>, S M AfzalUddin<sup>9</sup>

### Abstract

This study was carried out to evaluate the efficacy, safety and adverse effects of topical isotretinoin 0.05% gel in the treatment of acne vulgaris. This prospective study was undertaken in Skin & VD outpatient department of Rajshahi Medical College Hospital, Rajshahi. One hundred patients with mild to moderate acne vulgaris were enrolled and were instructed to apply isotretinoin 0.05% gel once daily at night for 12 weeks. Patients were followed up at 2, 4, 8 and 12 weeks for efficacy and tolerability. Efficacy was measured by counting facial inflammatory and noninflammatory lesions and by grading acne severity. Cutaneous tolerance was assessed by determining erythema, scaling and burning with pruritus. Response was excellent in 80% of cases. None of the cutaneous reactions was severe, all were mild and well tolerated. Nobody had to discontinue the therapy for side effects. This study confirms that isotretinoin 0.05% gel is safe and effective topical therapy for mild to moderate acne vulgaris.

**Key words :** Acne vulgaris, isotretinoin

TAJ 2016; 29: No-2: 01-05

### Introduction

Acne vulgaris is a common skin disease, affecting about 70-80% of adolescents and young adults. It is a multifactorial disease of the pilosebaceous unit.<sup>1</sup> Acne vulgaris is characterized by comedones, papules and pustules and less frequently by nodules, cysts and scars.<sup>2</sup> Four major factors associated with the pathogenesis of acne are increased

sebum production, follicular hyper keratinization, propionibacterium acnes proliferation and inflammation.<sup>3</sup> 15-30% of patients with acne need intense medical treatment.<sup>4</sup> The treatment is aimed to reduce the rate of sebum production, reduce bacterial

population in pilosebaceous follicle and reduce inflammation. The mild to moderate forms of acne are generally treated topically while the severe form of acne is treated orally.<sup>5</sup>

Topical retinoids represent a mainstay of acne treatment, because they expel mature comedones, reduce microcomedone formation and exert anti-inflammatory effects.<sup>6</sup> They normalize epidermal proliferation and differentiation and also influence inflammation via inhibition of the release of prostaglandins, leukotrienes and pro inflammatory cytokines as well as via inhibition of neutrophil

<sup>1</sup> Associate Professor, Department of Dermatology & venereology, Rajshahi Medical College, Rajshahi.

<sup>2</sup> Medical Officer, Islami Bank Medical College Hospital, Rajshahi.

<sup>3</sup> Professor, Department of Dermatology & venereology, Rajshahi Medical College, Rajshahi.

<sup>4</sup> Assistant Professor, Department of Dermatology & venereology, Rajshahi Medical College, Rajshahi.

<sup>5</sup> Associate Professor, Department of Dermatology & venereology, Islami Bank Medical College, Rajshahi.

<sup>6</sup> Associate Professor, Department of Medicine, Rajshahi Medical College, Rajshahi.

<sup>7</sup> Assistant Professor, Department of Medicine, North Bengal Medical College, Sirajganj.

<sup>8</sup> Assistant Professor, Department of Anaesthesiology & Intensive Care Unit, Rajshahi Medical College, Rajshahi.

<sup>9</sup> Assistant Professor, Department of Medicine, Rajshahi Medical College, Rajshahi.

chemotaxis and the expression of toll like receptors.<sup>7,8</sup>

Isotretinoin (13 - cis retinoic acid) acts primarily through its isomerization to retinoic acid and binds to all RAR<sub>s</sub>

(retinoic acid receptors)- $\alpha$ ,  $\beta$  and  $\gamma$ .<sup>9, 10</sup> It does not bind to RXR (Retinoid X receptor) or CRABP (cellular retinoic acid binding protein).<sup>11, 12</sup> In contrast with the oral preparation, it does not reduce sebaceous gland size or suppress sebum production.<sup>13, 14</sup>

Oral isotretinoin is very effective for severe forms of acne and it has significant systemic side effects. The oral drug is highly teratogenic. Topical isotretinoin diminishes side effects associated with systemic therapy, particularly teratogenicity & allows the drug to be used less restrictively or with greater safety for mild to moderate acne. The purpose of this study was to determine the efficacy, safety and adverse effects of topical isotretinoin 0.05% gel in the treatment of mild to moderate acne vulgaris.

### Material and Methods

The study was conducted in Skin & VD outpatient department of Rajshahi Medical College Hospital, Rajshahi. Total duration of study was six months. Acne was graded according to the Consensus Conference of Acne classification convened by American Academy of Dermatology in Washington DC on march 24 and 25 1990.<sup>15</sup> According to these criteria, mild acne is defined by the presence of comedones, without significant inflammation and a few or no papules; moderate acne, by the presence of comedones, with marked inflammatory papules and pustules and severe acne by the presence of inflammatory nodules, in addition to comedones, papules and pustules. One hundred patients were selected for the study with mild to moderate acne vulgaris (50 male & 50 female) of age range of 13-30 years. The patients were instructed to stop medicated shampoos or cleansers for 1 week prior to starting the study. No other cutaneous disease could be present on the face. Pregnant or lactating females, known hypersensitivity to isotretinoin, patients with history of topical and systemic treatment of acne within 6 months of starting treatment, history

of use of hormonal preparation or antibiotics over the last 3 months were excluded from the study. Pregnancy and lactation excluded female patients were advised to use non hormonal methods of contraception throughout the study period and for 1 month after stopping use of the study medication. Written informed consent was obtained from each patient prior to enrollment.

The patients were instructed to wash & dry their faces in the morning and at bed time with a neutral soap and to apply a thin layer of isotretinoin gel 0.05% to the entire face once daily at bed time during the 12 weeks treatment period. Efficacy and cutaneous tolerance were assessed four times over the trial period at weeks 2, 4, 8 and 12. Efficacy was evaluated by counting facial inflammatory and non-inflammatory lesions at each follow up visit and the severity of acne was graded. Response was graded as excellent (76-100 % reduction in total lesion counts), good (51-75 % reduction in total lesion counts), fair (26-50 % reduction in total lesion counts) and poor (0-25 % reduction in total lesion counts). Cutaneous tolerance was assessed by determining erythema, scaling, burning and pruritus. All cutaneous tolerance evaluations were graded on a 0-3 scale, with 0=none; 1=mild; 2=moderate and 3=severe. All observations including adverse reactions, were recorded on standardized case reports forms.

### Results

A total of 100 patients with mild to moderate acne vulgaris were included in the study. Six patients (4 male and 2 female) were lost to follow up. The rest of patients (46 male and 48 female) completed the study in four follow up visits over a span of six months. Mean age of the patients and sex distribution is shown in Table 1. The number of patients with mild and moderate acne vulgaris is shown in Table 2.

The mean number of non-inflammatory lesion at baseline was 88.5 which significantly reduced to 20.5 at fourth follow up visit (Figure 1). The mean number of inflammatory lesion at base line was 21.5 which significantly reduced to 6.7 at fourth follow up visit (Figure 2).

There was a gradual reduction in the counts of non-inflamed and inflamed lesions. At all-time points the reduction in counts was statistically significant

from the baseline. The decrease in total lesion count was also significant.

**Table 1 : Age and Sex distribution**

Age(years)	Mean	19.5
	Range	13 – 30
Sex	Male	46 (48.94%)
	Female	48 (51.06%)

**2 : Frequency of grades of acne vulgaris (n=94)**

Grade	Number	Percentage
Mild	32	34.04
Moderate	62	65.96

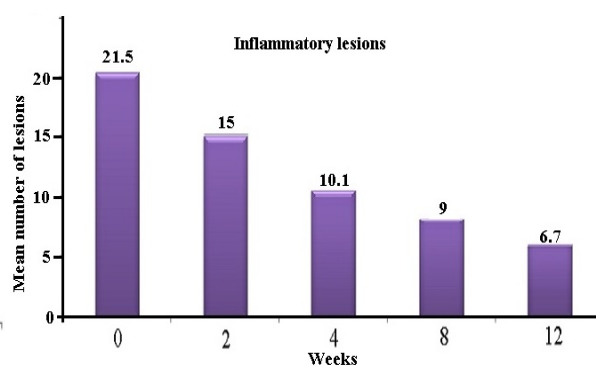
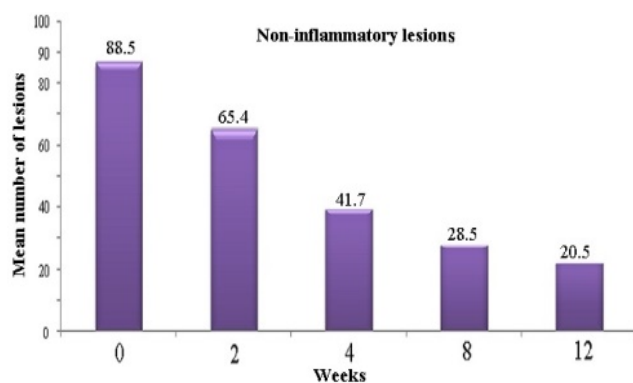
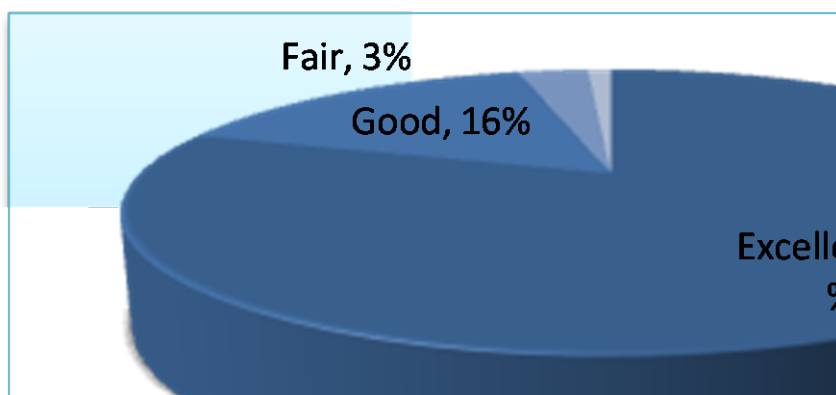


Figure 1 : Mean noninflammatory lesion count Figure 2 : Mean inflammatory lesion count There was a statistically significant reduction in the lesion count as compared with the baseline values.



**Table 3 : Frequency of erythema**

2 weeks	4 weeks	8 weeks	12 weeks	2 weeks	4 weeks	8 weeks	12 weeks
15 (16%)	12 (12.8%)	8 (8.5%)	6 (6.4%)	14(14.9%)	13 (13.8%)	12 (12.8%)	11 (11.7%)

**Table 4 : Frequency of scaling**

**Table 5 : Frequency of burning / pruritus**

2 weeks	4 weeks	8 weeks	12 weeks
36 (38.3%)	31 (33%)	25 (26.6%)	15 (16%)



Regarding efficacy, the improvement was excellent in 75 patients (80%) Good in 15 patients (16%) and fair in

3 patients (3%) and poor in 1 patient (1%) (Figure 3).

Irritation was mild and no discontinuation was reported because of adverse effects. The number of patients who had erythema, scaling and burning with pruritus steadily decreased from week 2 to week 12. There was a significant decrease in the frequency of side effects between first and fourth follow up visits (Table 3, 4, 5). No dosage regimen alteration was required during the study period and no systemic effects were observed.

## Discussion

The development of the drug isotretinoin for oral use has changed significantly the treatment of severe acne, particularly the cystic type.<sup>16</sup> The response is frequently very dramatic and acceptable to the patient. The oral drug has systemic side

effects including teratogenicity. The usefulness of oral isotretinoin for acne prompted this investigation of the efficacy of a topical formulation of the drug for the treatment of less severe cases of acne vulgaris.

The result of this study indicates that isotretinoin gel is highly effective in the treatment of mild to moderate acne vulgaris. It reduces both inflammatory and non-inflammatory lesions. The systemic side effects seen with oral isotretinoin have not been observed when the agent is used topically. Result of the present study are comparable to results of other studies.<sup>16-19</sup>

Chalker DK et al. Conducted a multicenter double-blind investigation and observed that isotretinoin 0.05% gel was

effective in reducing inflammatory lesions after 5 weeks and in reducing non-inflammatory lesions and acne severity grade after 8 weeks.<sup>16</sup> Judith Dominguez et al observed that topical isotretinoin reduced the number of inflammatory and non-inflammatory lesions.<sup>17</sup> Sara Inayat et al. conducted a study and found that topical

isotretinoin was highly effective in the treatment of mild to moderate acne vulgaris.<sup>18</sup> D. Ioannides et al. showed that topical application of 0.05% isotretinoin gel significantly improved inflammatory lesions within 5 weeks and non-inflammatory lesions

within 8 weeks.<sup>19</sup> Similar results were obtained in our study, after 12 weeks of once-daily topical application. In this study patients experienced some degree of erythema, scaling and burning with pruritus. The percentage of patients in our study who experienced burning and pruritus at fourth follow up visit is in accordance with the findings of Sara Inayat et al.<sup>18</sup>

In the present study, majority of patients tolerated once daily treatment with no irritation. None of the cutaneous

reactions was severe, all were mild and well tolerated. No systemic adverse effects were observed. No body had to discontinue the therapy for side effects. This study confirms that isotretinoin 0.05% gel is safe and effective topical therapy for mild to moderate acne vulgaris.

## References

1. Gollnick H. Current concepts of the pathogenesis of acne : implications for drug treatment. *Drugs* 2003; 63 : 1579-96.
2. Simpson NB & Cunliffe WJ. Disorder of the sebaceous glands. In : Tony B, Breathnach S, Cox N & Griffiths C. *Rook's Textbook of Dermatology*, 7<sup>th</sup> edn. Oxford, UK. : Blackwell Science Publication; 2004. P.43. 1-43.74.
3. Gollnick H, Cunliffe WJ, Berson D, et al. Management of acne : a report from a global alliance to improve outcomes in acne. *J Am Acad Dermatol* 2003; 49 : S 1-37.
4. Anja Thielitz, Mohamed B. Abdel Naser, Joachim W. Fluhr, Christos C. Zouboulis, Harald Gollnick. Topical retinoids in acne - an evidence based overview. *JDDG* 2008; 6 :1023-1031.
5. Nilkamal Waghmare, Pradhnya Waghmare, Swapnil Wani, Ashwini Yerawar. Development of Isotretinoin gel for the treatment of Acne Vulgaris. *RJPBCS* 2011; 2 :220-230.
6. Thielitz A, Gollnick H. Topical retinoids in acne vulgaris : Update on efficacy and safety. *Am J clin Dermatol* 2008;9 (6): 369-81.

7. Wolf JE, Jr. Potential anti-inflammatory effects of topical retinoids and retinoid analogues. *AdvTher* 2002; 19 : 109-18.
8. Sardana K, Shegal VN. Retinoids : fascinating up and coming scenario. *J Dermatol* 2003; 30: 355-80.
9. Bernard BA. Adapalene, a new chemical entity with retinoid activity. *Skin pharmacol* 1993;6 (suppl.) : 61-9.
10. Redfern CRF. Molecular markers of retinoid activity in the skin. *J Invest Dermatol* 1994;102 :11-12.
11. Hirschel - Scholz S, Siegenthaler G, Saurat JH. Isotretinoin differs from other synthetic retinoids in its modulation of human cellular retinoic acid binding protein (CRABP). *Br J Dermatol* 1989; 120 : 639-44.
12. Zouboulis CC. Exploration of retinoid activity and the role of inflammation in acne : issues affecting future direction for acne therapy. *J Eur Acad Dermatol Venereol* 2001; 15 (suppl 3) : 63-7.
13. Tschan T, Steffen H, Supersaxo A. Sebaceous-gland deposition of isotretinoin after topical application : an invitro study using human facial skin. *Skin pharmacol* 1997; 10 : 126-34.
14. Melnik B, Kinner T, Plewing G. Influence on oral isotretinoin treatment on the composition of comedonal lipids. Implications for comedogenesis in acne vulgaris. *Arch Dermatol Res* 1988;280 : 97-102.
15. Peter E Pochi et al. Report of the Consensus Conference on acne classification, Washington DC, March 24 and 25, 1990. *JAAD* 1991; 24(3) : 495-500.
16. Chalker DK et al. Efficacy of topical isotretinoin 0.05% gel in acne vulgaris : Results of a multicenter, double-blind investigation. *Journal of the American Academy of Dermatology* 1987; 17(2) : 251-4.
17. Judith Dominguez, Martia Teresa Hojyo, Jose Luis Celayo, Luciano Dominguez-Soto, Fernannda Teixeira. Topical isotretinoin vs topical retinoic acid in the treatment of acne vulgaris. *International Journal of Dermatology* 1998; 37 : 51-55.
18. Sara Inayat, Khawar khurshid, Maimoona Inayat, Sabrina Suhailpal. Comparison of efficacy & tolerability of topical 0.1% adapalene gel with 0.05% isotretinoin gel in the treatment of acne vulgaris. *Journal of Pakistan Association of Dermatologists* 2012 ; 22(3) : 240-7.
19. Ioannides D, Rigopoulos D, Katsambas A. Topical adapalene gel 0.1% vs isotretinoin gel 0.05% in the treatment of acne vulgaris : a randomized open-label clinical trial. *British journal of Dermatology* 2002 ; 147: 523-7.

All correspondence to  
**Dr. Md Moksedur Rahman**  
 Associate Professor  
 Department of Dermatology & Venereology  
 Rajshahi Medical College, Rajshahi.