



Original Article

CT Findings of Acute Stroke– Study of 321 Cases

Md. Durrul Huda,¹ Niranjan Kumar Saha,² Quamruddin Ahmad,³ Md. Kafil Uddin,⁴
Md. Munzur Alahi,⁵ Md. Hafizur Rahman⁶

Abstract

Stroke ranks first in frequency among all the neurological diseases of adult life and about 50% of all neurological disorders in a hospital are of this type. It is the third leading cause of death throughout the world. The purpose of the present study was to find out the presence or absence of haemorrhage or infarct and to detect the early signs of stroke on the basis of CT scanning.

Three-hundred twenty one consecutive acute stroke patients (mean age 64 ±9.75 years) were included in our study. Each underwent cranial computed tomography without intravenous contrast injection within the first 24 hours. CT findings of stroke were analyzed using SPSS software.

Among 321 patients, 209(65.11%) had ischemic stroke, 99(30.84%) had parenchymal haemorrhage and 13(4.05%) had subarachnoid haemorrhage. Total amount of haemorrhagic stroke was 112(34.89%). Early CT findings of ischaemic stroke were low attenuation area (83.25%), sulcal effacement (69.89%), loss of the insular ribbon (17.70%), hyperdense artery sign (1.43%).

CT scanning should be the first line of investigation for diagnosis of acute stroke as it is more available than MRI and is easily performed in severely ill patients who are dependent on support and monitoring devices

Key words: CT findings, acute stroke

TAJ 2019; 32: No-1: 17-24

Introduction

Stroke is a sudden loss of brain function which happens due to the disruption of cerebral blood flow.¹ The stroke is characterized by expeditious development of clinical symptoms during first few minutes or hours after which symptoms progress and in some patients lead to death.² In more than 80% of stroke, the cause is vascular insufficiency and this type of stroke is called ischemic. Main cause of ischemic stroke is cerebrovascular

thromboembolism. In other cases, around 15% of them, there is a cerebral blood vessel rupture which leads to haemorrhagic stroke (intracerebral haemorrhage)³. Stroke is a global issue and it takes a prominent place in the matter of adult mortality and morbidity.^{2,3}

Cerebrovascular accidents are one of the leading causes of death after heart disease and cancer in the developed countries and one of the leading causes of death in Bangladesh. The exact

¹ Assistant Professor, Radiology and Imaging, Rajshahi Medical College, Rajshahi.

² Professor, Department of Biochemistry and Molecular Biology, University of Rajshahi.

³ Professor and Head, Department of Neurology, Holy Family Red Crescent Medical College, Dhaka.

⁴ Associate Professor and Head, Department of Neurology, Rajshahi Medical College, Rajshahi.

⁵ Professor, Department of Neurology, Rajshahi Medical College, Rajshahi.

⁶ Professor and Head, Department of Radiology and Imaging, Rajshahi Medical College. Rajshahi.

prevalence rate of this disease is not known in our country. The incidence rate and the death rate from stroke increases dramatically with age. About 15 to 30% of patients die with each episode of cerebral infarction and 16 to 80% with cerebral haemorrhage. Those who survive are usually left with permanent disability. Thus, stroke becomes a great medical and social problem. Accurate and early diagnosis may lessen the morbidity and mortality rates in the future as newer and more effective therapies are currently being instituted.⁴ Computed tomography (CT) is now used routinely in the investigation of cerebrovascular disease to distinguish between infarct and haemorrhage, in connection with intention to treat, and to confirm a diagnosis of stroke.

The advent of CT in early 1970s greatly facilitated the diagnosis and management of stroke and added significantly to our understanding of pathophysiological brain alterations. With CT it is now possible for the first time to noninvasively and reliably diagnose and distinguish between strokes due to cerebral infarction and stroke due to haemorrhage. In addition, other brain lesions, at times, may be clinically present as stroke like syndromes such as primary or metastatic brain tumor or subdural hematoma that can usually be clearly differentiated by CT examination.^{5,6}

Computed Tomography is one of the most accurate methods available for identifying and localizing an infarction and haemorrhage within the brain. Ischemic infarction, haemorrhagic infarction, intracerebral hematoma and subarachnoid haemorrhage are usually differentiated. CT also permits identification of the acute and chronic sequence that may develop after a sequence of infarction or haemorrhage. These include, in acute phase, brain swelling and conversion of a bland infarct into haemorrhagic infarct and in chronic phase, cystic parenchymal change, cortical atrophy and focal ventricular dilation.⁴

Materials and Methods

This cross sectional observational study was performed in different clinics of Rajshahi and the department of Radiology & Imaging, Rajshahi

Medical College Rajshahi in collaboration with the Department of Neuromedicine of Rajshahi Medical College, Rajshahi, Bangladesh, from January 2012 to December 2015. The study population was comprised of total 321 patients who had definite evidence of first ever ischaemic type of stroke within 24 hours and were diagnosed by computed tomography (CT). Data was collected on the basis of inclusion and exclusion criteria, history sheets and relevant CT scan films of the patients irrespective of sex and age. The local ethical committee approved the study.

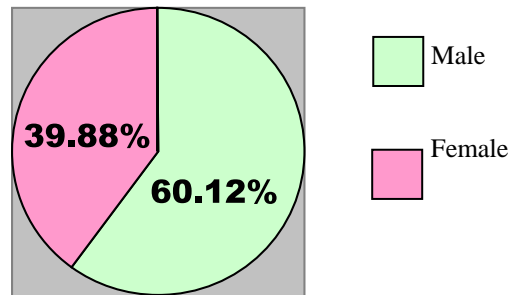
Stroke was diagnosed when neurological deficits were accompanied by corresponding abnormal findings depicted on brain computed tomography (CT). Detailed history, neurological examination and CT scan of brain were taken of all stroke patients to establish the diagnosis of stroke. After collection of data, these were entered into computer and analysis was done by using SPSS. Data were presented in the forms of tables, figures and diagrams

Results

The study population was comprised of total 321 patients who had definite evidence of first ever stroke and was diagnosed by computed tomography (CT). Among them haemorrhagic stroke were 112 (34.89%) & ischemic stroke were 209(65.11%). Age and sex distribution of the study population have been shown in table -1 and Fig-1 respectively. The mean age of the study population was 64 ± 9.75 years with a range of 34 to 95 years and the cases were divided into five different age groups; viz, 31- 40 years, 41-50 years, 51-60 years, 61-70 years and above 70 completed years in this study. It was found that the highest number of the patients 118(36.76%) belong to 7th decade. The next highest group belongs to 6th decade 103(32.09%). It was found that 54(16.82%) were above 8th decade, 39(12.15%) in 5th decade and 7(2.18%) were in 4th decade. Among the patients, 61-70 age group range showed highest frequency for male and female. The mean age of the study population was 64 ± 9.75 years.

Table 1: Distribution of the study patients by age (years) (n=321)

Age (years)	Male		Female		Total No.
	No. of patients	%	No. of patients	%	
31-40	4	1.25	3	0.93	7(2.18%)
41-50	23	7.17	16	4.98	39(12.15%)
51-60	63	19.63	40	12.46	103(32.09%)
61-70	72	22.43	46	14.33	118(36.76%)
> 70	31	9.66	23	7.17	54(16.82%)
Total	193	60.12%	128	39.88%	321(100.00%)

**Figure-1: Pie chart showing sex distribution**

In the present study hypertension was found to be the most common risk factor affecting 225(70.09%) out of 321 patients. Beside hypertension, the study patients had diabetes 65 (20.25%), heart disease 63 (19.63%), smoking 113(35.20%), family history of stroke 23(7.17%) and H/O oral pill 20(15.63 %) in female patients (Table- 2).

Table 2: Distribution of the study patients by risk factors (n=321)

Risk factors	Male(193)		Female(128)		Total No. (%) N=321
	No. of patients	(%)	No. of patients	(%)	
Hypertension	129	57.33/66.84	96	42.67/75.00	225 (100.0)/(70.09)
Smoking	111	98.23/57.51	2	1.77/1.56	113 (35.20)
Diabetes mellitus	37	56.92/19.17	28	43.08/21.86	65 (20.25)
Heart disease	39	61.90/20.21	24	38.10/18.75	63 (19.63)
H/O oral pill	-	-	20	15.63	20 (6.23)
Family history	13	56.52/6.80	10	43.48/7.81	23 (7.17)

Among 321 patients, 209(65.11%) had ischemic stroke, 99(30.84%) had parenchymal haemorrhage and 13(4.05%) had subarachnoid haemorrhage. Total amount of haemorrhagic stroke was 112(34.89%). Among the male patients 121 (62.69%) were ischaemic and 72(37.31%) were haemorrhagic stroke. Among the female patients 88(68.75%) were of ischaemic & 40(31.25%) were of haemorrhagic stroke (Table 3a, 3b and 3c).

Table 3a: Type of stroke of the study patients (n=321)

Type of stroke	No. of patients	% of patients
Infarcts	209	65.11
Haemorrhagic	112	34.89

Table 3b: Type of stroke (Infarcts, parenchymal and subarachnoid haemorrhage) of the study patients (n=321)

Type of stroke	No. of patients	% of patients
Infarcts	209	65.11
Haemorrhagic	Parenchymal	99
	Subarachnoid	13

Table 3c: Distribution of the study patients by type of stroke and sex (n=321)

Stroke	Male (n=193)		Female (n=128)		P value
	No. of patients	%	No. of patients	%	
Infarcts	121	62.69	88	68.75	0.265
Haemorrhagic	72	37.31	40	31.25	

p value reached from chi square test. The difference was not significant ($p>0.05$).

There are different CT signs of ischaemic and haemorrhagic stroke. These are shown in table -4 and table-5 respectively and Photo-1 to 6.

Table 4: CT Signs of ischaemic stroke patients (n=209)

CT Signs	No. of patients	% of patients
Low attenuation	174	83.25
Midline shift	121	57.89
Sulcal effacement	144	69.89
Loss of the insular ribbon	37	17.70
Hyperdense artery sign	3	1.43
Hydrocephalus	43	20.57
Transtentorial herniation	24	11.48

Table 5: CT Signs of haemorrhagic stroke patients (n=209)

CT Signs	No. of patients	% of patients
Hyper attenuation	112	100.00
Midline shift	82	73.21
Sulcal effacement	89	79.46
Intraventricular extension	35	31.25
SAH extension	26	23.21
Intraventricular and SAH extension	7	6.25
Hydrocephalus	42	37.50
Transtentorial herniation	24	21.43
SAH	13	11.61

Discussion

This study was done to evaluate different CT scan findings in patients presenting with acute stroke in differentiating between haemorrhage and infarct. Before the advent of CT scan and in places where CT scan was not available, physicians were mainly dependent on the history, physical findings and the Allen's method of scoring system to differentiate between haemorrhage and infarct using this scoring system. Allen studied 174 cases of acute stroke and was able to make an accurate diagnosis in 90% of cases.⁷

Unenhanced CT is widely available, can be performed quickly, and does not involve the administration of intravenous contrast material. It not only can help identify a haemorrhage (a contraindication to thrombolytic therapy), but it also can help detect early-stage acute ischemia by depicting features such as the hyperdense vessel sign, the insular ribbon sign and obscuration of the lentiform nucleus. The last two features are caused by a loss of contrast between gray matter and white matter on CT images⁸

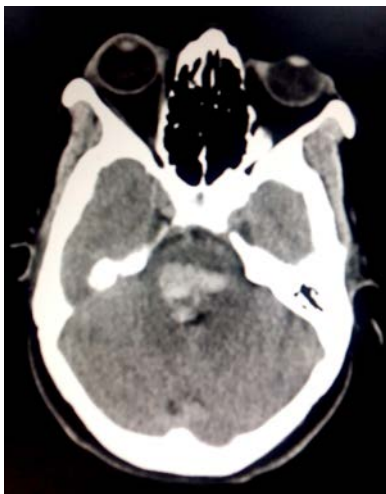

Photo-1: CT scan of the brain showing acute brain stem haemorrhage.

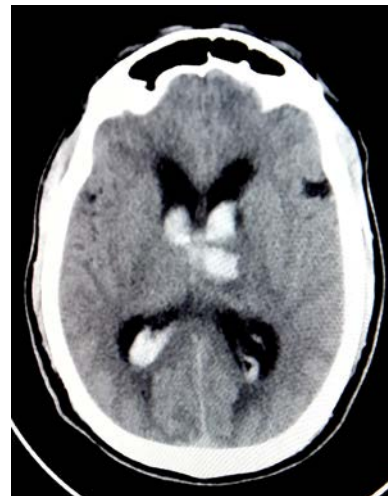


Photo-2: CT scan of the brain showing acute thalamic haemorrhage with ventricular extension.

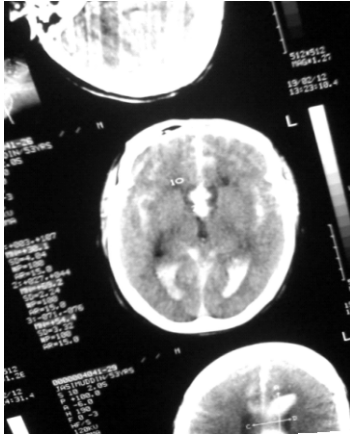


Photo-3: CT scan of the brain showing acute subarachnoid and intraventricular haemorrhage.

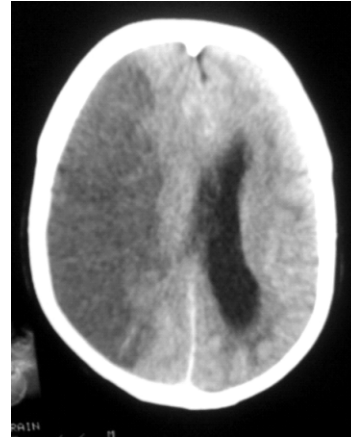


Photo-4: CT scan of the brain showing fronto-parietal infarct.

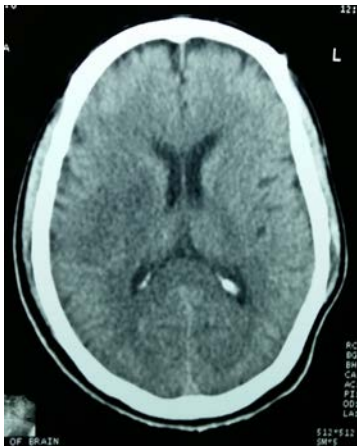

Photo-5: CT scan of the brain showing loss of insular ribbon sign.

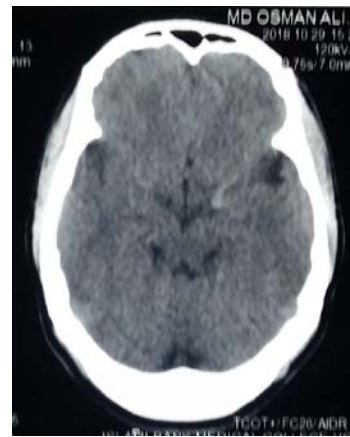

Photo-6: CT scan of the brain showing hyperdense artery sign.

An acute thrombus in an intracranial vessel typically has high attenuation. This feature is referred to as the hyperdense vessel sign (in cases of middle cerebral artery [MCA] involvement, hyperdense MCA sign) (Fig 2). Although this sign is highly specific, its sensitivity is poor.⁹ A hyperdense MCA sign also may be seen in the presence of a high hematocrit level or MCA calcification, but in such cases the hyperattenuation is usually bilateral.¹⁰ Rarely, fat emboli appear hypoattenuated when compared with attenuation in the contralateral vessel¹¹

Acute ischemia of the lenticulostriate territory may result in obscuration of the lentiform nucleus, which appears hypoattenuated because of cytotoxic edema (Fig 3). This feature may be seen on CT images within 2 hours after the onset of a stroke.¹² Cytotoxic edema of the insular cortex, which is susceptible to early and irreversible ischemic damage, also causes local hypoattenuation, which is called insular ribbon sign (Photo -5)¹³

In the present study 321 patients of stroke were analyzed and of them 65.11% patients had infarct, 30.84% patients had parenchymal haemorrhage, 4.05% patients had subarachnoid haemorrhage. These

findings of the study in relation to infarct and haemorrhage were almost similar to the studies reported by Kumar *et al* who found 60% infarcts, 30% haemorrhage and 8% subarachnoid haemorrhage.¹⁴

Hans Peter Harring *et al* found that in a series of patients with MCA territory infarctions the incidence of positive findings was 68% in cerebral CT scans performed within 2 hours of stroke onset increasing to 89% within 3 hours, thus emphasizing the great value of emergency cerebral CT scanning in acute stroke management, which is superior to MRI.¹⁵

At onset, hematoma is commonly seen as uniform and smooth hyperdense signals on CT. Over the course of the first 48 hours, large hematomas tend to show fluid levels, indicating that they are not solidified yet.¹⁶ CT scan is also able to determine the approximate age of hematomas, by evaluating for the density of the lesions measured in Hounsfield units, according to the value of x-ray attenuation corrected for the attenuation coefficient of water. The Hounsfield units for water is equal to 0, blood is between 30 and 45, gray substance is between 37 and 45, white substance is between 20 and 30, whereas bone is between 700 and 3000.¹⁷

Our study was to evaluate the role of CT scan in patients presenting with acute cerebrovascular accident in differentiating between haemorrhagic stroke and ischaemic stroke.

Conclusion:

CT scanning is the “Gold standard” technique for diagnosis of acute stroke as the rational management of stroke depends on “accurate diagnosis” and it should be ideally done in all cases. The recognition of acute ischemic stroke and its early signs are crucial for physicians and patients. The CT signs are needed for proper interpretation and consideration of patient’s clinical status. It is important to improve detection of early signs in acute stroke in non-contrast computed tomography, which is still the first choice of imaging. The capability of detecting early signs can happen only with continuous education and training of physicians. Given the fact that stroke is the third leading cause of death, skill in CT findings should be an imperative for radiologists and neurologists.

References

- Alawneh JA, Clatworthy PL, Morris RS, Warburton E. 2011. Stroke management. *Clin Evid* 6: 201.
- The world health report. Geneva: World Health Organization. 2004.
- Lloyd-Jones D, Adams RJ, Brown TM, Carnethon M, Dai S, De Simone G, et al. 2010. Executive summary: heart disease and stroke statistics-2010 update: a report from the American Heart Association. *Circulation* 121: 948–54.
- Osborn AG. 2013. Arterial Anatomy and Stroke. In: *Brain Imaging, pathology and anatomy*. Salt Lake City, Utah: Amirsys Pub.169-214.
- Sandercock P, Molyneux A, Warlow C. 1985. Value of computed tomography in patients with stroke: Oxfordshire Community Stroke project. *BMJ* 290:193-97.
- Kundu SS, Noor N, Jalali MA, Ali J, Ramiz S, Haque S, Dey UK. 2014. Computed tomographic findings in clinically diagnosed stroke patients. *Bangladesh journal of radiology and imaging*. **18(2)**: 44-48.
- Rishikant Sinha, Ahmad Rizwan Karim. 2017. Role of Computed Tomography in Evaluation of Cerebrovascular Accidents. *Annals of International Medical and Dental Research* 3 (2): 35-39.
- Tomandl BF, Klotz E, Handschu R, Stemper B, Reinhardt F, Huk WJ, Eberhardt KE, Fateh-Moghadam S. 2003. Comprehensive imaging of ischemic stroke with multisection CT. *RadioGraphics* 23(3):565–92.
- Leys D, Pruvo JP, Godefroy O, Rondepierre P, Leclerc X. 1992. Prevalence and significance of hyperdense middle cerebral artery in acute stroke. *Stroke* 23:317–324.
- Von Kummer R, Meyding-Lamade U, Forsting M, Rosin L, Rieke K, Hacke W et al. 1994. Sensitivity and prognostic value of early CT in occlusion of the middle cerebral artery trunk. *AJNR Am J Neuroradiol* 15:9–15.
- Lee TC, Bartlett ES, Fox AJ, Symons SP. 2005. The hyperdense artery sign. *AJNR Am J Neuroradiol* 26:2027–29.
- Tomura N, Uemura K, Inugami A, Fujita H, Higano S, Shishido F. 1988. Early CT finding in cerebral

- infarction: obscuration of the lentiform nucleus. Radiology 168:463-67.
13. Truwit CL, Barkovich AJ, Gean-Marton A, Hibri B, Norman D. 1990. Loss of the insular ribbon: another early CT sign of acute middle cerebral artery infarction. Radiology 176: 801-06.
 14. Kumar LT, Gore VN and Patil GC. 2016. The role of computed tomography in the evaluation of cerebrovascular accidents. International Journal of Research in Medical Science 4(10):4305-4309.
 15. Weisberg LA. 1990. How to identify and manage brain haemorrhage? Post Graduate Medicine. 88(3): 169-175.
 16. Zilkha A. 1983. Intraparenchymal fluid-blood level: a CT sign of recent intracerebral hemorrhage. J Comput Assist Tomogr.7:301-305.
 17. Feeman TG. 2010. The Mathematics of Medical Imaging: A Beginner's Guide. New York: Springer. 51 (12):66-75.

All correspondence to
Dr. Md. Durul Huda
Assistant Professor
Department of Radiology and Imaging
Rajshahi Medical College
Email: duruldr68@gmail.com