



Original Article

Ultrasound Guided Needle Aspiration of Breast Abscess as an Alternative to Surgical Incision and Drainage

Md. Nowshad Ali,¹ Md. Abdul Hannan,² Shah Md. Ahsan Shahid,³
Taibatul Kubba,⁴ Dipankar Roy⁵

Abstract

Breast abscess is the localized collection of pus in breast tissue. Various treatment protocols used now a day like oral drugs, hot compression, surgical incision and drainage and ultrasound guided needle aspiration. Aim of this article was to identify the ultrasound guided needle aspiration of breast abscess is an alternative to surgical incision and drainage by analysis of previous study reports. It was found that though ultrasound guided aspiration of breast abscess has some benefit than traditional surgical drainage but it not applicable for all cases.

Keywords: Ultrasound guided needle aspiration, breast abscess, surgical incision and drainage

TAJ 2020; 33: No-1: 01-04

Introduction

Breast is a tear-shaped organ which undergoes cyclical changes under the influence of hormone throughout the reproductive life of a woman. Both benign and malignant lesion can be found in the breast, but majority of the breast lesions are benign. The significance of this entity is that around 50% of women in their life time experience the sign/symptom of benign breast disease.¹ Breast abscess is an inflammatory disease which is most commonly found in females than males. Incidence of breast abscess in Bangladesh is not clearly documented.

The global prevalence of mastitis in lactating women is approximately 1-10% but may be higher. Duct ectasia (periductal mastitis or dilated ducts associated with inflammation) occurs in 5-9% of non-lactating women. Breast abscess

develops in 3-11% of women with mastitis, with a reported incidence of 0.1-3% in breastfeeding women. Approximately 50% of infants with neonatal mastitis develop breast abscess.²

Definition

Breast abscess may be defined as the localized collection of inflammatory exudates (ie, pus) in the breast tissue. It is the first presentation of breast infection. Breast abscesses develop most commonly when mastitis or cellulitis does not respond to conservative treatment. Breast abscess can occur as primary (no other disease) or secondary causes like periductal mastitis, skin infection over the breast or granulomatous lobular mastitis.

Etiology

Most common organism causing breast abscess is the *Staphylococcus aureus*. Breast infections may

¹ Professor & Head, Department of Pediatric Surgery, Rajshahi Medical College, Bangladesh.

² Associate Professor, Department of Surgery, Rajshahi Medical College, Bangladesh.

³ Assistant Professor, Department of Pediatric Surgery, Rajshahi Medical College, Bangladesh.

⁴ M. Phil Fellow (Radiology & Imaging), Rajshahi University.

⁵ Medical Officer, Civil Surgeon's Office, Lalmonirhat.

sometimes (up to 40% of abscesses) be polymicrobial, with isolation of aerobes (Staphylococcus, Streptococcus, Enterobacteriaceae, Corynebacterium, Escherichia coli, and Pseudomonas) as well as anaerobes (Peptostreptococcus, Bacteroides, Lactobacillus, Eubacterium, Clostridium, Fusobacterium and Veillonella). More unusual pathogens may include Bartonella henselae (the agent of cat scratch disease), mycobacteria (TB and atypical mycobacteria), Actinomyces, Brucella, fungi (Candida and Cryptococcus), parasites, and maggot infestation. Unusual breast infections may be the initial presentation of HIV infection.

Classification of breast abscess

For clinical relevance and for planning treatment breast abscess is classified as:

- **Puerperal abscess:** seen in primiparous mothers
- **Non-puerperal central abscess:** commonest non-breastfeeding abscess, seen mostly in young women; especially smokers

Non-puerperal peripheral abscess: less commonly seen. Seen in older women with underlying chronic medical conditions like diabetes, rheumatoid arthritis; women taking steroids or underwent a recent breast intervention.

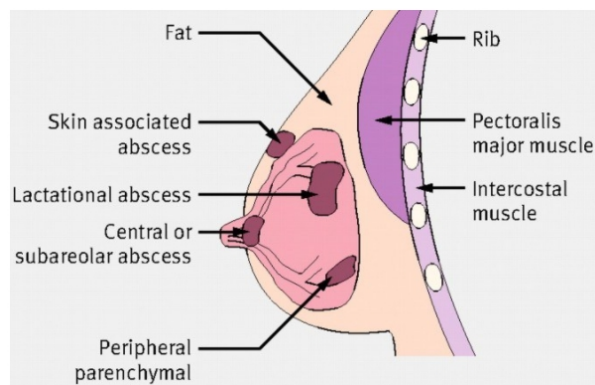


Figure-1: Sites of different types of breast abscess

Risk factors

Risk factors strongly associated with mastitis include:

- Female gender

Age 15 to 45 years or adolescence

Infants <2 months of age

Lactation, particularly after 6 to 8 weeks of breastfeeding or at weaning

Poor breastfeeding technique (may also be due to infant factors such as tongue-tie)

Milk stasis (may be secondary to poor breastfeeding technique or tight-fitting bra)

Nipple injury

Previous mastitis

- Shaving or plucking areolar hair
- Anatomic breast defect, mammoplasty, or scar
- Other underlying breast condition, particularly breast cancer
- Nipple piercing
- Foreign body (e.g. silicone implant)
- Skin infection
- Positive carrier status for *Staphylococcus aureus*
- Presence of a hospital-acquired infection
- Immunosuppression (including diabetes mellitus).

Breast abscess is strongly associated with prolonged mastitis and prior breast abscess.

These factors need to be specifically considered when a patient history is taken.

Treatment

Traditionally, breast abscesses were managed via incision and drainage with antibiotic therapy but this treatment strategy is associated with a prolonged healing time, regular dressings and unsatisfactory cosmetic outcomes.³ Ultrasound guided drainage is now considered as first-line treatment.

Sonographic features suggestive of a breast abscess include

- hypoechoic collection, mostly multiloculated
- no vascularity within the collection
- acoustic enhancement due to fluid content

- an echogenic, vascular rim.⁴

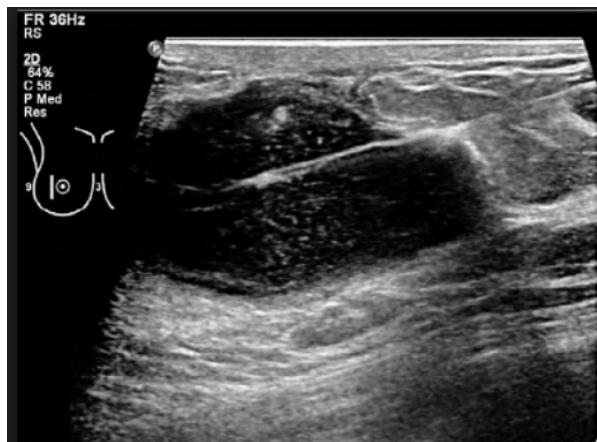


Fig-2: Ultrasonographic aspiration of breast abscess.

Previous Study Report

Various studies were done regarding ultrasound guided aspiration of breast abscess. A study was conducted in Copenhagen, Denmark to identify the efficacy of ultrasound-guided drainage of breast abscess with special attention to the risk of recurrence and the need for surgical treatment in a consecutive patient. In this study 86 (97%) out of 89 patients with puerperal abscesses and 50 (81%) out of 62 with non-puerperal abscess recovered after the first round of ultrasound-guided drainage. This study also concludes that sonographic aspiration method is less invasive than traditional surgery and has a high rate of success.⁵ Some other studies also reported more than 90% recovery rates in ultrasound-guided drainage.⁶⁻⁹

A comparative study was done regarding the management of puerperal breast abscess by percutaneous ultrasound guided needle aspiration versus open surgical drainage. This study reported that failure rate for aspiration technique was 17.14% with 06 patients requiring conversion to open surgical drainage after aspiration. The resolution time was less in aspiration group. Painful and cumbersome daily changes of dressing, mammary fistula in 3 patients with ugly scar were the main drawback of open surgical drainage. 82.86% cure rate was found in percutaneous ultrasound guided aspiration of breast abscess.¹⁰

Faisal Elagili et al. reported their study fifty (50%) patients required only a single aspiration, 10 required multiple aspirations and five required incision and drainage. Those patients in whom needle aspiration failed had multi-loculated lesions irrespective of abscess volume and size. They also reported that needle aspiration with ultrasound guidance is an effective treatment for breast abscess irrespective of abscess volume and size.¹¹

Conclusion

Still now open surgical drainage is the main stream treatment in Bangladesh aspect. The side effects of this treatment include scarring and impairment of breast-feeding. Ultrasound-guided drainage causes less scarring, does not affect breast-feeding and does not require general anaesthesia or hospitalization.¹² Ultrasound-guided drainage is a less expensive procedure than surgery.¹³ Considering above mentioned advantage and results of previous study ultrasound guided aspiration of breast abscess should be routinely practiced.

References

1. Naveen N, Mukherjee A, Mahajan V. A clinical study of benign breast disease in rural population. *J Evol Med Dent Sci.* 2013; 2(30): 5499-511.
2. <https://online.epocrates.com/diseases/108423/Mastitis-and-breast-abscess/Epidemiology> [Accessed on 30/11/2018]
3. Benson EA. Management of breast abscesses. *World J Surg* 1989; 13:753-756.
4. <https://radiopaedia.org/articles/breast-abscess> [Accessed on 30/11/2018].
5. A F Christensen, N Al-Suliman, K R Nielsen, I Vejborg, N Severinsen, H Christensen, M B Nielsen. Ultrasound-guided drainage of breast abscesses: results in 151 patients. *The British Journal of Radiology.* 78 (2005), 186-188.
6. Hook GW, Ikeda DM. Treatment of breast abscesses with US-guided percutaneous needle drainage without indwelling catheter placement. *Radiology* 1999; 213: 579-82.
7. Karstrup S, Solvig J, Nolsoe CP, et al. Acute puerperal breast abscesses: US-guided drainage. *Radiology* 1993; 188:807-9.

8. Blaivas M. Ultrasound-guided breast abscess aspiration in a difficult case. *Acad Emerg Med* 2001; 8:398–401.
 9. Karstrup S, Nolsoe C, Brabrand K, Nielsen KR. Ultrasonically guided percutaneous drainage of breast abscesses. *Acta Radiol* 1990; 31:157–9.
 10. Kaushal D Suthar, Bhavna N Mewada, Keyur N Surati, Jainam K Shah. Comparison of percutaneous ultrasound guided needle aspiration and open surgical drainage in management of puerperal breast abscess. *International Journal of Medical Science and Public Health*. 2013; 2(1): 69-72.
 11. Faisal Elagili, Norlia Abdullah, Liew Fong 1 and Tan Pei, 1. Aspiration of Breast Abscess Under Ultrasound Guidance: Outcome Obtained and Factors Affecting Success. *Asian J Surg* 2007; 30(1):40–4.
 12. Schwarz RJ, Shrestha R. Needle aspiration of breast abscesses. *Am J Surg* 2001; 182:117–9.
- Imperiale A, Zandriono F, Calabrese M, Parodi G, Massa T. Abscesses of the breast: US-guided serial percutaneous aspiration and local antibiotic therapy after unsuccessful systemic antibiotic therapy. *Acta Radiologica* 2001; 42:161.

All correspondence to
Prof. Md. Nowshad Ali
Professor and Head
Department of Pediatric Surgery
Rajshahi Medical College, Rajshahi
Email: nowshadrokeya@gmail.com