



Original Article

Modified Volar Oblique Triangular Flap for Coverage of Fingertip Defects

Md. Salek Bin Islam,¹ Afroza Nazneen,² Ahmed Asif Iqbal,³
Md. Noazesh Khan,⁴ Asim Sarkar,⁵ Md. Jalaluddin⁶

Abstract

Fingertip includes the portion of the digit which is distal to the insertion of flexor digitorum profundus (FDP) tendon and the extensor tendon. It is the most vulnerable part of the hand to be injured. So, reconstruction of this part requires a good outcome in sensation and function. To meet the goal of the reconstruction principle, "Like with Like" local flap is the most preferable. Such type of flap is a Volar oblique triangular flap based on volar perforator vessels from the Digital artery proper. The aim of the study is to identify its reconstruction outcome in viability, sensation, range of movement of DIPJ, and patients' satisfaction regarding contour.

This was a prospective observational study; ten patients were included who were admitted in the Burn and Plastic surgery Department of Rajshahi Medical College Hospital, Rajshahi, from September 2019 to December 2020.

Thirteen flaps were harvested to cover for the fingertip defect of ten patients; among them, three were female. The age range of our operated patient was 2- 38 years. None of the flaps was lost except marginal necrosis or epidermal loss. The range of movement of DIPJ and 2SPD were within the normal limit. Patients were satisfied with their contour.

So, the modified volar oblique, triangular flap is one of the good options for fingertip defects.

TAJ 2021; 34: No-1: 63-69

Introduction

Fingertip includes the portion of the digit which is distal to the insertion of FDP tendon and the extensor tendon.¹⁻³ It is the most sensible portion of the hand, even in human body³⁻⁵ and volar pulp is more than half (56%) of the fingertip.^{3,6} So reconstruction of this part requires good outcome in sensation and function. A thick volar epidermis of fingertip has deep papillary ridges making the fingerprint and the underlying vascularized

fibrofatty pulp gives unique contour of the fingertip.³ So it deems aesthetic outcome in reconstruction too.

Fingertip most vulnerable part of the hand to be injured.^{1,3} According to Fassler geometry classification fingertip may be injured transverse, radial or ulnar oblique and volar or dorsal oblique.^{1,7} Though availability of adjacent tissue is less, a wide range of reconstruction procedures are available, ranging from STSG to distant flap. To

¹ Associate Professor, Department of Burn and Plastic Surgery. Rajshahi Medical College.

² Associate Professor and Head, Department of Burn and Plastic Surgery. Rajshahi Medical College.

³ Associate Professor, Department of Hand and Microsurgery Department, Rajshahi Medical College.

⁴ Professor, Plastic Surgery, Sheikh Hasina National Institute of Burn and Plastic Surgery, Dhaka.

⁵ Registrar, Department of Burn and Plastic Surgery. Rajshahi Medical College Hospital.

⁶ Department of Burn and Plastic Surgery. Rajshahi Medical College Hospital.

meet the goal of the reconstruction principle, "Like with Like" local flap is the most preferable. Such type of flap is a Volar oblique triangular flap based on volar perforator vessels from the Digital artery proper. This flap was first described by Venkataswami R et al.^{3,8} in 1980 based on digital artery proper neurovascular bundle. In this study, we modified this flap based on tiny volar perforators to achieve more advancement. The aim of the study is to identify its reconstruction outcome in viability, sensation, range of movement of DIPJ, and patients' satisfaction regarding contour.

Materials and Methods

Patients and data collection:

In this prospective observational study, ten patients were included who were admitted in Burn and Plastic surgery Department of Rajshahi Medical College Hospital, Rajshahi, from September 2019 to December 2020. All these patients had fingertip injury with exposed distal phalanx without any life-threatening condition. After proper preoperative management and consent were taken from the patients, wound size, sites, type of injury were assessed in the operation theater, under good light and anesthesia with all aseptic precautions. Then flap design was done. All patients were discharged on the first postoperative day with advice to keep the injured upper limb elevated. We assessed the viability of the flap on the 5th postoperative day, and sutures were removed on 10 to 14th postoperative day. Evaluation of static two-point discrimination, range of movement of distal phalangeal joint, and satisfaction of patients or patient's parents regarding contour finger pulp were done in first and third postoperative months. All data were recorded in the Patient datasheet, and data analysis was done by Microsoft Excel 2010.

Surgical technique:

We used general anesthesia and arm tourniquet for children and digital block and digital tourniquet for adult patients. After wound excision and trimming of the exposed distal phalanx, the flap was designed. Here, we didn't shorten the bone. Flaps were triangular in shape on the volar aspect,

having a base and two limbs. The direction and length of "Base" were corresponding to that of the base of the wound. Long arm of the triangle was a long lateral axial line of the finger which was contralateral side of the defect to take more tissue in case of oblique fingertip defect and in case of a transverse defect, either ulnar or radial lateral axial line of finger. And short arm was oblique from the base of the wound to the long arm and met at a point that was proximal to DIPJ. The length of long arm depended on the degree of advancement, which was 1.5 to 2.5 times of base of the defect.

The first incision was made along the long arm, and up to fibrofatty tissue and perforators from digital artery proper was identified. Then oblique arm was incised, and the whole flap was separated from the flexor sheath. During the elevation of the flap, the fibrous band was divided carefully to preserve the perforators. Here, we tried to preserve perforators arising from both digital artery proper. After adequate mobilization of the flap, tensionless closure was done with 5-0 prolene. After giving Vaseline gauze and puffy dressing on the flap, volar short arm splint was given an elevation of injured upper limb was done by collar and cuff sling.

Results:

Thirteen flaps were harvested to cover for the fingertip defect of ten patients; among them, three were female. Three patients had been operated on two digits of the same hand. Age range of our operated patient was 2- 38 years, and the median age was 22.5 (\pm 13.39) years. All the fingers, including the thumb (of a patient) and both hands, were operated on in our studied patients. Most of the cause of fingertip injury was Electrical burn (40%) and machinery injury (40%), shown in Table 1. Machinery injury was occurred due to accidental entrapment of finger in the belt in the rolling machine. We covered all types of defects according to geometry fingertip injury classification. Table 2 showed the characteristics of the defect. Mean defect area and flap sizes were 3.15 (\pm 0.79) cm² and 6.29 (\pm 1.72) cm², respectively. Most (54.34%) of the wound was healed without any flap loss. Four flaps had a

marginal loss (< 2 mm), and two flaps had only epidermal loss; Table 3. None was required any secondary procedure. Only 4 patients developed 5 to 10 degrees restriction of active extension at DIPJ. All patients had good static two-point discrimination; ranging from 5- 3 mm, which was normal according to American Hand Surgery Society. We assessed patient's or pediatric patient's 1-5 scale of satisfaction regarding contour of the

fingertip and were divided them into four categories; Excellent (5/5), Good (4/5), Fair (3/5), and Poor (1/5 or 2/5). None had poor satisfaction and near one-fourth had excellent satisfaction. We also measured the correlation between flap survivability to 2 SPD and level of satisfaction and found no significant difference between any loss group and the other two groups, and the result was shown in Table 4 and Table 5, respectively.

Table1: Demographic distribution:

Variables

Age	Range	2-38 years
	Mean (SD)	22.5 (\pm 13.39) years
Sex	Male	7
	Female	3
Etiology of wound	Electrical burn	4 (40%)
	Machinery burn	4 (40%)
	Post infective	1(10%)
	Sharp weapon	1(10%)

Table2: Cases and characteristics of the defect

Case no	Age (years)	Injure d fingers	Wound type	Wound length (cm)	Wound width (cm)	wound size (cm ²)	Flap Length (cm)	Flap width(cm)	Flap size (cm ²)
1	22	Ring	Ulnar oblique	1.8	1.5	2.7	4.5	1.5	6.75
2	6	Ring	volar oblique	2	1.8	3.6	3.6	1.8	6.48
3	34	Middle	volar oblique	2.5	1.5	3.75	5	1.5	7.5
4	6	Index	Radial oblique	2.5	1.3	3.25	3.75	1.3	4.88
5	38	Little	Ulnar oblique	2.3	1.5	3.45	4.6	1.5	6.9
6	22	Ring	Radial oblique	2.8	1.7	4.76	4.2	1.7	7.14
7	28	Middle	dorsal oblique	1.7	1.8	3.06	4.25	1.8	7.65
		Ring	Radial oblique	1.6	1.6	2.56	4	1.6	6.4
8	2	Middle	Ulnar oblique	1.5	1	1.5	2.55	1	2.55
		Thumb	Radial oblique	2	1.2	2.4	3	1.2	3.6
9	32	Index	Radial oblique	1.8	2	3.6	4.5	2	9
		Middle	Radial oblique	2	1.4	2.8	5	1.4	7
10	35	Index	Radial oblique	2.4	1.5	3.6	4.32	1.4	6.05

Table3: outcome of flaps:

Variables	Frequency	Percentage
Survivability of flaps		
No loss	7	53.85%
Epidermal loss	2	15.38%
Marginal loss (< 2mm)	4	30.77%
ROM of DIPJ		
Normal	9	63.23%
5degree extension lag	3	23.08%
10degree extension lag	1	7.69%
Patient's satisfaction of contour		
Excellent	3	23.08%
Good	6	46.16%
Fair	4	30.77%
Poor	0	0
Two static point discrimination (2SPD)		
Mean	3.65 mm	
SD	±0.63 mm	

Table 4: Comparison of 2SPD among different groups

Group	Mean (SD) mm	p-value (student's t-test)
No loss	3.5(±0.5)	
Epidermal loss	3.5(±0.71)	1(NS)
Marginal loss	4.0(±0.82)	0.233 (NS)

NS: Non-significant

Table 5: Comparison of Satisfaction of contour of fingertip among different groups

Group/ Level of Satisfaction (Frequency)	Excellent	Good	Fair	X2 test
No loss	3	3	1	
Epidermal loss	1	0	1	0.062 (NS)
Marginal loss	1	2	2	0.814 (NS)

NS: Non significant

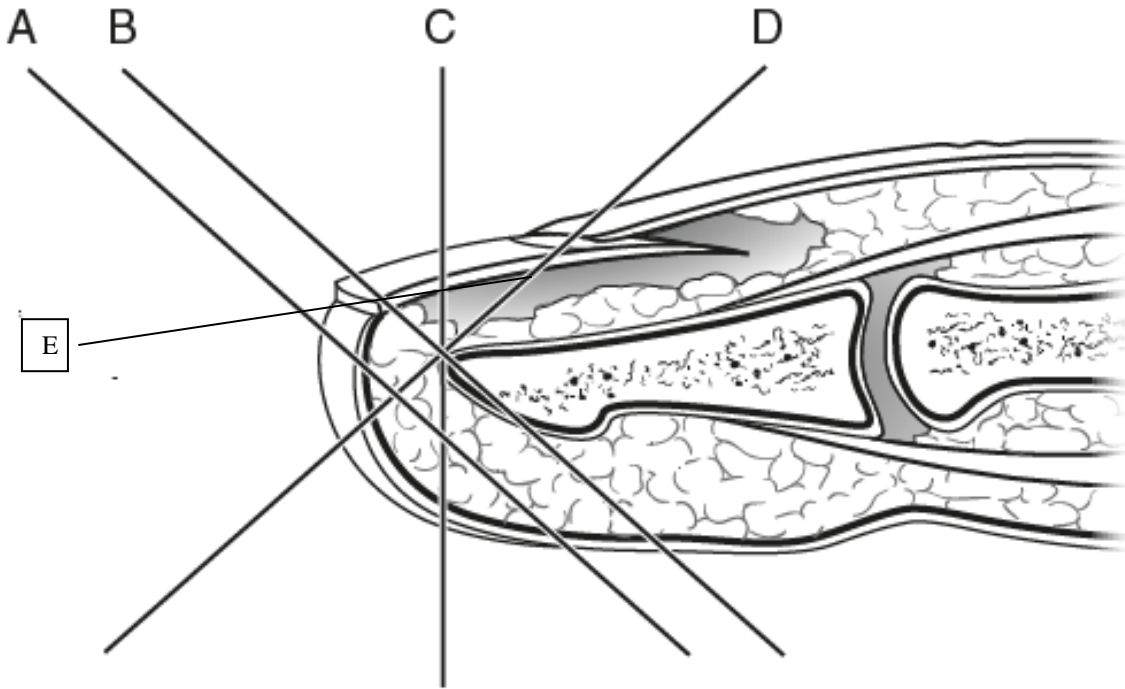


Figure 1: Fessler's geometric classification of fingertip (A: Volar oblique without exposed bone; B: Volar oblique with exposed bone; C: Transverse; D: Dorsal oblique; E: Lateral oblique)

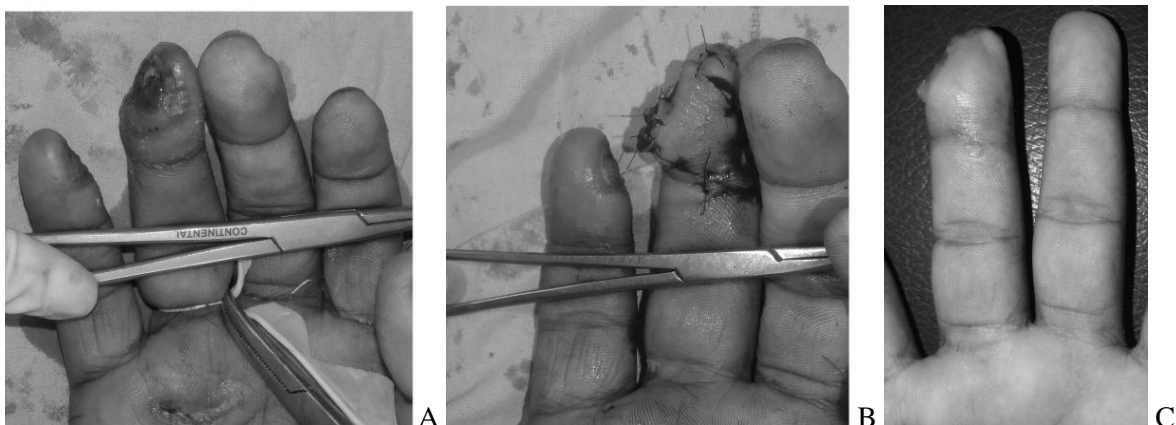


Figure 2: 21 years old man Lateral (Ulnar) oblique defect of right ring finger following electrical burn (A. Site of defect; B: Immediate postoperative and C. 3rd postoperative week picture)

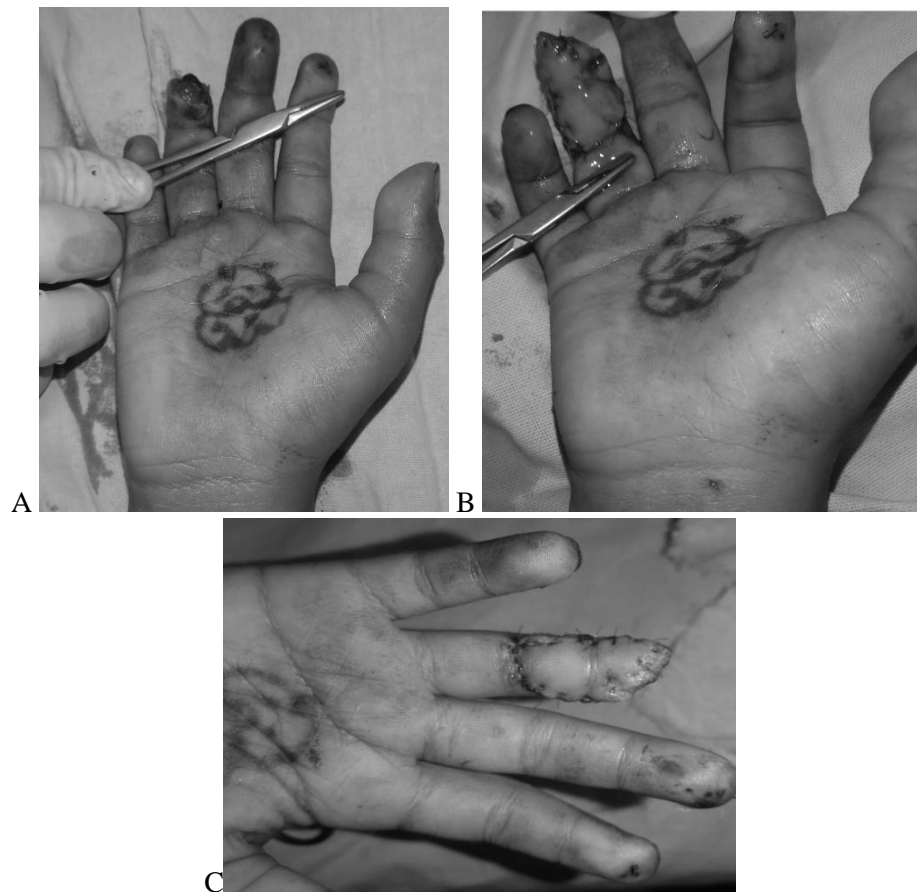


Figure3: 6 years old boy with right ring finger transverse fingertip injury due to machinery injury (A. Defect; B. Immediate postoperative and C. 7th postoperative picture)

Discussion

Fingertip is the common injury in this modern mechanized world, and the aims of the reconstruction are to provide durable coverage, to preserve sensation and length, and good aesthetic contour.³ To meet these aims, a wide range of reconstruction options. 1.5 cm^2 wound may be healed by secondary intention.^{3,9-14} Skin graft is another option for reconstruction for wounds larger than 1.5 cm^2 , and distal phalanx is not exposed.^{3,15-16} So, when the fingertip comes with exposed bone, flap coverage is the ultimate option to achieve the goal.

Many local, regional, distant flaps or homodigital or heterodigital flaps have been described for fingertip defect coverage in literature. Among

these, volar oblique triangular flap is one of the useful options and was first described by Venkataswami R et al.⁸ We have modified Venkataswami R et al. described flap few aspects. We harvested the flap on volar perforators of Digital artery Proper, but Venkataswami R et al. include either of neurovascular bundle. Another modification was the size of the flap. Length of long arm was 1.5 to 2.5 times larger than the base of defect in our study that was 2 to 2.5 times in Venkataswami R et al. described flap. So, flap size was lesser than that of Venkataswami R et al. described flap to cover the same size of the defect. It might be greater mobility achieved due to the flap was based on perforator vessels. Though Venkataswami R et al. used this flap for only oblique amputation, but in our study, we used the

flap for both oblique and transverse fingertip defect.

Survivability of modified volar oblique triangular flap was good. Only one patient developed 10 degrees active extension lag but had a full range of passive extension. It was due to non-compliance of the patient, but it is acceptable due to the American Society for Surgery of Hand. On third postoperative month, 2 SPD became normal in all patients and no significant alteration marginal loss and epidermal loss group. Overall, all patients and in the case of pediatric patients, parents were satisfied regarding the contour of the fingertip.

Conclusion:

Modified volar oblique triangular flap based on tiny perforators has the advantage of escaping disturbing the main neurovascular bundle. Not only that, this flap can cover all sorts of fingertip defects and also has a good outcome both functionally and aesthetically. So, the modified volar oblique triangular flap is one of the useful options for fingertip defects.

References

1. Fassler PR. Fingertip injuries: Evaluation and treatment. *J Am Acad Orthop Surg* 1996; 4: 84,
2. Yeo CJ, Sebastin SJ, Chong AK. Fingertip injuries. *Singapore Med J*. 2010; 51:78–86; quiz 87.
3. Lemmon JA, Janis JE, Rohrich RJ. Soft-Tissue Injuries of the Fingertip: Methods of Evaluation and Treatment. An Algorithmic Approach. *Plast Reconstr Surg* 2008;122: e105-117.
4. Chau N, Gauchard GC, Siegfried C. Relationships of job, age, and life condition with the causes and severity of occupational injuries in construction workers. *Int. Arch. Environ Health* 2004; 77: 60
5. Sorock GS. Acute traumatic occupational hand injuries: Type, location, and severity. *J Occup Environ Med* 2002; 44: 345
6. Murai M, Lau H-K, Pereira BP, and Pho RWHA. cadaver study on volume and surface area of the fingertip. *J Hand Surg (Am.)* 1997; 22: 935
7. Zhou J-L, Zhao Q, Zhang Y-L, Zhao D-H, Li Y-H, Xu L. A New Triangular Rotation and advancement Pulp Flap for lateral Oblique Fingertip Defect. *Plast Reconstr Surg Glob Open* 2020;8: e30-33
8. Venkataswami R, and Subramanian N. Oblique triangular flap: A new method of repair for oblique amputations of the fingertip and thumb. *Plast Reconstr Surg* 1980;66: 296
9. Mennen U, and Wise A. Fingertip injuries management with semiocclusive dressing. *J Hand Surg. (Br.)* 1993;18: 416
10. Chow SP, and Ho E. Open treatment of fingertip injuries in adults. *J Hand Surg (Am.)* 1982; 7: 470
11. Louis DS, Palmer AK, and Burney RE. Open treatment of digital tip injuries. *JAMA* 1980; 244: 697
12. Ipsen T, Frandsen PA, and Barfred, T. Conservative treatment of fingertip injuries. *Injury* 1987;18: 203
13. Buckley SC, Scott S, and Das K. Late review of the use of silver sulphadiazine dressings for the treatment of fingertip injuries. *Injury* 2000; 31: 301
14. Lee LP, Lau PY, and Chan CW. A simple and efficient treatment for fingertip injuries. *J Hand Surg (Br.)* 1995; 20: 63
15. Patten HS. Split skin graft from the hypothenar area for fingertip avulsion. *Plast Reconstr Surg* 1968; 43: 426
16. Holm A, and Zachariae L. Fingertip lesion: An evaluation of conservative treatment versus free skin grafting. *Acta Orthop Scand* 1974;45: 382

All correspondence to
Dr. Md. Salek Bin Islam
 Associate Professor
 Department of Burn and Plastic Surgery
 Rajshahi Medical College
 Email: salekbinislam@gmail.com