

CASE REPORT

A Giant Arteriovenous Malformation Involving Tongue, Neck and Face

MD. SAIF ULLAH KHAN¹, MD. MAHBUBUR RAHMAN¹, DIPAL KRISHNA ADHIKARY²

¹Department of Vascular Surgery, Bangabandhu Sheikh Mujib Medical University, Dhaka, ²Department of Cardiology, Bangabandhu Sheikh Mujib Medical University, Dhaka.

Address for Correspondence: Dr Md Saif Ullah Khan, Assistant Professor, Department of Vascular Surgery, Bangabandhu Sheikh Mujib Medical University, Dhaka. E-mail: drsaifkhanmurad@yahoo.com

University Heart Journal 2017; 13(1): 26-28

Introduction:

Vascular malformations result from abnormal-sized vascular structures or an abnormal number of vascular structures. Vascular anomalies are a diffuse collection of vascular abnormalities that are present at birth or soon after. Historically the terminology has been complicated, descriptive, difficult to understand and a barrier to communication between specialties. The International Society for the Study of Vascular Anomalies (ISSVA) was founded after 16 years of biennial meetings with the primary goal of improving the understanding of these abnormalities. ISSVA adopted the biological classification system developed by Mulliken & Glowacki published in 1982.¹ This classification differentiated vascular anomalies due to their endothelial cell characteristics and clinical behaviour. It simply distinguished two main types of vascular anomalies: vascular tumours (grow by cellular mainly endothelial hyperplasia) and vascular malformations (localised defects in vascular morphogenesis caused by dysfunction in embryogenesis and vasculogenesis). All AVMs are present at birth, but they are not always clinically evident. Although the pathogenetic mechanisms of AVMs are not completely understood, the hemodynamic alterations that lead to the clinical manifestations of AVMs have been described well. An abnormal communication causes shunting of blood from the high-pressure arterial side to the low-pressure venous side. This creates an abnormal low-resistance circuit that steals from the high-resistance normal capillary bed.

Transcatheter embolization of vascular malformations became an extremely valuable option in the treatment of these frequently complex and deeply seeded anomalies. This modality can be effectively applied alone, prior to, or in combination with surgical resection when the vascularity of the malformation must be reduced.

Most AVMs are not amenable to complete surgical excision. A lesion must be well localized for a chance at complete resection. Resectability depends on the degree of extension into adjacent structures.

A variety of percutaneous sclerotic and transarterial embolizing agents have been advocated in numerous combinations, depending on location, severity and the extent of the malformations. Absolute ethanol, bleomycin, 3% sodium tetradecyl sulfate (STS), polidocanol, ethanolamine oleate, n-butyl cyanoacrylate, polyvinyl alcohol foam and various types of coils and polymer microspheres have all been used.^{1,2} Madani H, Farrant J, Chhaya N, et al. Peripheral limb vascular malformations: an update of appropriate imaging and treatment options of a challenging condition.²

Case Report:

A 22 year unmarried destitute women admitted in the department of vascular surgery, Bangabandhu Sheikh



Fig.-1:

Mujib Medical University (BSMMU), Dhaka, Bangladesh on march 2008 with the background history of roaming about in the highest medical institutes of the country for about seven years including BSMMU. The young lady developed small reddish-blue swelling in the tongue from early childhood. The diffuse swelling gradually extended into the whole tongue, neck, lips and left side of face. This time she was taken to the hospital by a social worker as the patient could not take even liquid food, because the enlarged tongue occluded almost whole of the mouth.

Duplex Ultrasonography

Ultrasonography with color Doppler revealed highly vascular lesion with numerous arterio-venous fistulas.




Fig.-2:

MRI:

Revealed extensive lesion involving almost whole, tongue, neck, face and thorax.

Computed tomography Angiogram

Computed tomography (CT) revealed extensive lesion involving almost whole, tongue, neck, face and thorax.

Treatment:

We decided to operate. Oro-pharyngeal intubation was not possible, so the patient undergone tracheostomy two days before definitive surgery .

Partial excision of lesion was done. Patient is under continued sclerotherapy by sodium tetradecyl sulfate for residual and growing lesions.

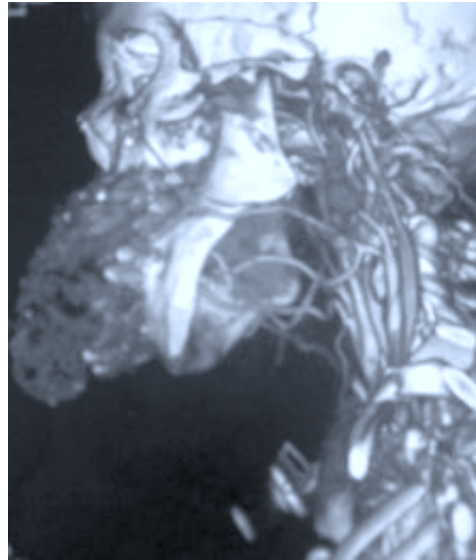


Fig.-3:

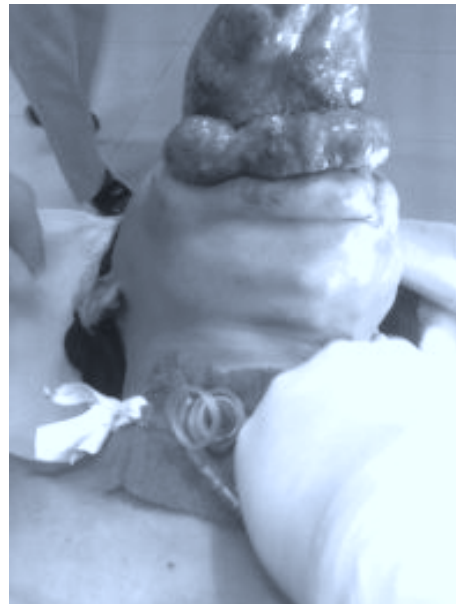

Fig.-4:

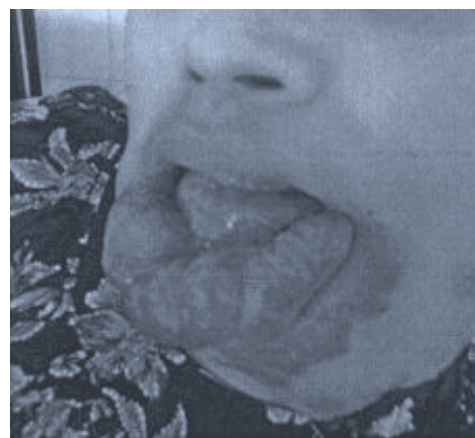


Fig.-5:

References:

1. ISSVA classification of vascular anomalies. International Society for the Study of Vascular Anomalies. Available at <https://issva.clubexpress.com/docs.ashx?id=178348>. April 2014; Accessed: August 26, 2016.
2. Madani H, Farrant J, Chhaya N, et al. Peripheral limb vascular malformations: an update of appropriate imaging and treatment options of a challenging condition. *The British Journal of Radiology*. 2015;88(1047):20140406. doi:10.1259/bjr.20140406.