

Long term Cardiovascular Manifestations of COVID - 19

KHURSHED AHMED, SUDHIR PRASAD SAH, MD. FAKHRUL ISLAM KHALED,
AFM AZIM ANWAR, MD. HARISUL HOQUE

Department of Cardiology, Bangabandhu Sheikh Mujib Medical University, Dhaka.

Address of Correspondent: Dr. Khurshed Ahmed, Associate Professor, Department of Cardiology, Bangabandhu Sheikh Mujib Medical University, Dhaka. Email: dmkahmed28@gmail.com

Abstract:

Although severe acute respiratory syndrome coronavirus 2 (SARS-CoV-2) is well known for causing an acute respiratory disease, a number of patients after they get recovered from acute infection, subsequently experience a constellation of symptoms and events that lasts for more than 3 months. Adequate clinical data are now accumulating on the subacute and long-term effects of Covid-19 and can involve multiple organ systems. This spectrum of symptoms and late manifestations are thought to have a possible link with the covid-19 and this condition is named LONG COVID or POST-COVID. Some of the patients may show the ongoing evidence of cardiovascular damage on long term without having symptoms which may be picked up by different imaging modalities like CMR. There has been an increase in the number of COVID-19 patients in an exponential fashion so as to cause a collapse in the healthcare system in many countries across the world, with an effect not only on public health, but also on social and economic activities.

Keywords: SARS-CoV-2, Covid-19, Long COVID, ACE2, Cardiovascular system

University Heart Journal 2022; 18(2): 118-124

Introduction:

Severe acute respiratory syndrome coronavirus 2 (SARS-CoV-2) is the causative organism of Coronavirus disease 2019 (COVID-19) pandemic, which has created a havoc globally. It took its origin in late Dec. 2019 in the city of Wuhan, Hubei province, china^{16,5} and since then it has taken millions of lives and resulted in significant morbidities worldwide. It was declared a pandemic by WHO on 11th March 2020, and as of 28th March 2022, more than 482 million cases have been reported worldwide with more than 4.82 million deaths.^{15,17,5} At the start of the pandemic, it was known to be a respiratory pathogen but as the pandemic is getting older, our understanding of the cardiovascular consequences of covid-19 is getting better. Available data suggest that elderly patients and those with comorbidities have adverse prognosis.^{20,10} These patients have a high risk of cardiovascular adverse events, including death from cardiovascular causes. Covid-19 patients can present acutely to the cardiac emergencies with myocardial infarction (MI), arrhythmias, cardiac arrest, heart blocks, heart failure and coagulation abnormalities. It has varied presentations ranging from asymptomatic disease to severe respiratory failure, myocardial involvement has been detected in unto 20-30% of hospitalized Covid-19 patients manifested by an elevation

in troponin levels.² As we are getting close to the end of pandemic, there are accumulating data and the increasing reports of persistent and prolonged effects after acute Covid-19.

Pathophysiology

SARS-CoV-2 is a single stranded, positive-sense RNA virus.^{24,25} The structure of SARS-CoV-2 is a nucleocapsid surrounded by a protein membrane and a lipo-containing outer cell, from which the clavate spine processes extend called "spike".^{26,1} It uses its spike protein to attach to host cells using the angiotensin-converting enzyme 2 (ACE2) as its receptor for membrane fusion.^{30,33} The spike protein contains 2 functional subunits. The S1 subunit contains the receptor-binding domain that binds to ACE2 and the S2 subunit is responsible for the fusion and entry into the host cell. Before entry, the spike protein must be primed by a serine protease TMPRSS2.³⁴ In a living organism, the coronavirus has the highest affinity for the integral plasma membrane protein of ACE2[28,1]. It is wide spread in the body and can be found in the surface of the membrane of the endothelial cell, including the epithelium of the nervous system, nerve endings, and also in the cells of the reproductive system.^{27,1}

Penetration into the cell occurs by binding of the SARS-CoV-2 protein S to the zinc ACE2 peptidase. After S binding, the protein is cleaved in two regions (S protein priming) by the transmembrane serine protease TMPRSS2, which, in turn, promotes the fusion of the viral membrane with the host cell and the direct penetration of the virus into the cytoplasm by endocytosis where replication and amplification of the virus occurs.^{28,1,30,9}

ACE2, part of the renin-angiotensin system, is responsible for cleaving angiotensin (Ang) II into Ang (1-7).^{31,32,9} The involvement of ACE2 likely contributes to the development of cardiovascular complications. The ACE2 is highly expressed in pulmonary tissues, but also in adult human hearts and endothelial cells, indicating an intrinsic susceptibility of these organs to a direct invasion of SARS-CoV-2. Furthermore, SARS-CoV-2 probably produces a downregulation in the ACE2 activity, reducing the conversion of angiotensin II (Ang II) to Ang-(1-7) which in turn leads to increased blood level of angiotensin II, mediating pulmonary vasoconstriction. Ang-II binding to Ang receptors causes vasoconstriction, inflammation, vascular remodeling and fibrosis.^{35,29} Inhibition of ACE2 can be one of the factors of lung damage, as well as the cause of systemic inflammation with the release of cytokines, which ultimately contributes to the development of acute respiratory distress syndrome and multiple organ dysfunction[4]. Liu et al. (2020)²⁹ showed that elevated angiotensin II (ATII) level in the serum were significantly associated with high viral load and more severe lung injury in COVID-19. Excessive angiotensin II potentially activates the pro-thrombotic p38 Mitogen-Activated Protein Kinase (MAPK) pathway, which may lead to thromboembolic events.⁵³ Angiotensin II may also induce Nox2-related reactive oxygen species (ROS) production, resulting in myocardial injury.⁵⁴ Downregulation of ACE2 may cause des-Arg⁹-bradykinin (DABK) accumulation and excessive G-protein-coupled receptor B₁ (BK₁) activation, potentially contributing to HF.⁵⁵ Beyond the local inflammatory effects caused by the virus's entry, a systemic inflammatory response has been proposed to play an essential role in cardiovascular complications.⁵

Due to the immune response, high levels of chemokines are synthesized to attract inflammatory effector cells.⁵² An exacerbated inflammatory response with cytokine storm mediated through pathologic T cells and monocytes leading to myocarditis, is another possible mechanism postulated to explain cardiac injury due to COVID-19.^{64,65} But the exact mechanism of cardiovascular complications in long COVID is not fully understood.

ACE2 is also expressed in adipose tissue and there has been a pathophysiological link between COVID-19 and obesity as pointed out by recent publications[56]. Obesity modulates inflammatory response through secretion of pro- and anti-inflammatory adipokines, modulation of interleukin 6; therefore, COVID-19 infection and its interaction with adipocytes may contribute to deleterious outcomes.⁵⁶ Inflammation involving the epicardial adipose tissue may be affected by myocarditis because of the contiguity of the myocardium and epicardial adipose tissue. Epicardial fat has been linked with atrial fibrillation and coronary artery disease.⁵ Hence, the COVID-19 interaction with epicardial fat may provide a plausible link to acute or long-term atrial fibrillation and coronary artery disease.²

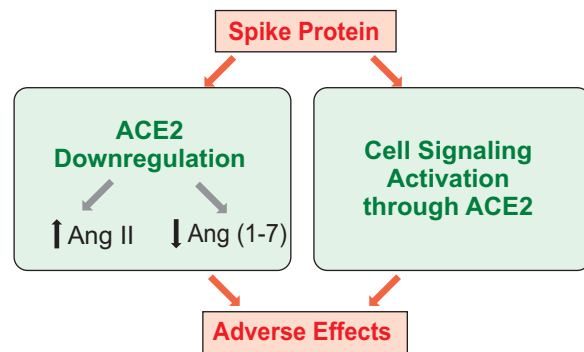


Figure 1. The spike protein downregulates ACE2 that in turn increases Ang II and decreases Ang (1–7), resulting in adverse effects. The spike protein also directly activates cell signaling through the ACE2 receptor, which may also promote adverse events.

Long term impact on cardiovascular system

The sufferings of a covid-19 patient may not get over after the acute infection is resolved but may extend far beyond the acute illness. Post recovery manifestations of patients who have recovered from coronavirus disease 2019 (COVID-19) have become another challenge for the clinicians. Numerous reports have shown that COVID-19 has a variety of long-term effects on almost all systems including respiratory, cardiovascular, gastrointestinal, neurological, psychiatric, and dermatological systems[60]. It is of concern that after 60 days from the onset of infection, as many as 87.4% of 143 patients in an Italian study were affected by Long COVID symptoms and only 12.6% of patients were completely free of any Covid-19 related symptoms.^{42,43} The symptoms and the clinical manifestations of these patients are clinically heterogenous and suggesting involvement of multi-organ/system including the cardiovascular system, the main persistent symptoms being fatigue & dyspnea.^{19,59} It may last for several months

but the duration is still a matter of observation. Cardiovascular involvement commonly manifest with symptoms such as palpitation and chest pain, and less commonly with events such as late arterial and venous thromboembolism, heart failure episodes, strokes or transient ischemic attack, myopericarditis.¹⁹ Long COVID is a still not fully understood entity comprising a constellation of heterogeneous symptoms of uncertain etiology and uncertain direct causality of SARS-CoV-2 infection.

Different terminologies have been used in different articles to represent these groups of patients such as “long Covid”, “Chronic Covid syndrome.” “Long-Haul COVID.” “Post-Acute sequelae of SARS-CoV-2 infection” and “post-acute COVID-19 syndrome (PACS)”.⁸ Post-acute covid-19 is defined as presence of symptoms extending beyond 3 weeks from the initial onset of symptoms and long covid (or chronic covid-19) as extending beyond 12 weeks.^{18,3,19} In a German study of 100 patients who recently recovered from COVID-19, cardiac magnetic resonance imaging (performed a median of 71 days after COVID-19 diagnosis) revealed cardiac involvement in 71% and ongoing myocardial inflammation in 60%.⁵¹ Following cardiovascular symptoms are commonly reported so far;

Palpitations

Commonest cardiac symptom complained by patients of Long COVID; it may correspond to simple sinus tachycardias or supraventricular or ventricular arrhythmias.¹⁹ Although it has no diagnostic specificity, but since it is a frequent cause of requests for medical assistance it must be carefully considered.^{21,19} It is rarely associated with *de novo* electrocardiographic changes. In fact, these changes should be considered *de novo* only when a baseline pre-COVID electrocardiogram (ECG) is available.^{22,19}

Chest pain

Chest pain is another symptom commonly complained of by patients with Long COVID. These pains often do not correspond to instrumental findings useful for a correct interpretation.²³ Chest pain was reported in up to 20% of COVID-19 survivors at 60 day follow-up^{61,62} whereas ongoing palpitation and chest pain were reported in 9 and 5%, respectively, at 6 months follow-up in the post-acute COVID-19 Chinese study.⁶³

Postural Orthostatic tachycardia syndrome (POTS)

A number of case reports have been published on patients who developed POTS after SARS-CoV-2 infection. The diagnosis is made in presence of an increase of >30 b.p.m.

in adults (>40 b.p.m. in patients aged 12–19 years) within 10 min of assuming the upright position in the absence of orthostatic hypotension with associated symptoms of orthostatic intolerance. The association between preceding viral illness and POTS has been previously established. With ACE2 found on neurons, alteration to the autonomic nervous system has been implicated in COVID-19.²²

De novo arrhythmia

Supraventricular and ventricular arrhythmias together with conduction disturbances have been reported among the possible manifestations of long COVID although the exact timing of its onset is difficult to establish.²²

The venous thrombotic manifestations

The thromboembolic events recorded in Long COVID within the first year after recovering from acute COVID-19 include deep vein thrombosis (2.4%) and pulmonary thromboembolism (1.7%).³⁶

Heart failure

Heart failure occurring *De novo* in patients recovered from COVID-19 is rare. Most cases have been studied on patients with pre-existing HF possibly worsening after COVID-19 are reported along with the few cases of *de novo* HF. This limits the ability to identify those cases in which HF is indeed a clinical manifestation of Long COVID. Maestre-Muñiz *et al.*³⁶ report HF onset in 11 of the patients (2.0%) who recovered from COVID-19.

Arterial thrombosis

Arterial thrombosis in subjects without known vascular pathology is found on occasion. In addition to the coronary arteries, with manifestations of acute coronary syndromes in subjects at low risk and without significant coronary artery disease on angiography,³⁷ unexplained thrombotic/thromboembolic events continue to be described at the peripheral/ cerebral/ splanchnic level.³⁸

Myocarditis, pericarditis, myopericarditis

Myocarditis is a debated issue in both COVID-19 and Long COVID mainly due to diagnostic incompleteness and therefore lack of certainty, in particular pathological evidence. In several studies, the diagnosis of myocarditis is based either on the levels of isolated hypertroponinaemia or on the combination of hypertroponinaemia and signs of myocardial oedema on CMR.³⁹ It would be correct to describe persistent hypertroponinaemia and/or oedema, without forcing its interpretation into myocarditis.¹⁹

Cardiometabolic conditions

Diabetes, both type 1 and type 2, is associated with severe COVID-19 and Long COVID. Interventions to target

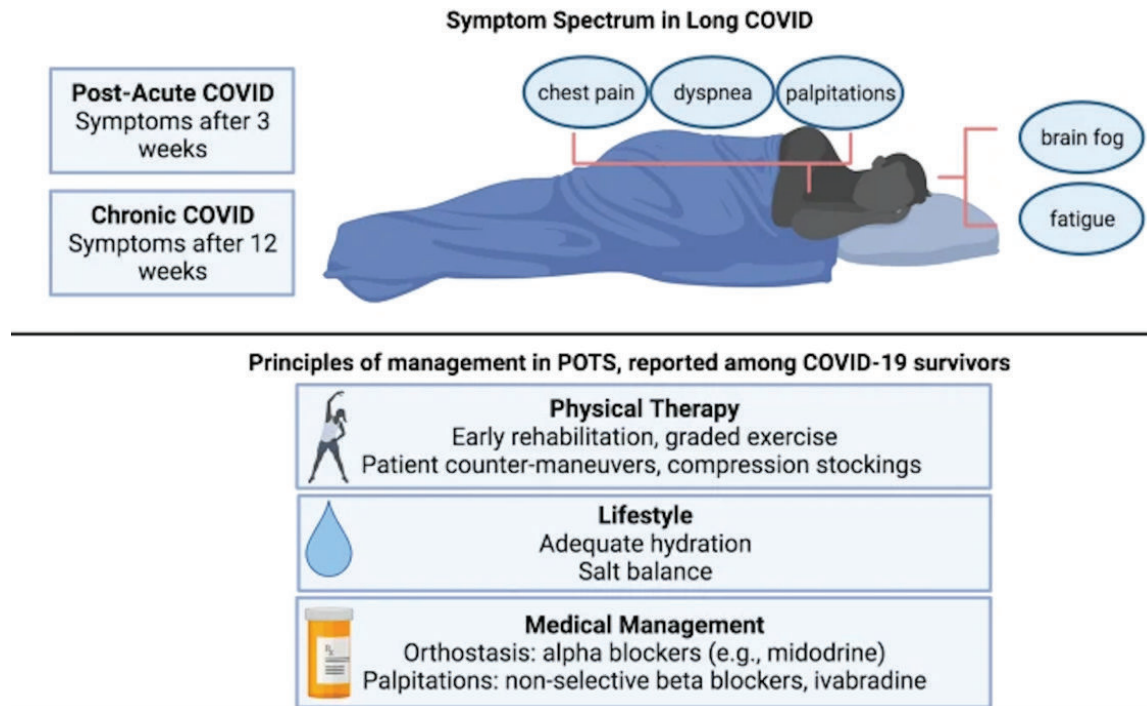


Fig.-2: Review of the definitions and symptomatic manifestations, and current principles of management for potential COVID/postural orthostatic tachycardia syndrome overlap

multiple risk factors, combined with the use of novel glucose-lowering agents that improve metabolic function and the key processes that are impaired in COVID-19, should be the preferred therapeutic options for the management of people with long COVID.¹⁹

The use of imaging modalities may boost our understanding of the cardiovascular involvement in Long COVID. Imaging studies have shown cardiovascular changes that occur following a COVID-19 infection.⁴⁴⁻⁴⁷ Myocardial oedema and late gadolinium enhancement (LGE) have been observed in 58% of 26 Chinese patients presenting with Long COVID cardiac symptoms.⁴⁸ Myocarditis-pattern LGE have been observed up to a month post-infection in 27% of 148 patients in the UK who have had myocardial injury; among which, one-third had findings consistent with an active myocarditis.⁴⁹ Furthermore, up to 78% of 100 mild COVID-19 cases in Germany—despite having fewer co-morbidities—had CMR abnormalities of similar extent and severity to that of patients requiring hospitalization.⁵⁰ Thus, while cardiovascular changes have been observed following a COVID-19 infection, its relationship with Long COVID is still unclear. Furthermore, we are unsure if there are other cardiovascular changes that have been yet to be detected.

Conclusion:

COVID-19 impacts on the cardiovascular system is both the short and long term. With the emerging success of the covid-19 vaccines, the survival of patients has dramatically improved and so we now are left with significant number of survivors having persistent symptoms even months after COVID-19 infection. COVID-19 patients with myocardial injury are likely to remain at risk of cardiovascular events in the long term. Since, we are not yet out of the covid-19 pandemic, it is possible that even larger number of patients will experience long-term sequelae and the term “long haulers” has been suggested to refer to these patients. While clinicians endure to battle COVID-19, we also need to develop broad strategies to manage post-COVID-19 symptoms and encourage those affected to seek suitable care. It will therefore, be imperative to open out-patient post-covid-19 clinics in locality where large outbreaks have occurred and, to provide them healthcare facility in a multidisciplinary approach with a thoughtfully integrated research agenda, to avoid health system fragmentation and to allow the comprehensive study of long-term health consequences of COVID-19 on multiple organ systems and overall health and wellbeing. Special attention is to be paid to athletes with resolved infection who are at risk for exercise-induced arrhythmias and should have graded resumption of activity and exercise.

References:

1. Petrikov SS, Ivannikov AA, Vasilchenko MK, Esaulenko AN, Alidzhanova KG. COVID-19 and cardiovascular system: Pathophysiology, pathomorphology, complications, long-term prognosis. *Russian Sklifosovsky Journal "Emergency Medical Care"*. 2021;15;10(1):14-26.
2. Mitrani RD, Dabas N, Goldberger JJ. COVID-19 cardiac injury: Implications for long-term surveillance and outcomes in survivors. *Heart rhythm*. 2020;17(11):1984-90.
3. Del Rio C, Collins LF, Malani P. Long-term health consequences of COVID-19. *Jama*. 2020;324(17):1723-4.
4. Long B, Brady WJ, Koyfman A, Gottlieb M. Cardiovascular complications in COVID-19. *The American journal of emergency medicine*. 2020;38(7):1504-7.
5. Lee CC, Ali K, Connell D, Mordi IR, George J, Lang EM, Lang CC. COVID-19-associated cardiovascular complications. *Diseases*. 2021;9(3):47.
6. Kwenandar F, Japar KV, Damay V, Hariyanto TI, Tanaka M, Lugito NP, Kurniawan A. Coronavirus disease 2019 and cardiovascular system: a narrative review. *IJC Heart & Vasculature*. 2020 Aug 1;29:100557.
7. Arévalos V, Ortega-Paz L, Fernandez-Rodríguez D, Alfonso Jiménez-Díaz V, Rius JB, Campo G, Rodríguez-Santamarta M, De Prado AP, Gómez-Menchero A, Díaz Fernández JF, Scardino C. Long-term effects of coronavirus disease 2019 on the cardiovascular system, CV COVID registry: A structured summary of a study protocol. *PLoS one*. 2021;16(7):e0255263.
8. Dixit NM, Churchill A, Nsair A, Hsu JJ. Post-Acute COVID-19 Syndrome and the cardiovascular system: What is known?. *American heart journal plus: cardiology research and practice*. 2021;5:100025.
9. Seeherman S, Suzuki YJ. Viral infection and cardiovascular disease: Implications for the molecular basis of COVID-19 pathogenesis. *International Journal of Molecular Sciences*. 2021;22(4):1659.
10. Khawaja SA, Mohan P, Jabbour R, Bampouri T, Bowsher G, Hassan AM, Huq F, Baghdasaryan L, Wang B, Sethi A, Sen S. COVID-19 and its impact on the cardiovascular system. *Open heart*. 2021;8(1):e001472.
11. Nalbandian A, Sehgal K, Gupta A, Madhavan MV, McGroder C, Stevens JS, Cook JR, Nordvig AS, Shalev D, Scharat T, Ahluwalia N. Post-acute COVID-19 syndrome. *Nature medicine*. 2021;27(4):601-15.
12. Pandolfi L, Fossali T, Frangipane V, Bozzini S, Morosini M, D'Amato M, Lettieri S, Urtis M, Di Toro A, Saracino L, Percivalle E. Broncho-alveolar inflammation in COVID-19 patients: a correlation with clinical outcome. *BMC pulmonary medicine*. 2020;20(1):1-0.
13. <https://www.acc.org/latest-in-cardiology/articles/2021/04/21/13/08/intermediate-and-long-term-impact-of-covid-19-on-cardiovascular-disease>
14. Satterfield BA, Bhatt DL, Gersh BJ. Cardiac involvement in the long-term implications of COVID-19. *Nature Reviews Cardiology*. 2021 Oct 22:1-0.
15. <https://www.worldometers.info/coronavirus/>
16. Guzik TJ, Mohiddin SA, Dimarco A, Patel V, Savvatis K, Marelli-Berg FM, Madhur MS, Tomaszewski M, Maffia P, D'acquistio F, Nicklin SA. COVID-19 and the cardiovascular system: implications for risk assessment, diagnosis, and treatment options. *Cardiovascular research*. 2020;116(10):1666-87.
17. <https://www.who.int/director-general/speeches/detail/who-director-general-s-opening-remarks-at-the-media-briefing-on-covid-19-11-march-2020>
18. Greenhalgh T, Knight M, Buxton M, Husain L. Management of post-acute covid-19 in primary care. *bmj*. 2020 Aug 11;370.
19. Di Toro A, Bozzani A, Tavazzi G, Urtis M, Giuliani L, Pizzoccheri R, Aliberti F, Fergnani V, Arbustini E. Long COVID: long-term effects?. *European Heart Journal Supplements*. 2021 Oct;23(Supplement_E):E1-5.
20. Richardson S, Hirsch JS, Narasimhan M, Crawford JM, McGinn T, Davidson KW, Barnaby DP, Becker LB, Chelico JD, Cohen SL, Cookingham J. Presenting characteristics, comorbidities, and outcomes among 5700 patients hospitalized with COVID-19 in the New York City area. *Jama*. 2020;323(20):2052-9.
21. Lee CC, Ali K, Connell D, Mordi IR, George J, Lang EM, Lang CC. COVID-19-associated cardiovascular complications. *Diseases*. 2021;9(3):47.
22. Dixit NM, Churchill A, Nsair A, Hsu JJ. Post-Acute COVID-19 Syndrome and the cardiovascular system: What is known?. *American heart journal plus: cardiology research and practice*. 2021;5:100025.
23. Richter D, Guasti L, Koehler F, Squizzato A, Nistri S, Christodorescu R, Dievart F, Gaudio G, Asteggiano R, Ferrini M. Late phase of COVID 19 pandemic in General Cardiology. A position paper of the ESC Council for Cardiology Practice. *ESC heart failure*. 2021;8(5):3483-94.
24. Huang C, Wang Y, Li X, Ren L, Zhao J, Hu Y, Zhang L, Fan G, Xu J, Gu X, Cheng Z. Clinical features of patients infected with 2019 novel coronavirus in Wuhan, China. *The lancet*. 2020;395(10223):497-506.
25. Wu C, Chen X, Cai Y, Zhou X, Xu S, Huang H, Zhang L, Zhou X, Du C, Zhang Y, Song J. Risk factors associated with acute respiratory distress syndrome and death in patients with coronavirus disease 2019 pneumonia in Wuhan, China. *JAMA internal medicine*. 2020;180(7):934-43.
26. To KK, Hung IF, Ip JD, Chu AW, Chan WM, Tam AR, Fong CH, Yuan S, Tsoi HW, Ng AC, Lee LL. COVID-19 re-infection by a phylogenetically distinct SARS-coronavirus-2 strain confirmed by whole genome sequencing. *Clinical infectious diseases: an official publication of the Infectious Diseases Society of America*. 2020 Aug 25.
27. Srivastava SP, Goodwin JE, Kanasaki K, Koya D. Inhibition of angiotensin-converting enzyme ameliorates renal fibrosis by mitigating dpp-4 level and restoring antifibrotic micromas. *Genes*. 2020;11(2):211.
28. Corman VM, Lienau J, Witznath M. Coronaviruses as the cause of respiratory infections. *Der Internist*. 2019;60(11):1136-45.

29. Liu Y, Yang Y, Zhang C, Huang F, Wang F, Yuan J, Wang Z, Li J, Li J, Feng C, Zhang Z. Clinical and biochemical indexes from 2019-nCoV infected patients linked to viral loads and lung injury. *Science China Life Sciences*. 2020;63(3):364-74.
30. Yan R, Zhang Y, Li Y, Xia L, Guo Y, Zhou Q. Structural basis for the recognition of SARS-CoV-2 by full-length human ACE2. *Science*. 2020;367(6485):1444-8.
31. Gheblawi M, Wang K, Viveiros A, Nguyen Q, Zhong JC, Turner AJ, Raizada MK, Grant MB, Oudit GY. Response by Gheblawi et al to Letter Regarding Article, "Angiotensin-converting enzyme 2: SARS-CoV-2 receptor and regulator of the renin-angiotensin system: celebrating the 20th anniversary of the discovery of ACE2". *Circulation Research*. 2020;127(2):e46-7.
32. Warner FJ, Smith AI, Hooper NM, Turner AJ. Angiotensin-converting enzyme-2: a molecular and cellular perspective. *Cellular and molecular life sciences: CMLS*. 2004;61(21):2704-13.
33. Tai W, He L, Zhang X, Pu J, Voronin D, Jiang S, Zhou Y, Du L. Characterization of the receptor-binding domain (RBD) of 2019 novel coronavirus: implication for development of RBD protein as a viral attachment inhibitor and vaccine. *Cellular & molecular immunology*. 2020;17(6):613-20.
34. Hoffmann M, Kleine-Weber H, Schroeder S, Krüger N, Herrler T, Erichsen S, Schiergens TS, Herrler G, Wu NH, Nitsche A, Müller MA. SARS-CoV-2 cell entry depends on ACE2 and TMPRSS2 and is blocked by a clinically proven protease inhibitor. *cell*. 2020;181(2):271-80.
35. Mendoza-Torres E, Oyarzún A, Mondaca-Ruff D, Azocar A, Castro PF, Jalil JE, Chiong M, Lavandero S, Ocaranza MP. ACE2 and vasoactive peptides: novel players in cardiovascular/renal remodeling and hypertension. *Therapeutic advances in cardiovascular disease*. 2015;9(4):217-37.
36. Maestre-Muñoz MM, Arias Á, Mata-Vázquez E, Martín-Toledano M, López-Larramona G, Ruiz-Chicote AM, Nieto-Sandoval B, Lucendo AJ. Long-term outcomes of patients with coronavirus disease 2019 at one year after hospital discharge. *Journal of clinical medicine*. 2021;10(13):2945.
37. Wong SW, Fan BE, Huang W, Chia YW. ST-segment elevation myocardial infarction in post-COVID-19 patients: A case series. *Ann Acad Med Singap*. 2021;50(5):425-30.
38. Fan BE, Umaphathi T, Chua K, Chia YW, Wong SW, Tan GW, Chandrasekar S, Lum YH, Vasoo S, Dalan R. Delayed catastrophic thrombotic events in young and asymptomatic post COVID-19 patients. *Journal of thrombosis and thrombolysis*. 2021;51(4):971-7.
39. Ghugre NR, Orbach A, Biswas L, Connelly KA, Chan A, Strauss BH, Wright GA, Roifman I. Suspected subclinical myocarditis detected by cardiac magnetic resonance imaging late post COVID-19 recovery. *Journal of Cardiology Cases*. 2021;24(5):203-5.
40. Khunti K, Davies MJ, Kosiborod MN, Nauck MA. Long COVID—metabolic risk factors and novel therapeutic management. *Nature Reviews Endocrinology*. 2021;17(7):379-80.
41. Chu KY, Nackeeran S, Horodyski L, Masterson TA, Ramasamy R. COVID-19 infection is associated with new onset Erectile Dysfunction: Insights from a National Registry. *Sexual Medicine*. 2022;10(1):100478.
42. Yelin D, Margalit I, Yahav D, Runold M, Bruchfeld J. Long COVID-19—it's not over until?. *Clinical Microbiology and Infection*. 2021;27(4):506-8.
43. Petersen MS, Kristiansen MF, Hanusson KD, Danielsen ME, á Steig B, Gaini S, Strøm M, Weihe P. Long COVID in the Faroe Islands: a longitudinal study among nonhospitalized patients. *Clinical Infectious Diseases*. 2021;73(11):e4058-63.
44. Sartoretti E, Sartoretti T, Imoberdorf R, Dracklé J, Sartoretti-Schefer S. Long-segment arterial cerebral vessel thrombosis after mild COVID-19. *BMJ Case Reports CP*. 2020 Sep 1;13(9):e236571.
45. Sollini M, Ciccarelli M, Cecconi M, Aghemo A, Morelli P, Gelardi F, Chiti A. Vasculitis changes in COVID-19 survivors with persistent symptoms: an [18F] FDG-PET/CT study. *European journal of nuclear medicine and molecular imaging*. 2021;48(5):1460-6.
46. Jagia P, Ojha V, Naik N, Sharma S. Myocardial fibrosis detected by cardiovascular magnetic resonance in absence of myocardial oedema in a patient recovered from COVID-19. *BMJ Case Reports CP*. 2020;13(12):e240193.
47. Agarwal S, Al Hashimi H, Agarwal SK, Albastaki U. Possible association between myocardial infarction with nonobstructed coronary arteries and SARS-CoV-2 infection. *CMAJ*. 2020;192(48):E1633-6.
48. Huang L, Zhao P, Tang D, Zhu T, Han R, Zhan C, Liu W, Zeng H, Tao Q, Xia L. Cardiac involvement in patients recovered from COVID-2019 identified using magnetic resonance imaging. *Cardiovascular Imaging*. 2020;13(11):2330-9.
49. Kotecha T, Knight DS, Razvi Y, Kumar K, Vimalasvaran K, Thornton G, Patel R, Chacko L, Brown JT, Coyle C, Leith D. Patterns of myocardial injury in recovered troponin-positive COVID-19 patients assessed by cardiovascular magnetic resonance. *European heart journal*. 2021;42(19):1866-78.
50. Outcomes of Cardiovascular Magnetic Resonance Imaging in Patients Recently Recovered from Coronavirus Disease 2019 (COVID-19).
51. Puntmann VO, Carerj ML, Wieters I, Fahim M, Arendt C, Hoffmann J, Shchendrygina A, Escher F, Vasa-Nicotera M, Zeiher AM, Vahreschild M. Outcomes of cardiovascular magnetic resonance imaging in patients recently recovered from coronavirus disease 2019 (COVID-19). *JAMA cardiology*. 2020 Nov 1;5(11):1265-73.
52. Holter JC, Pischke SE, de Boer E, Lind A, Jenum S, Holten AR, Tonby K, Barratt-Due A, Sokolova M, Schjalm C, Chaban V. Systemic complement activation is associated with respiratory failure in COVID-19 hospitalized patients. *Proceedings of the National Academy of Sciences*. 2020;117(40):25018-25.
53. Grimes JM, Grimes KV. p38 MAPK inhibition: A promising therapeutic approach for COVID-19. *Journal of Molecular and Cellular Cardiology*. 2020;144:63-5.

54. Violi F, Pastori D, Pignatelli P, Cangemi R. SARS-CoV-2 and myocardial injury: a role for Nox2?. *Internal and Emergency Medicine*. 2020;15(5):755-8.
55. Nicolau LA, Magalhães PJ, Vale ML. What would Sérgio Ferreira say to your physician in this war against COVID-19: How about kallikrein/kinin system?. *Medical hypotheses*. 2020 Oct 1;143:109886.
56. Malavazos AE, Romanelli MM, Bandera F, Iacobellis G. Targeting the adipose tissue in COVID 19. *Obesity (Silver Spring, Md.)*. 2020 Jul 1.
57. Packer M. Epicardial adipose tissue may mediate deleterious effects of obesity and inflammation on the myocardium. *Journal of the American College of Cardiology*. 2018;71(20):2360-72.
58. Goeller M, Achenbach S, Marwan M, Doris MK, Cadet S, Commandeur F, Chen X, Slomka PJ, Gransar H, Cao JJ, Wong ND. Epicardial adipose tissue density and volume are related to subclinical atherosclerosis, inflammation and major adverse cardiac events in asymptomatic subjects. *Journal of cardiovascular computed tomography*. 2018;12(1):67-73.
59. Fernández-de-Las-Peñas C, Palacios-Ceña D, Gómez-Mayordomo V, Palacios-Ceña M, Rodríguez-Jiménez J, de-la-Llave-Rincón AI, Velasco-Arribas M, Fuensalida-Novo S, Ambite-Quesada S, Guijarro C, Cuadrado ML. Fatigue and dyspnoea as main persistent post-COVID-19 symptoms in previously hospitalized patients: related functional limitations and disability. *Respiration*. 2022;101(2):132-41.
60. Kayaaslan B, Eser F, Kalem AK, Kaya G, Kaplan B, Kacar D, Hasanoglu I, Coskun B, Guner R. Post COVID syndrome: A single center questionnaire study on 1007 participants recovered from COVID 19. *Journal of Medical Virology*. 2021;93(12):6566-74.
61. Carfi A, Bernabei R, Landi F. Persistent symptoms in patients after acute COVID-19. *Jama*. 2020;324(6):603-5.
62. Carvalho-Schneider C, Laurent E, Lemaigen A, Beaufils E, Bourbao-Tournois C, Laribi S, Flament T, Ferreira-Maldent N, Bruyère F, Stefic K, Gaudy-Graffin C. Follow-up of adults with noncritical COVID-19 two months after symptom onset. *Clinical Microbiology and Infection*. 2021;27(2):258-63.
63. Huang C, Huang L, Wang Y, Li X, Ren L, Gu X, Kang L, Guo L, Liu M, Zhou X, Luo J. 6-month consequences of COVID-19 in patients discharged from hospital: a cohort study. *The Lancet*. 2021;397(10270):220-32.
64. Zhou Y, Fu B, Zheng X, Wang D, Zhao C, Qi Y, Sun R, Tian Z, Xu X, Wei H. Pathogenic T-cells and inflammatory monocytes incite inflammatory storms in severe COVID-19 patients. *National Science Review*. 2020;7(6):998-1002.
65. Merad M, Martin JC. Pathological inflammation in patients with COVID-19: a key role for monocytes and macrophages. *Nature reviews immunology*. 2020;20(6):355-62.