

## CASE REPORT

# A Case of Infective Endocarditis Caused by Rapidly Growing Non-tuberculous Mycobacterium after Cardiac Catheterization

S. M. NURUL HUDA, MOHAMMAD FAISAL IBN KABIR, MD. FAKHRUL ISLAM KHALED,  
AFM AZIM ANWAR, MD. RASUL AMIN

Dept of Cardiology, Bangabandhu Sheikh Mujib Medical University (BSMMU), Shahbag, Dhaka, Bangladesh,  
Address of Correspondence: Dr. S. M. Nurul Huda, Resident, Dept of Cardiology, BSMMU. Email: drsmnhuda@gmail.com

### Abstract:

*Endocarditis caused by non-tuberculous mycobacterium is rare and often missed without appropriate blood cultures. It does not respond to standard antitubercular treatment and is also resistant to many other antibiotics. The course of the disease may be indolent and often results in a fatal outcome.*

*Here we report a case of Nontuberculous mycobacterial endocarditis of the native aortic valve in an immunocompetent patient following coronary angiography. The case highlights an unfortunate intervention – related nosocomial infection and the difficulties in chemotherapeutic options for this organism, particularly in the presence of marrow suppression and acute interstitial nephritis.*

**Key Words:** *Infective Endocarditis, Rapidly Growing Non-tuberculous Mycobacterium, Cardiac Catheterization, reuse of single-use medical devices.*

*University Heart Journal 2023; 19(1): 31-34*

*DOI: <https://doi.org/10.3329/uhj.v19i1.69828>*

### Introduction:

Infective endocarditis (IE) is a rare but serious disease with a high mortality rate.<sup>1</sup> Nontuberculous mycobacterial disease does not occur frequently in immunocompetent patient. The NTM is found in soil, in environmental water, drinking water, and in aerosols. The reservoir in animals has been considered less important, although species have been isolated in animals such as birds, fish, and some amphibians. Although contact with mycobacteria is quite frequent, developing a disease is difficult because of the low virulence of these pathogens.<sup>2</sup> Based on their growth rates, NTM have been classified into slowly growing or rapidly growing mycobacteria. Rapidly growing mycobacteria grow within seven days on solid media [3]. Environmental mycobacteria are common post procedure pathogens, especially when disposable equipment is recycled. Native valve endocarditis with NTM is rare and often missed. Accurate identification and sensitivity, combination therapy, and prolonged duration of antibiotics are, therefore, important for a successful outcome.

### Case Report:

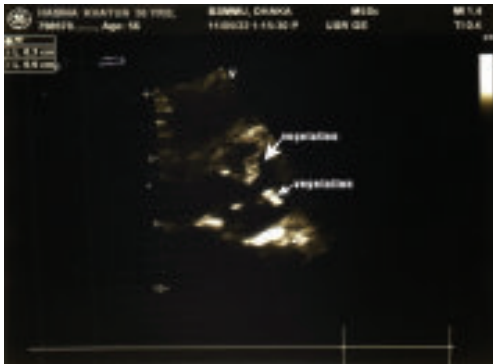
A 56-years-old woman with known diabetic, hypothyroidism, cholelithiasis was admitted in our hospital with the complaints of intermittent fever for several month.

She had a history of NSTEMI about three months back for which coronary angiography was done and revealed triple vessel coronary artery disease. Then she underwent PCI with stenting to LAD(x1) & RCA(x2). The pre & post procedure events were uneventful. Ten days after procedure, patient was developed intermittent fever varying from 102-106 °F which was associated with chills & rigor. Thorough clinical evaluation and all possible investigation to find out the cause of fever including complete blood count with PBF, urine RME, blood & urine culture, SARS-Cov-2, Dengue NS1, Malarial parasite, Widal test, Weil-Felix reaction, Brucella agglutination, test for Kala-azar, color doppler echocardiography, CT scan of chest, USG of abdomen were done. But no definite cause of fever was identified. She got empirical treatment with injection Meropenem & injection Vancomycin for 07 days, anti-malarial drugs Artemeter+Lumefantrine and Sulfadoxine+Pyrimethamine. Then she was discharged with advice of medication along with cap Doxycycline and cap Cefixime for 2 weeks. But Patient's fever was continued in intermittent pattern.

About two months after the index PCI patient was developed severe cough with respiratory distress and admitted in hospital and diagnosed as cardiogenic shock, acute heart failure, atrial

fibrillation with bronchiectasis in lung. Color Doppler echocardiography showed good LV systolic function with LVEF:60%, Mild aortic stenosis, moderate aortic regurgitation. Fever was varying from 100-101°F. Blood culture showed Pseudomonas (sensitive to Ceftazidime, meropenem, etc.), Urine culture showed Enterococcus species (sensitive to Vancomycin, Linezolid etc.), sputum culture showed profuse Enterococcus sp. & scanty klebsiella pneumonia (sensitive to vancomycin, gentamicin). IV antibiotic, inj. vancomycin and inj. Ceftazidime was started after getting c/s report and later on Inj. Gentamicin was added. About 03 weeks of in hospital treatment, patient was shifted to our hospital for better management.

After admission we thoroughly examined the patient clinically. Patient had anemia, mild pedal oedema, temp 102°F, pulse 90b/min, BP 130/60 mmHg, respiratory rate:

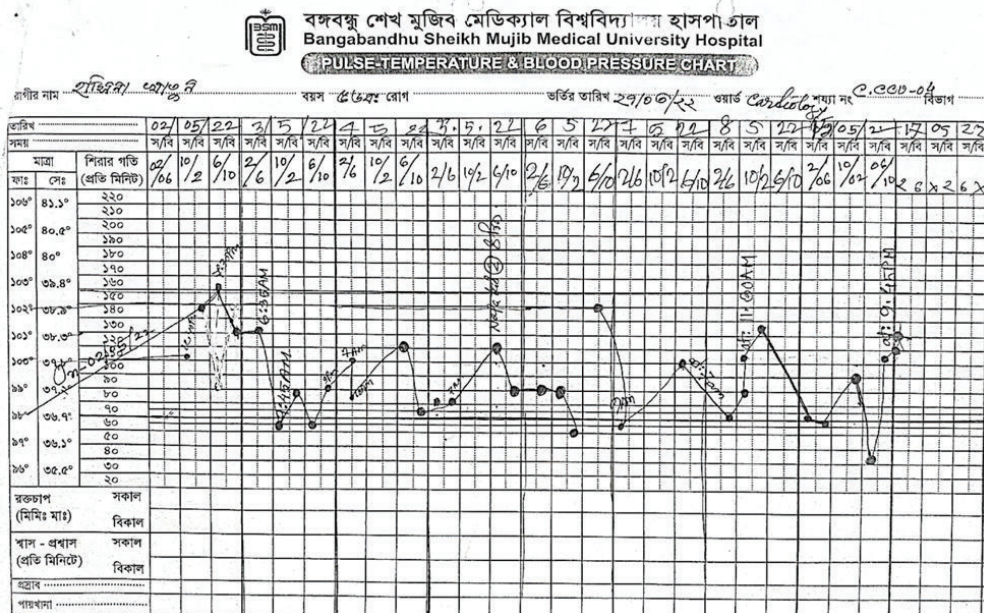


**Fig.-1:** Transthoracic echocardiography PLAX view showing vegetation attached with the NCC & RCC cusp of aortic valve

20bpm, SpO2- 94% with 4LO2/min, lung: bi basal crepitation, heart: early diastolic murmur in aortic area, no palpable lymphadenopathy, clubbing, bony tenderness or organomegaly. We perform all baseline investigation, send multiple sets of blood culture for aerobic, anaerobic & HACHEK group from different site according to infective endocarditis protocol and perform a transthoracic color doppler echocardiography. Echocardiography finding showed multiple vegetation attaching in cusp in aortic valve (about 0.7 x 0.5 cm in NCC & 0.3 x 0.9 cm in RCC), moderate AR, mild MR, good LV systolic function (EF-62%).

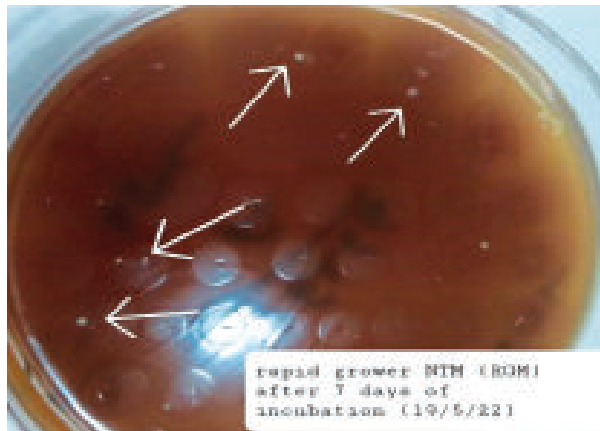
Meanwhile, blood culture report came and showed growth of rapid grower Nontuberculous Mycobacteria (NTM) which was sensitive to Linezolid, Clarithromycin, Amikacin and Cefoxitin. Injection linezolid (600mg 12 hourly), injection clarithromycin (500 mg 12 hourly) and Injection Amikacin (500mg 12 hourly) were started. During this period patient was developed Acute Interstitial Nephritis, Pancytopenia, seizure episodes due to Epileptic encephalopathy and treated accordingly.

Patient's heart failure was not improving clinically, and fever was continued in intermittent pattern. So, opinion was taken from cardiac surgeon regarding surgical management option of infective endocarditis. But it was advised to avoid surgery due to multiple comorbidity and high risk of mortality. Meanwhile, patient was evaluated by serial echocardiography showing vegetation had been organized and size was decreasing without developing any local complication. But patient's fever was not improving.



**Fig.-2:** Temperature chart of patient showing intermittent fever

Inj. Linezolid has to be discontinued after three weeks due to a possible cause of marrow suppression. Injection Tigecycline was added empirically in addition to ongoing antibiotic injection Clarithromycin & Amikacin. Meanwhile blood culture was sent several times during the peak of fever. Repeat blood culture report about one and half month later of initial blood culture of NTM still showed rapid grower nontuberculous mycobacterium while the organism is sensitive to same antibiotic panel as previous one.



**Fig.-3:** Repeat blood culture showed rapid grower NTM

But still patient was frequently documented with high rise of temperature. Patient was taken to abroad about 2 months later for further management. One month later patient died there.

#### **Discussion:**

Endocarditis due to mycobacterium is rare, and rapidly growing NTM account for 68% of the isolates.<sup>4</sup> Post procedure mycobacterial infections have been often reported, especially in Indian subcontinent, where glutaraldehyde is used as a sterilizing solution for surgical and other equipment.<sup>5</sup> Cardiac catheterization is now increasingly performed in smaller centers. Infections complicating coronary angiography include sepsis, endocarditis, suppurative pancarditis, stent infection, septic arthritis, epidural abscess, necrotizing fasciitis, and groin wound infection.<sup>6</sup>

Risk factors for bacteremia following catheterization include obesity, duration of the procedure, the number of balloons used, and the number of skin punctures performed [7]. Another important cause is reuse of single-use medical devices such as guide wire, catheter, balloon during cardiac catheterization particularly in the least developed countries. Users often justify the reprocessing of such

devices on the basis of economic and environmental benefits. These perceived benefits are questionable as many of the processes required to ensure that the device is safe and fit for its intended purpose. Single-use medical device reprocessing entails disinfecting, cleaning, sterilizing, packaging, labeling, and storing a used or opened package of a medical device to be placed into service again.<sup>8</sup> To reprocess such a device after it has been used, one must ensure that it is sufficiently clean or sterile and properly functioning, and will not pose a risk to the patient for whom it is used. In developing countries most commonly used agent for sterilization of such devices is glutaraldehyde which is actually partially sporicidal. Besides glutaraldehyde solutions lose their activity after 1 or 2 weeks of storage and must therefore be stored as aqueous acidic solutions and alkalinized to pH 8.5 by bicarbonate before use. Sterilization by ethylene oxide is a better option but not readily available in developing countries due to higher cost.

The most common causative organism of bacteremia following cardiac catheterization is *Staphylococcus aureus*, particularly in the obese. Native valve endocarditis with NTM is rare and often missed without appropriate blood cultures. In cases of post procedure endocarditis, the aortic valve is predominantly affected (as was seen in our case). Early diagnosis and prolonged combination therapy are obligatory to minimize mortality, as rapidly growing NTM is inherently resistant to multiple antibiotics.<sup>9</sup> Typically, antibiotics with maximum in vitro activity against NTM isolates include amikacin, clarithromycin, tigecycline, and cefoxitin. To a lesser extent, linezolid and imipenem are also effective against nearly 50% of clinical isolates.

Combination therapy is mandatory and should be administered for at least 3-6 months. Tigecycline and linezolid are newer antibiotics with efficacy against NTM and the recommended treatment length with these drugs is 6-12 months. Among the carbapenems, only imipenem is useful in some cases.<sup>10</sup> In our patient clarithromycin, Amikacin, Linezolid & Cefoxitin were the sensitive drugs. Patient's clinical improvement was not satisfactory though chemotherapeutic agents were chosen according to culture sensitivity report. In vitro drug susceptibility patterns do not always correlate with clinical responses and measurements of minimum inhibitory concentrations of antibiotics do not always predict their therapeutic effects.<sup>11</sup> In our patient we have to hold Linezolid due to bone marrow suppression. Amikacin was also held temporarily and later resumed in low dose due to development of acute interstitial nephritis. Cefoxitin was not available in local

market. So, we have to continue Clarithromycin and Amikacin for this patient. Tigecillin was added to standard antituberculous therapy with the hope of some benefit in such a desperate situation.

### Conclusion:

Endocarditis due to non-tuberculous mycobacteria is a rare but dangerous pathology. It often leads to fatal outcome despite combination antimicrobial therapy. It remains uncertain if early diagnosis and institution of appropriate therapy or valve surgery would have altered the fatal outcome in our case. So utmost effort should be taken for early diagnosis and treatment initiation in suspicious case. As well as nosocomial infection control needs to be strengthened particularly at smaller centers where complex interventions are increasingly being conducted. The reuse of single-use devices can affect their safety, performance and effectiveness, exposing patients to unnecessary risk, infection even death. World Health Organization recommends that a device designated as 'single-use' must not be reused. It should only be used on an individual patient during a single procedure and then discarded. The reuse of single-use devices has also legal implications.

### Declaration of patient consent:

The authors certify that they have obtained all appropriate patient consent forms. In the form the patient(s) has/have given his/her/their consent for his/her/their images and other clinical information to be reported in the journal.

### Conflicts of interest:

There are no conflicts of interest.

### Reference:

1. Moreillon P, Que YA. Infective endocarditis. *Lancet* 2004; 363:139–49.
2. Wagner D, Young LS. Nontuberculous mycobacterial infections: A clinical review. *Infection* 2004;32:257-70.
3. Brown-Elliott BA, Wallace RJ Jr. Clinical and taxonomic status of pathogenic nonpigmented or late-pigmenting rapidly growing mycobacteria. *Clin Microbiol Rev* 2002;15:716-46.
4. Matos ED, Santana MA, de Santana MC, Mamede P, de Lira Bez-erra B, Pano ED, Filho CSS, Lemos ACM. Nontuberculosis mycobacteria at a multiresistant tuberculosis reference center in Bahia: clinical epidemiological aspects. *Braz J Infec Dis* 2004;8(4):296–304 Aug-doi:<https://doi.org.10.1590/s1413-86702004000400005>.
5. Wallace RJ, Jr, Brown BA, Griffith DE. Nosocomial outbreaks/pseudo-outbreaks caused by nontuberculous mycobacteria. *Annu Rev Microbiol.* 1998;52:453–90. [PubMed] [Google Scholar]
6. Jayasuriya S, Movahed MR. Infectious endocarditis with systemic septic embolization as a rare complication of cardiac catheterization. *Exp Clin Cardiol.* 2009;14:e17–20. [PMC free article] [PubMed] [Google Scholar]
7. Shaw JP, Eisenberg MJ, Azoulay A, Nguyen N. Reuse of catheters for percutaneous transluminal coronary angioplasty: Effects on procedure time and clinical outcomes. *Catheter Cardiovasc Interv.* 1999;48:54–60. [PubMed] [Google Scholar]
8. "Reuse of Medical Devices Labeled for Single-use." Statement of David Feigal, MD before the Senate Committee on Health, Education, Labor and Pensions. June 27, 2000. <https://www.fda.gov/NewsEvents/Testimony/ucm114926.htm> Accessed March 30, 2017.
9. Griffith DE, Aksmit T, Brown-Elliott BA, Catanzaro A, Daley C, Gordin F, et al. Official ATS/IDSA statement: Diagnosis, treatment, and prevention of nontuberculous mycobacterial diseases. *Am J Respir Crit Care Med.* 2007;175:367–16. [PubMed] [Google Scholar]
10. Gayathri R, Therese KL, Deepa P, Mangai S, Madhavan HN. Antibiotic susceptibility pattern of rapidly growing mycobacteria. *J Postgrad Med.* 2010;56:76–8. [PubMed] [Google Scholar]
11. Nessar R, Cambau E, Reyrat JM, Murray A, Gicquel B. *Mycobacterium abscessus*: a new antibiotic nightmare. *J Antimicrob Chemother.* 2012;67:810–8. [PubMed] [Google Scholar]