

# Successful Surgical Outcome of Coarctation of Aorta in an adult male

MD. MOSTAFIZUR RAHMAN, MA HOSSAIN, MAQ CHOWDHURY, OS KHAN, SR SARKER,  
REZWANUL HOQUE, ASIT BARENADHIKARY

Department of Cardiac Surgery, Bangabandhu Sheikh Mujib Medical University, Dhaka

**Address for Correspondence:** Dr. Md. Mostafizur Rahman, Associate Professor, Department of Cardiac Surgery, Bangabandhu Sheikh Mujib Medical University, Dhaka, E-mail: rattan\_cts@yahoo.com

## Abstract:

*Coarctation of the aorta is a relatively common defect that accounts for 5-8% of all congenital heart defects. Coarctation of the aorta may occur as an isolated defect or in association with various other lesions, most commonly patent ductus arteriosus, bicuspid aortic valve and ventricular septal defect. The diagnosis of coarctation of the aorta may be missed or delayed unless there is a high index of suspicion and the presentation may be congestive heart failure in infant or hypertension in older children and adult. A case of coarctation of the aorta associated with patent ductus arteriosus having features of headache, exertional dyspnea and uncontrolled hypertension is being presented here. PTFE patch aortoplasty and ligation with transfixation of PDA was done. Post-operative period was uneventful and patient was discharged on 7<sup>th</sup> post-operative day.*

**Key words:** Coarctation of the aorta, Patent Ductus Arteriosus.

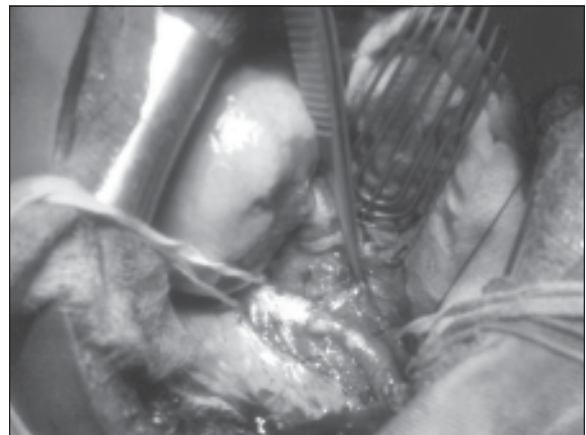
## Introduction:

Coarctation of the aorta may be defined as a constricted aortic segment that comprises localized medial thickening with a ridge of intimal hypoplasia and may include tissue extending from the ductus arteriosus.<sup>1</sup> Coarctation may occur at any site within the aorta, but the most common location is at the insertion of the ductus (or ligamentum arteriosus). Externally the aorta appears to be sharply indented or constricted. Internally there is an obstructing diaphragm or shelf on the posterior wall resulting in luminal narrowing, which is usually more marked than is apparent by external appearance. Dilatation of the descending aorta immediately distal to the coarctation segment (post-stenotic dilatation) is usually present. Varying degrees of hypoplasia of the isthmus of the aorta (the portion of the aorta between the origin of the left subclavian artery and ductus arteriosus) are present in most patients with thoracic coarctation; this hypoplasia may be significant in symptomatic coarctation of the neonate and infant; in children and adults, the isthmus may have only mild narrowing. The transverse aortic arch (the arch between the origin of the right innominate artery and the left subclavian artery) may also be hypoplastic in symptomatic neonates and infants. Collateral vessels that connect arteries from the upper part of the body to the vessels below the level of coarctation are seen; these may be present as early as a few weeks to a few months of life. The most commonly associated clinically significant defects include patent ductus arteriosus, VSD and aortic stenosis. The earlier the infant presents, the more likely a

significant associated defect is present. Bicuspid aortic valve may be seen in nearly two thirds of infants with coarctation of the aorta, whereas only 30% of those who present in childhood have such an anomaly. Some patients with coarctation of the aorta may have cerebral aneurysms, predisposing them to cerebrovascular accidents with severe hypertension later in life. Coarctation of the aorta is the most common (15-36%) cardiac defect associated with Turner syndrome.


## Case report:

A 22 years male presented in the department of cardiac surgery of BSMMU with the complaints of headache, exertional dyspnea and uncontrolled hypertension. He had been well until 5 months back. His hypertension was poorly

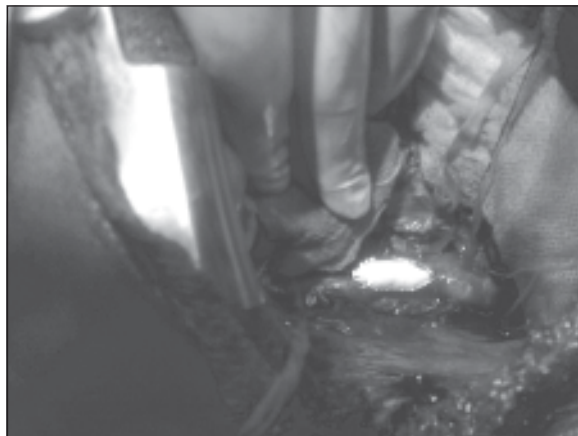


**Fig.-1:** Shows the coarctation of the aorta.

controlled despite a combination of antihypertensive agents (beta-blocker, calcium channel blocker and angiotensin receptor blocker). Physical examination showed blood pressure 140/90 in both arms, heart rate of 74 beats/minute. Femoral pulses were palpable bilaterally but weak and delayed compared to the radial pulses. A systolic murmur was present in the left infraclavicular area and under the left scapula. His echocardiogram showed no abnormality. Ribs notching were observed on the chest radiograph. Aortography showed a significant ring-like stenosis in the thoracic descending aorta. Surgical intervention was done via left posterolateral thoracotomy through fourth intercostal space. Coarctation was associated with patent ductus arteriosus. Ligation with transfixation of PDA was done. The area of constriction was incised longitudinally; the obstructing shelf was excised and a PTFE patch aortoplasty was done. The cross clamp time was 23 minutes and no malperfusion syndrome occurred. Total hospital stay after procedure was seven days. After 3 month follow-up visit, the patient was in good clinical condition.



**Fig.-2:** Shows posterior wall of aorta after excision of shelf.



**Fig.-3:** PTFE patch aortoplasty

### Discussion:

The exact mechanism by which aortic coarctation is produced is not clearly understood. The most commonly invoked hypotheses include hemodynamic and ectopic ductal tissue theories. In the hemodynamic theory, an abnormal preductal flow or abnormal angle between the ductus and aorta that increases right-to-left ductal flow and decreases isthmus flow potentiates development of coarctation.<sup>2</sup> Postnatal spontaneous closure of the ductus arteriosus completes the development of aortic obstruction. In the ectopic ductal tissue theory, abnormal extension of ductal tissue into the aorta (ectopic ductal tissue) has been postulated to create the coarctation shelf and with ductal closure, development of aortic obstruction. This theory, however, does not explain the variable degrees of isthmus and aortic arch hypoplasia associated with coarctation of the aorta<sup>3</sup>.

The presence of associated defects and aortic arch anomalies, the extent of patency of the ductus arteriosus, the rapidity of the process of closure of the ductus arteriosus and the level of pulmonary vascular resistance determine the timing of clinical presentation and the severity of symptoms. Generally, patients with coarctation of the aorta present with congestive heart failure in early life or with hypertension in older children and adult. Studies continue to document that coarctation of the aorta is often missed in the first year of life and the median age of referral to a pediatric cardiologist in one study was 5 years.<sup>4,5</sup> Regarding age of presentation it was reported to the Pediatric Cardiac Care Consortium from 1985-1993, among 2192 patients - 1337 were infants, 824 were children and 31 were adults.<sup>6</sup>

Patients may present in the first few weeks of life with poor feeding, tachypnea and lethargy and progress to overt CHF and shock.<sup>7</sup> Patients often present after the neonatal period with hypertension or a murmur. These patients often have not developed overt CHF because of the presence of arterial collateral vessels. Diagnosis is often made after hypertension is noted as an incidental finding during evaluation of other problems. Other presenting symptoms may include headaches, chest pain, fatigue or even life-threatening intracranial hemorrhage. In this case, patient was relatively asymptomatic until he presented with headache, exertional dyspnea and uncontrolled hypertension.

Prognosis and survival depend on the disease severity and patient's age at the time of correction. Death in these patients is usually due to heart failure, coronary artery disease, aortic rupture/dissection, concomitant aortic valve

disease, infective endarteritis/endocarditis, or cerebral hemorrhage.<sup>3</sup> Aortography (conventional, CT or MRI), echocardiogram, chest X-ray, CT scan of brain are needed to diagnose the disease and to find associated defects. Treatment consists of aggressive management of hypertension, endocarditis prophylaxis and endovascular (stenting) or surgical treatment for coarctation. Surgical treatment includes PTFE patch aortoplasty, subclavian flap aortoplasty, excision of coarcted segment and end to end anastomosis or anastomosis with interposition graft. In this case, patient was treated with PTFE patch aortoplasty and ligation with transfixation of PDA.

### References:

1. Rao PS. Should balloon angioplasty be used instead of surgery for native aortic coarctation?. *Br Heart J*. Dec 1995; 74(6): 578-79.
2. Rudolph AM, Heymann MA, Spitznas U. Hemodynamic considerations in the development of narrowing of the aorta. *Am J Cardiol*. Oct 1972; 30(5): 514-25.
3. Skoda J. Demonstration eines Falles Ven Obliteration de Aorta. *Wochenblatt Zeitschrift de kaiserlichen-Konighiche Gesellschaft der Aerttze Zur Wien*. 1995; 1: 710-20.
4. Stafford MA, Griffiths SP, Gersony WM. Coarctation of the aorta: a study in delayed detection. *Pediatrics*. Feb 1982; 69(2): 159-63.
5. Thoele DG, Muster AJ, Paul MH. Recognition of coarctation of the aorta- a continuing challenge for the primary care physician. *Am J Dis Child*. Nov 1987;141(11):1201-04.
6. Norton JB Jr. Coarctation of the Aorta. In: Moller JH, ed. *Surgery of Congenital Heart Disease: Pediatric Cardiac Care Consortium*. Armonk, NY: Futura Publishing Co; 1984-1995:143-57.
7. Salahuddin N, Wilson AD, Rao PS. An unusual presentation of coarctation of the aorta in infancy: role of balloon angioplasty in the critically ill infant. *Am Heart J*. Dec 1991;122(6):1772-75.