

A Case Report of Tubercular Constrictive Pericarditis

RAJIB KUMAR BASAK, MD, AFTABUDDIN, ASIT BARAN ADHIKARY, OMAR SADEQUE KHAN,
KHAN MOHAMMAD AMANUR RAHMAN

Department of Cardiac Surgery, Bangabandhu Sheikh Mujib Medical University (BSMMU), Dhaka

Address of Correspondence: Dr. Rajib Kumar Basak, Resident, Department of Cardiac Surgery, BSMMU

Abstract:

Diagnosis of Constrictive pericarditis is sometimes become difficult because that requires a high degree of clinical suspicion due to nonspecific sign and symptoms. But in endemic area like our country the presentation of tubercular constrictive pericarditis is common. Here we report a case of 28 year Bangladeshi male with tubercular constrictive pericarditis presenting with progressive exertional dyspnea, ankle edema, puffyness of face, dry nonproductive cough. After physical examination and investigation, the patient was diagnosed as constrictive pericarditis. Patient was previously diagnosed as a tubercular patient and still now on antitubercular cat-1 chemotherapy. So finally diagnosis becomes tubercular constrictive pericarditis. After improvement of the symptoms with medical treatment, the definitive surgical intervention, pericardiectomy done. Then removed pericardial tissue was sent for histopathological examination and histopathological report confirmed the diagnosis of tubercular pericarditis. This case is a late presentation of extrapulmonary manifestation of pulmonary tuberculosis, which is present as a consequence or, complication of pulmonary tuberculosis. So, early diagnosis and treatment is very much important in this case to prevent late consequence like tubercular constrictive pericarditis.

Introduction:

Chronic constrictive pericarditis is a chronic inflammatory process that involves both fibrous & serous layers of the pericardium in which fibrous thickening of the pericardium occur. As a result of fibrous thickening of the pericardium, diastolic filling of the heart is restricted as well as reduced venous return & cardiac output.^{1,2} Many etiological factors have been identified. Among them infection, idiopathic chronic pericarditis, post cardiac surgery, mediastinal radiotherapy are important. But pericarditis caused by Mycobacterium tuberculosis is the most common cause in endemic area.^{2,3} Tubercular pericarditis still now remain as a diagnostic & therapeutic challenge for the medical practitioners even in endemic area because of its diagnostic dilemma. So if remain untreated, in the long run the chance of development of constrictive pericarditis is greatly increased.³ Here we have reported a case of constrictive pericarditis who had the history of pulmonary tuberculosis few years back.

Case Report:

A Bangladeshi male of 28 years age, nonsmoker, nonalcoholic, non-diabetic, normotensive, madrasa teacher from a low socioeconomic status presented with progressive ankle edema, puffyness of face and abdominal distension for three months, dyspnea on exertion for two months. Dry & nonproductive cough for one month. General examination revealed generalized pitting edema, swelling of face, build & nutritional status-below average, mildly anaemic, elevated jugular venous pressure, B.P.-

100/70mmHg, pulse-100/min, Respiratory rate-20/min, temperature-normal. Systemic examination of respiratory system revealed-movement of the chest wall-diminished on both side, trachea is centrally placed, expansibility of chest wall-slightly diminished on both side, percussion note were dull over mid-axillary & infrascapular line below 5th rib, normal vesicular breath sound on the upper zone & diminished on lower zone of both lung field, vocal resonance diminished & bilateral basal crepitation were present. Cardiovascular system examination revealed-no visible apex beat or any other pulsation, no palpable apex beat, no parasternal heave, no palpable p2. 1st and 2nd heart sound soft in all the areas of precordium, no added sound. Examination of abdomen reveals distended abdomen with everted umbilicus, shifting dullness positive, bowel sound present, liver 3 finger breadth from right costal margin in mid clavicular line. Patient had a past history of pulmonary tuberculosis and was treated with antitubercular drugs 2 years back. But patient cannot give the name of the drugs and clean cut duration of the treatment period. After hospitalization and taking some treatment like diuretics, antibiotics, vitamins and following few advices e.g. restricted fluid intake, high protein diet patient improved.

According to investigation, Complete Blood Count-Hb-14.3g/dl, ESR-15mm, PT-15.1 sec & INR-1.27. S.creatinine-0.8mg/dl. RBS-6.7mmol/l. S.bilirubin-40µmol/l. TSH-3.60µIU/ml. Sputum for AFB-negative. Montaux test-negative. Blood for ANA-negative. Chest X-ray-P/A view

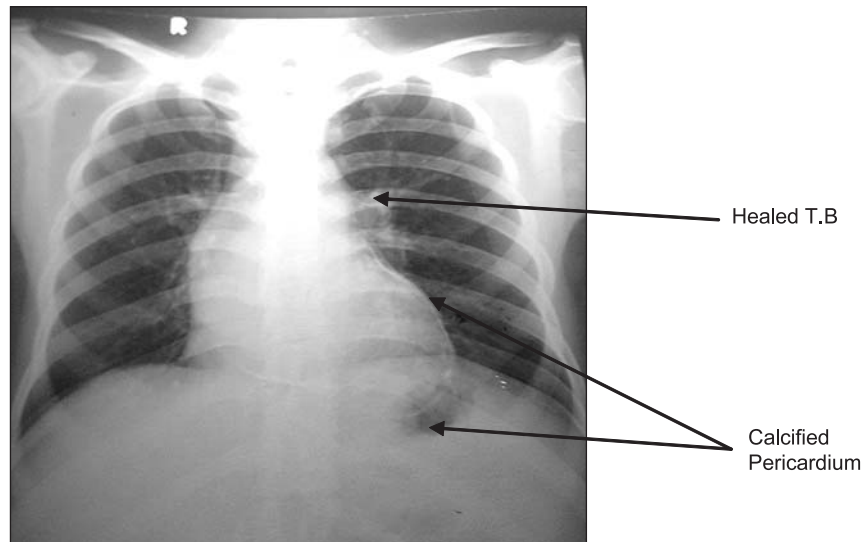


Fig.-1: X-ray chest shows calcification of pericardium on the surface of left ventricle and healed T.B on left lung near to the hilar region.

showed features of healed tuberculosis in both lung field with calcified pericardium (Fig 1). Cardiac shadow was within normal limits. Ultrasonogram of whole abdomen-moderate ascitis & congestive hepatomegaly. ECHO(2D,M)-pericardial thickened & mildly calcified(3mm),mild to moderate pericardial effusion(11mm),no diastolic collapse of RA/RVOT,IVC-dilated & loss of phasic variation in respiration, PASP-36mmHg.So depending on history, clinical findings & investigation reports, patient was diagnosed as a case of tubercular constrictive pericarditis.

After 1 month of admission, surgical procedure pericardiectomy was done by standard median sternotomy. In some areas, pericardium was stony hard and was very difficult to cut by scissor. Very consciously and slowly outlet of the heart and root of the aorta upto the origin of brachiocephalic trunk was made clear. Pulmonary artery was made clear upto its bifurcation. Part of the right atrium was made clear for emergency cardiopulmonary bypass if any serious injury occurs on the chamber of heart. Then gradually and gently left ventricle was made clear as maximum as possible. After left ventricle, left atrium, then right ventricle, right atrium, root of superior and inferior venacava was made free from constrictive covering. On both side upto phrenic nerves all thickened pericardium was removed layer by layer. During this procedure no serious injury occurred. Pericardium was sent for histopathological report. Chest was closed in layers keeping two IT tube in situ .Some straw colour fluid and thick caseous materials present in the pericardial cavity

was sent for microbial, biochemical study. Report was positive in favour of tuberculosis. Histopathological report of removed pericardium showed dense infiltration of chronic inflammatory cells & granulomas composed of epithelioid cells with few Langhans type giant cells and granulomatous inflammation consistent with tubercular pericarditis.

After operation patient's postoperative course was uneventful with improvement of heart function.

Discussion:

The case we presented here is of constrictive pericarditis which arises as a complication of tuberculosis and present to us with thickened pericardium. Other than tuberculosis constrictive pericarditis may arise as a complication of other infection, previous cardiac surgery, mediastinal radiation, direct trauma etc. But in this case there was no such history. Among them tuberculosis is uncommon in western countries, but more common in developing countries like our country.⁴ Hughes and Lipton reported maximum of their cases of constrictive pericarditis comes as a consequence of tuberculosis and all of the cases was needed surgical procedure pericardiectomy⁵. Sir Martin Lowe & colleagues reports on intriguing case of constrictive pericarditis⁶.Their reports did not mention tuberculosis as a etiological factor of constrictive pericarditis⁶. Sir Paul Arnow & John Flaherty present reports on fever of unknown origin of 60 patients. Among them 27 patients were diagnosed as extrapulmonary tuberculosis & nearly most of them tubercular constrictive

pericarditis.^{6,7} Abid Hossain Laghari & colleagues reported series of 143 surgically confirmed cases of constrictive pericarditis, among them increased pericardial thickness was seen in 37%, abnormal septal motion in 49%, atrial enlargement in 61% and almost all thickened pericardium showed tubercular pericarditis in histopathological examination.⁸ Tuberculosis accounted for 49% of the patients of constrictive pericarditis in a case series reported in 1962 in Europe. But now it becomes rare cause of pericarditis in developed countries. Although tuberculosis is still a common cause of constrictive pericarditis in developing countries especially in endemic areas like our country.⁸ Extrapulmonary tuberculosis occurs in 20% patients with tuberculosis. Among them 1-8% patient develops tubercular pericarditis and usually spread either from lung or, mediastinal/hilar lymph node, rarely as part of miliary tuberculosis.⁹ But still it remain as a diagnostic challenge to the clinician in endemic area/developing countries where pericardial manifestation of tuberculosis is 50-70% of cases whereas <5% in developed countries¹⁰. The main pathogenesis of tubercular constrictive pericarditis is the presence of pericardial effusion with predominance of polymorphonuclear leukocyte or lymphocyte exudates no mycobacteria detected. Our findings were consistent with the findings of other authors¹⁰. Then absorption of effusion occur and ultimately pericardial thickening & fibrosis occur, which develops constrictive pericarditis.¹⁰ After confirmation of diagnosis there are two therapeutic options of treatment of constrictive pericarditis which are surgical and medical treatment. Between these two options, the surgical option pericardectomy is still now considered as the only definitive treatment. In our case after confirmation of diagnosis we also gave symptomatic medical treatment and after improvement of symptom, patient under went

definitive treatment pericardectomy followed by definitive antituberculous treatment for another six months. During follow-up period patient showed marked improvement^{9, 10}. From this case study, we like to conclude that main cause of constrictive pericarditis is tuberculosis in developing country and pericardectomy followed by antituberculous drug is the choice of treatment.

Reference:

1. Liu YW, Tsui HR, Li WH, Lin LJ, Chen JH. Tuberculous constrictive pericarditis with concurrent active pulmonary tuberculosis infection: a case report. *Cases Journal* 2009; 2:1-5.
2. Nicholas TK, Eugn HB, Donald BD, Frank LH, Robert BK. Pericardial disease In: Kirklin/Barratt-Boyes Cardiac surgery, 3rd ed. New York: Churchill Livingstone; 2003. p 1779-1793.
3. Chhina D, Gupta R, Mohan B. Early diagnosis in an unusual presentation of tubercular pericarditis-A case report. *Asian Pac J Trop Dis* 2013;3:161-163.
4. Malkowska AM, Waring WS. Constrictive pericarditis is an overlooked cause of right heart failure: a case report. *Cases Journal* 2008;1:1-2.
5. Hughs FA, Lipton S. Chronic Constrictive Tuberculosis Pericarditis Report of a case with Pericardectomy. *Ann. Surg.* 1999; 12:66-74.
6. Lima MV, Cardoso JN, Cardoso CM, Brancalhao ECO, Limaco RP, Barrtto CP. Constrictive Pericarditis with Extensive calcification. *Arq Bras Cardiol* 2011; 96:7-10.
7. Lowe MD, Harcombe AA, Grace AA, Petch MC. Constrictive pericarditis and tuberculosis. *Lancet* 1997;350:1782-1784.
8. Layhari AH, Tai JM. Heavily thickened pericardium with constrictive pericarditis. *J Pak Med Assoc* 2013;63:639-641.
9. Kozarez I, Schuler G, Desch S. Constrictive pericarditis after tuberculosis in adolescence. *Grand rounds* 2011;11:111-114.
10. Altemimi HA, Altaf SY, James RK, Nata R, Kumar EB, Codispoti M.A. Difficult diagnosis-Constrictive pericarditis and its treatment: a case report. *Cases Journal* 2009; 2:1-3.