

Hypertension and Recurrent Hypokalaemia in Young Woman - A Case Report of Primary Hyperaldosteronism (Conn's Syndrome)

MD.NAZMUL HASAN¹, MD.ABDUR RAHIM¹, QUAZI MAMTAZ UDDIN AHMED¹,
MD. SYEDUL ISLAM¹, MD. RASUL AMIN², MD. ATIKUR RAHMAN¹, MD.NURUL AMIN¹

¹Department of Internal Medicine, Bangabandhu Sheikh Mujib Medical University, Dhaka-1000

²Department of cardiology, Bangabandhu Sheikh Mujib Medical University, Dhaka-1000

Address of the correspondence: Dr. Md. Nazmul Hasan, Assistant professor, Department of Internal Medicine, Bangabandhu Sheikh Mujib Medical University, Dhaka-1000, Email- nazmul_31st@yahoo.com

Abstract

Primary hyperaldosteronism is caused by most commonly due to aldosterone producing adenoma(Conn's syndrome) or bilateral adrenal hyperplasia. Clinical features may be of different type which includes hypertension in young age or resistant hypertension, recurrent hypokalaemia and characterized by increased ratio of plasma aldosterone (ng/dl) to rennin (ng/ml per hour) activity. We report a case of young woman presented with hypertension and recurrent hypokalaemia.

Key words: primary hyperaldosteronism, recurrent hypokalaemia, adrenal adenoma

Introduction

Primary hyperaldosteronism is characterized by increased aldosterone secretion and suppressed rennin activity which would clinically manifested as hypertension, hypokalaemia and was first described by J. W. Connin 1955.¹ Primary hyperaldosteronism is a cause of secondary hypertension with prevalence estimates of 5-13% of all patients with hypertension and now regarded as one of the common cause.^{2,3} The common causes of primary hyperaldosteronism are, aldosterone-producing adenoma (Conn's syndrome) or bilateral idiopathic hyperplasia and less common causes are due to primary (unilateral) adrenal hyperplasia, aldosterone-producing adrenocortical carcinoma or familial hyperaldosteronism.⁴ Primary hyperaldosteronism can sometimes pose a diagnostic dilemma as the presentation may be very varied and misleading. We report a case of a 24-year-old woman who presented with recurrent hypokalaemia which was difficult to correct and hypertension.

Case report

A 24-year-old woman was admitted in internal medicine department of Bangabandhu Sheikh Mujib Medical University (BSMMU), Dhaka with onset of hypertension at the age of 19 years of age and recurrent all four limb weakness due to hypokalaemia for 9 months. Her blood pressure was well control with losartan potassium 50 mg daily. But she developed weakness of all four limbs 9 months back and was found to be hypokalaemic since then, she had several episodes of hypokalaemia and the last one was three months ago and was put on oral potassium supplement but it was not fully correct in three months.

For two weeks, she developed severe weakness of the all four limbs and was admitted in BSMMU. The weakness had no relation with taking carbohydrate meal and alcohol and she had no family history of hypertension and hypokalaemia. General physical examination revealed pulse – 80 beat/min, blood pressure- 150/90 mm of Hg, respiratory rate -16 breaths/min and examination of the nervous system revealed only reduced muscle power of MRC grade 3/5 in all four limbs, all jerks were present and planter was flexor bilaterally. All other examination findings are normal. The investigations showed, serum electrolyte: sodium-142 mmol/l, potassium-1.71 mmol/l, chloride-103.3 mmol/l, magnesium-2.1 mg/dl, corrected calcium-9.3 mg/dl, albumin- 33 gm/dl; urinary electrolyte: sodium- 200 mmol/l, potassium-91 mmol/l, calcium-165 mg/dl and serum creatinine – 1.3 mg/dl. ECG showed prominent R wave in v_2 , ST –segment depression, T – wave inversion and pathological Q wave merged with T wave (figure-1) Urine RME, urinary PH, LFT and ABG were normal. The USG of whole abdomen and echocardiogram were normal. Serum aldosterone and plasma renin were 379.10 pg/ml (early morning, normal range: 20-180 pg/ml) and 10 pg/ml (normal range: 4-37.25 pg/ml) respectively and aldosterone to renin ratio is 37.91. The CT -scan of adrenal glands with contrast showed left sided adrenal adenoma (figure-2). She was treated with oral and intravenous potassium supplement before diagnosis but never corrected until we added spiranolactone 100 mg daily with losartan potassium 50 mg OD to control blood pressure. Now she is on this drug without any potassium supplement and her potassium level was 4.3 mmol/l. Simultaneously, we consulted surgeon and she is listed for left sided adrenalectomy.

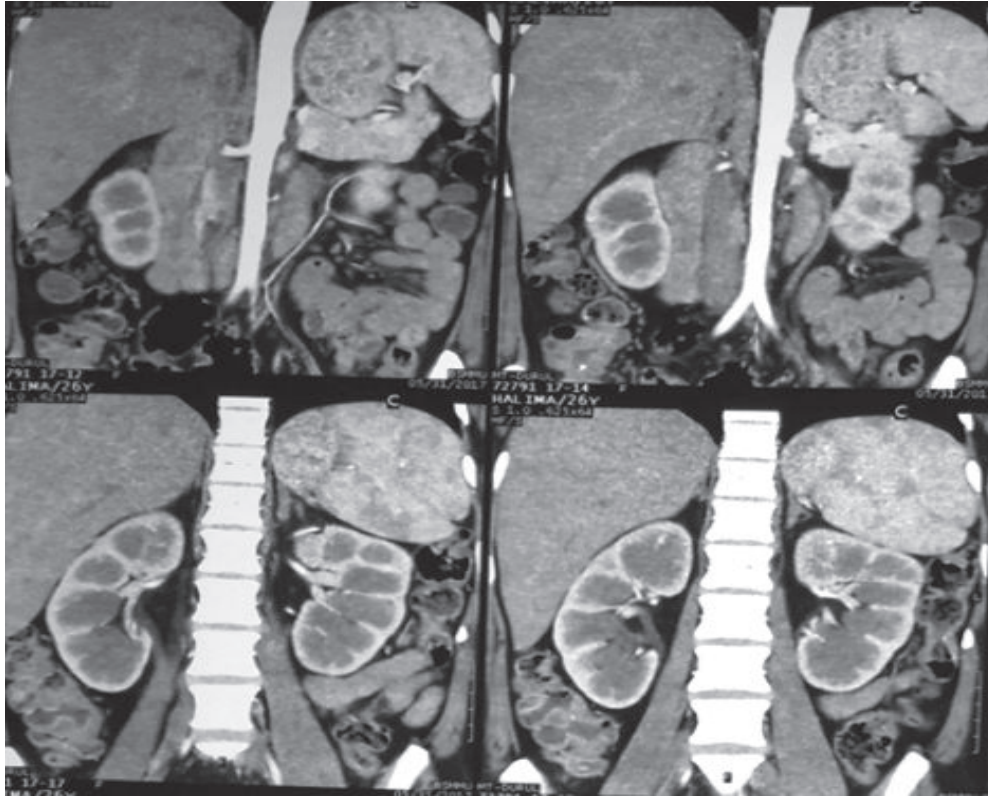


Fig.-2: CT-scan showing left sided adrenal adenoma(arrow marked)

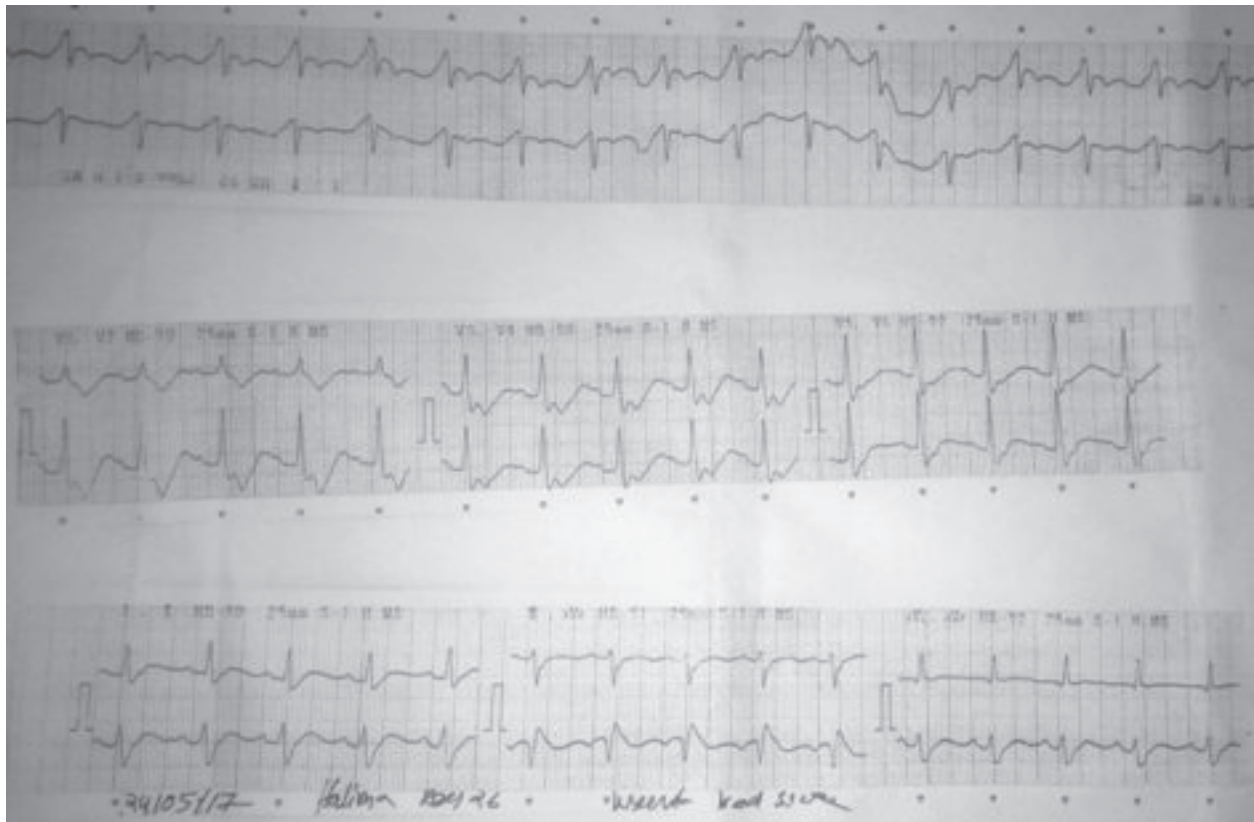

Fig.-1: ECG

Discussion

Recent data, suggest that primary hyperaldosteronism is one of the commonest cause of secondary hypertension and commonly occurs between 30 and 50 years of age.⁵ Causes of primary hyperaldosteronism unilateral adenoma (30%), unilateral (2%) and bilateral (60%) adrenal hyperplasia, familial hyperaldosteronism (1%) and adrenal carcinoma with aldosterone hypersecretion (<1%). The uncontrollable synthesis of aldosterone leads to increased sodium reabsorption, kaliuresis and renin suppression. All of the above produces arterial hypertension, which affects target organs (heart, kidneys, brain) more severely than essential hypertension does.⁶

Primary hyperaldosteronism is usually associated with hypokalemia, renal potassium leakage, and arterial hypertension due to excessive aldosterone secretion.⁷ However, the clinical and biological spectrum of primary hyperaldosteronism varies. In particular, hypokalemia is uncommon and present only in 7 to 38% of cases.⁸ Primary hyperaldosteronism can also present as flaccid paraparesis which is more common in Oriental people.⁸ Our patient presented with recurrent flaccid quadriparesis due to hypokalaemia which is only present in a few percentage of the patient and she had young onset of hypertension.

The diagnostic approach of primary hyperaldosteronism can be summarised in three main steps: plasma Aldosterone Concentration (PAC), plasma Renin Activity (PRA) and calculation of PAC/PRA Ratio calculation. PAC/PRC rates over 23.6 are diagnostic of PA, with a sensitivity of 97% and a specificity of 94%. Aldosterone receptor antagonists should be discontinued at least 6 weeks before the examination.⁹ Our patient had a PAC/PRA ratio of 37.91 which is diagnostic of primary hyperaldosteronism. Confirmation of primary hyperaldosteronism is based on oral sodium load test, saline infusion test and hydrocortisone suppression test. Oral sodium load test includes the determination of sodium and aldosterone concentration in 24-hour urine, after 3 days of increased salt intake. Rates of aldosterone >12 µg and Sodium >200mmols are diagnostic of PA.⁹ We could not do the test due to unavailability. The hydrocortisone suppression test is rarely performed in most centers nowadays.⁹

Distinction of the disease subtype is based on CT (MRI shows no superiority), adrenal vein catheterization with venous sampling and genetic screening for the familial types of the disease.⁵ In our patient, contrast CT-scan of adrenal glands demonstrated unilateral adrenal adenoma

. We could not do venous sampling due to unavailability. The therapeutic approach, in unilateral forms of primary hyperaldosteronism preferably adrenalectomy, while bilateral disease are treated conservatively, with aldosterone receptor antagonists.^{10,11} Our patient was treated with spironolactone, titrated up to 100 mg daily and losartan potassium 50mg daily, leading to optimal control of blood pressure and she listed for left sided adrenalectomy.

In conclusion, primary hyperaldosteronism can be presented with diagnostic dilemma to the clinicians because, it has variable presentations. Screening for hyperaldosteronism should be undertaken more frequently in cases of young or resistant hypertension, hypertension with spontaneous or secondary hypokalemia and in patients with hypokalaemic paralysis to treat them effectively. Choice of treatment in unilateral adrenal adenoma with hyperaldosteronism is adrenalectomy but before that patient should be normotensive with medical management.

References

1. Conn JW: Primary aldosteronism, a new clinical syndrome. *J Lab Clin Med*; 1955;45:3-17
2. Young WF: Primary aldosteronism—renaissance of a syndrome: Review. *Clin Endocrinol*; 2007;66:607-18
3. Krysiak R, Okopie D B, Herman ZS: Primary aldosteronism. *Przegl Lek*; 2007;64(1):31-6.
4. Young WF Jr: Minireview: primary aldosteronism—changing concepts in diagnosis and treatment. *Endocrinology*; 2003;144(6):2208-13
5. Hannesmann A, Wallaschofski H. Prevalence of primary aldosteronism in patient's cohorts and in population-based studies—a review of the current literature. *Horm Metab Res*. 2012; 44: 157-62
6. Viola A, Tizzani D, Monticone S, Crudo V, Galmozzi M, Burrello J, et al. Diagnosis and treatment of unilateral forms of primary aldosteronism. *Curr Hypertens Rev*. 2013; 9: 156-65.
7. Vallotton MB: Primary aldosteronism. *Clin Endocrinol*; 1996;45:47-60
8. Conn JW, Rovner D, Cohen E, Nesbit R: Normokalemic primary hyperaldosteronism. Its masquerade as essential hypertension. *J Am Med Assoc*; 1966;195:111-6.
9. Young WF. Primary aldosteronism: renaissance of a syndrome. *Clin Endocrinol (Oxf)*. 2007; 66: 607-18.
10. Sukor N, Gordon RD, Ku YK, Jones M, Stowasser M. Role of unilateral adrenalectomy in bilateral primary aldosteronism: a 22-year single center experience. *J Clin Endocrinol Metab*. 2009; 94: 2437-45.
11. Ronconi V, Turchi F, Appolloni G, di Tizio V, Boscaro M, Giacchetti G. Aldosterone, mineralocorticoid receptor and the metabolic syndrome: role of the mineralocorticoid receptor antagonists. *Curr Vasc Pharmacol*. 2012; 10: 238-46.