

CASE REPORT

A Giant Left Atrium due to Rheumatic Mitral Regurgitation, Outcome after Left Atrial Reduction Surgery with Mitral Valve Replacement

ISTIAQ AHMED¹, SOROWER HOSSAIN¹, ANKAN KUMAR PAUL²

¹Department of Cardiac Surgery, Dhaka Medical College Hospital (DMCH), Dhaka, ²Postgraduate Resident, Cardiac Surgery, National Institute of Cardiovascular Disease (NICVD), Dhaka.

Address of Correspondence: Dr. Istiaq Ahmed, Department of Cardiac Surgery, DMCH, Dhaka,
E-mail: ankankumar64@gmail.com

Abstract:

A trans-thoracic echocardiography and chest radiograph of a 26 year old lady diagnosed as rheumatic mitral regurgitation with atrial fibrillation revealed a giant left atrium of 10.9 cm size with symptoms of dyspnoea and palpitation. The patient was treated with left atrial size reduction along with mitral valve replacement surgery and showed an excellent and quick recovery with total disappearance of symptoms and restoration of sinus rhythm only within few days.

Key Words: Giant left atrium, Rheumatic mitral regurgitation, Left atrial reduction surgery.

University Heart Journal 2018; 14(1): 42-44

Introduction:

In case of rheumatic mitral valvular disease sometimes the left atrium gets dilated and/or Hypertrophied. The incidence is 0.3%. It is more common with mitral regurgitation. Chest X-ray is the cheapest method to diagnose it. But a more sensitive diagnosis can be made with trans-thoracic echocardiography that is also less costly and more accurate. Prognosis depends upon the timing of surgery and operative technique.

Case Report:

Mrs. Asia Khatun, 25 years old, lady was admitted in dept. of cardiac surgery, National Institute of Cardiovascular Diseases, Bangladesh in april, 2016 with exertional dyspnea and palpitation for one and a half years, which was mild initially and became severe for last 2 months. She gave history of rheumatic fever at the age of 14 years and didn't complete the treatment.

On examination her pulse was 105/min, irregularly irregular, pulse deficit present as heart rate was 140/min, BP was 90/60 mm of Hg. Apex beat was shifted below and laterally (It 6th intercostal space 12 cm from midline). Systolic thrill was present in mitral area. 1st heart sound was soft. A pansystolic murmur was audible over mitral area radiating to left axilla.

Chest radiograph showed cardiomegaly. Cardiothoracic ratio 0.86, double right heart border was seen (Fig 1). ECG showed atrial fibrillation. Trans-thoracic echocardiography showed

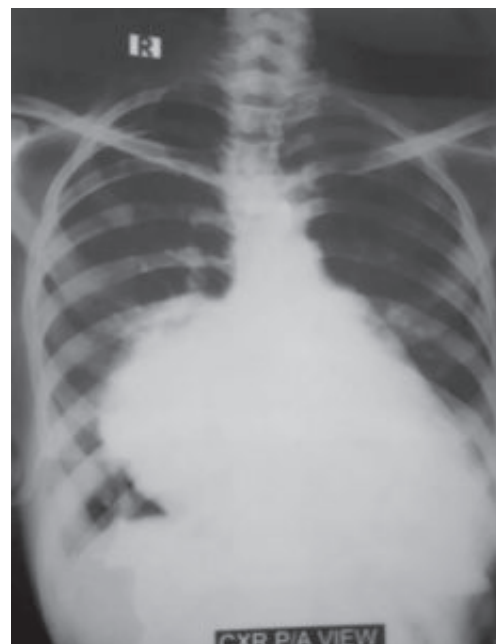


Fig.-1: Pre operative chest X-ray P/A view showing giant left atrium

severe mitral regurgitation due to rheumatic heart disease with pulmonary hypertension (PASP- 40mm Hg) with giant left atrium, the diameter of which was 109mm (Fig 2). Other lab values were normal.

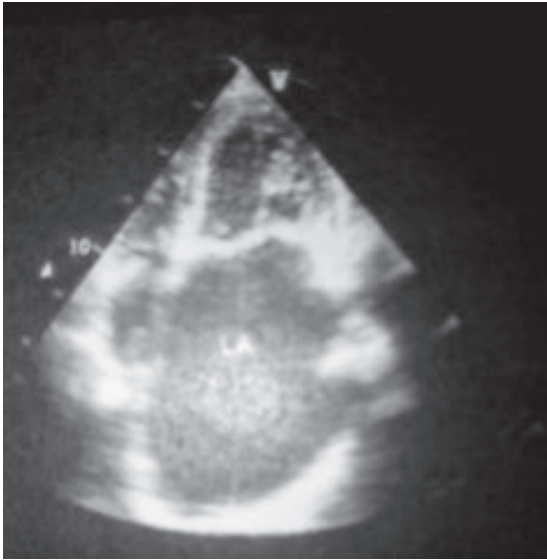


Fig.-2: Pre-operative echocardiogram showing giant left atrium

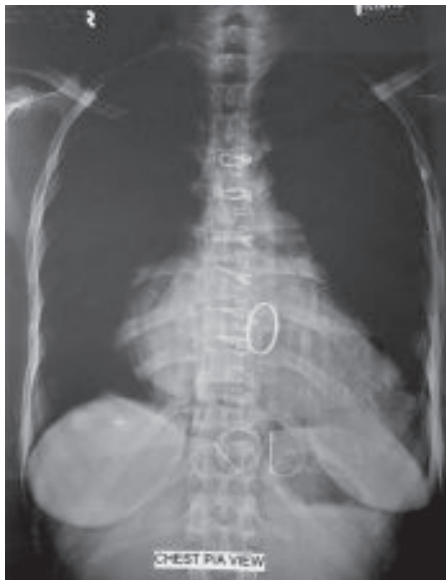

Fig.-3: Post operative X-ray chest P/A view showing LA size has reduced.

Operative procedure

With all aseptic precautions median sternotomy was done under general anaesthesia. Pericardial sac was opened and cardio-pulmonary bypass was established. The left atrium was found hugely dilated. (Fig 4) Left atriotomy was done and mitral valve was identified.

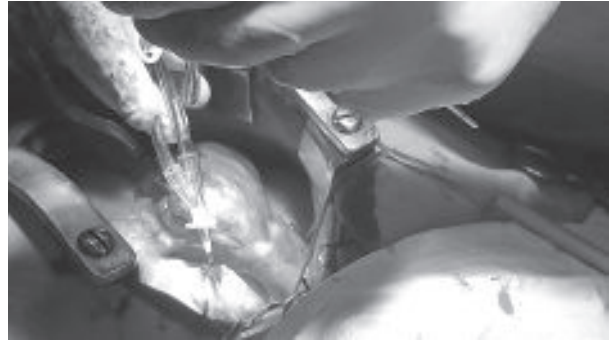


Fig.-4: Per-operative image of giant left atrium

Mitral valve replacement with 31mm Saint Judes medical bi-leaflet mechanical valve was done along with external ligation of left atrial appendage and internal plication of left atrium (Fig 5). Aortic cross clamp time was 72 minutes and extracorporeal circulation time was 114 minutes. Post operative period in ICU was uneventful. Patient was discharged on 8th POD.



Fig.-5: Mechanical mitral valve in situ

Follow up

In the follow up x-ray after 5 days the cardiothoracic ratio reduced to 0.65 (Fig 3). On the 15th post operative day follow up trans-thoracic echocardiography revealed LA size of 47mm. patient became symptomless totally and atrial fibrillation was corrected. Follow up after 3 months showed the patient remained symptoms free and trans-thoracic echocardiography revealed normally functioning valve and normal sized left atrium. The patient remain asymptomatic on the subsequent follow up upto 2 years. The patient is on minimum medication and leading a normal life.

Discussion:

Giant left atrium is a rare condition with incidence of 0.3¹. Its most common cause is mitral regurgitation due to chronic rheumatic heart disease. It has seldom been seen in a patient with mitral regurgitation due to non-

rheumatic cause. Only 2-3 cases has been reported. The proposed hypothesis for it that rheumatic pancarditis damages the entire heart including left atrium and right atrium. This damaged left atrium dilates easily when mitral regurgitation fills the atrium with large volume of blood². The cause of giant left atrium in our patient was mitral regurgitation with rheumatic heart disease.

According to definition of Isomura and co-workers, left atria larger than 6cm diameter is termed as giant left atrium³. Hurst proposed that a giant left atrium is defined as one that touches the right lateral side of the chest wall in chest X-ray². Piccoli et al defined the giant left atrium as a cardiothoracic ratio on chest X-ray of >0.7 combined with left atrial antero-posterior diameter of >8cm in trans thoracic echocardiography⁴. The largest left atrial diameter reported was 18.7cm in an symptomatic patient, but the patient didn't survive post operatively⁵. Sinatra and colleagues⁶ reported the case of a patient with left atrial diameter of 17 cm which was treated successfully. The left atrial diameter in our patient was 10.9 cm in trans thoracic echocardiography and a cardio-thoracic ratio of 0.86 in chest x-ray posterior anterior view.

Some surgeons believe that effect of rheumatic process on the elastic fibers of the tissue is irreversible. This process causes strain and the tone is lost. As a result the left atrial enlargement is irreversible. So they prefer left atrial plication by believing that with reduction of left atrial size along with mitral valve replacement the pressure effect will be reduced with favorable effect on post-operative course¹. Previously it was also thought that only mitral valve replacement surgery will result in reduction of left atrial size in a long run. But several comparative studies showed that the plication procedure causes a significant decrease in the incidence of low-output syndrome and respiratory failure postoperatively,

as well as a marked decrease in mortality. So it has been concluded that the plication procedure is an effective means of relieving compression in the presence of giant left atrium⁷. In our case we found it to be true. With external ligation of left atrial appendage and internal plication of left atrium the post-operative recovery was completely smooth. Patient became symptom free totally and atrial fibrillation was corrected.

Conclusion:

Giant left atrium due to mitral regurgitation with chronic rheumatic heart disease is a condition with poor prognosis. but with correct surgical procedure it can be managed in an excellent way and patient may remain symptom free for rest of the life.

Reference:

1. Maghraby AE and Hajar R. Giant left atrium: A review. *Heart views* 2012 Apr-Jun; 13(2): 46-52.
2. Hurst JW. Memories of a patient with giant left atrium. *Circulation* 2001; 104: 2630-1.
3. Isomura T, Hisatomi K, Hirano A, Maruyama H, Kosuga K, Ohishi K, et al. Left atrial plication. *J card surg* 1993; 8: 365.
4. Piccoli GP, Massini C, Di Eusanio G, Ballerini L, Tacobone G, Soro A, et al. Giant left atrium and Mitral valve disease; Early and late results of surgical treatment in 40 cases. *J Cardiothoracic surg*, 1984; 25; 328-36.
5. Ates M, Sensoz Y, Abay G, Akcar M. Giant left atrium with rheumatic mitral stenosis. *Tex Heart Inst J*. 2006; 33: 389-391.
6. Sinatra R, Pulitani I, Antonazzo A, Melina G. A novel technique for giant left atrium reduction. *Eur J Cardiothoracic Surg* 2001; 20: 412-4.
7. Kawazoe K, Beppu S, Takahara Y, Nakajima N, Tanaka K, Ichihashi K, et al. Surgical treatment of giant left atrium combined with mitral valvular disease. Plication procedure for reduction of compression to the left ventricle, bronchus, and pulmonary parenchyma. *J Thorac Cardiovasc Surg*. 1983 Jun;85(6):885-92.