

# Evaluation of LVEF with Changing left Ventricular Morphology in Hypertrophic Cardiomyopathy

MD MOHIUDDIN MASUM<sup>1</sup>, RAYHAN SHAHREAR<sup>2</sup>, ZINNAT ARA YESMIN<sup>3</sup>, LATIFA NISHAT<sup>3</sup>, LAILA ANJUMAN BANU<sup>3</sup>

<sup>1</sup>Department of Anatomy, Anwer Khan Modern Medical College, Dhaka, Bangladesh, <sup>2</sup>Department of Anatomy, Ibrahim Medical College, Dhaka, Bangladesh, <sup>3</sup>Department of Anatomy, Bangabandhu Sheikh Mujib Medical University (BSMMU), Dhaka, Bangladesh.

**Address for Correspondence:** Dr. Md. Mohiuddin Masum, Assistant Professor, Department of Anatomy, Anwer Khan Modern Medical College, Email: dr.masum@outlook.com

## Abstract:

**Background:** Hypertrophic cardiomyopathy (HCM) is the most frequent type of cardiomyopathy. HCM is a disease of changing cardiac morphology that causes various form of cardiac dysfunction. HCM patients may remain asymptomatic and undiagnosed for a long time. If they become symptomatic, they commonly present with breathlessness, chest discomfort, and exertion. It is also responsible for the sudden cardiac death. Proper assessment of the functional status of the heart is required for proper management strategies of HCM. **Objective:** The objective of the study was to assess the IVS, PWT and LVEF in different cardiac phenotypes as well as to draw correlation among them. **Materials and method:** A descriptive cross-sectional study was undertaken on thirty-four adult Bangladeshi hypertrophic cardiomyopathy patients (thirty-one male, three female). The study was carried out in the Department of Anatomy, BSMMU. Diagnoses adult HCM patients were selected as study patients. Transthoracic echocardiography was done to assess the interventricular septal thickness (IVS), left ventricular posterior wall thickness (PWT) and left ventricular ejection fraction (LVEF). **Result:** The changes in the value of the left ventricular ejection fraction shows significant correlation with left ventricular posterior wall thickness, rather than the interventricular septal thickness. **Conclusion:** Though significant correlation between left ventricular ejection fraction and left ventricular posterior wall thickness was found, a large cohort study could be done to see the long term outcome of such correlation.

*University Heart Journal 2019; 15(1): 12-15*

## Introduction:

Hypertrophic cardiomyopathy (HCM) is the most frequent type of cardiomyopathy.<sup>1-2</sup> Majority of the HCM patients may remain asymptomatic and undiagnosed for a long time. If they become symptomatic, they commonly present with breathlessness, chest discomfort, and exertion.<sup>3-4</sup> It is also responsible for the sudden cardiac death (SCD).<sup>3,5</sup> In HCM, hypertrophy of the myocardium occurs in the absence of any other causes.<sup>6-7</sup> Prevalence of HCM is about 0.2%, irrespective of gender, race or ethnicity.<sup>1,8</sup>

In HCM, histological disarray occurs within the cardiomyocytes. It occurs due to the molecular changes in their myofilaments structure.<sup>6</sup> The increment of the bulk of the cardiac tissue requires extra perfusion. Especially in the time of stress when there is an increase

the cardiac output. Increase in heart rate puts the heart to an increased workload. However, the abnormal proliferation of the tissue and its disarranged direction of fibers hampers proper perfusion.<sup>5</sup>

It is stated that a better assessment of the functional status of the heart is required for proper management strategies of HCM.<sup>8</sup> The objective of the study was to assess the interventricular septal thickness (IVS), left ventricular posterior wall thickness (PWT) and left ventricular ejection fraction (LVEF) in different cardiac phenotypes as well as to draw correlation among them.

## Materials and Methods:

A descriptive cross-sectional study was undertaken on 34 adult Bangladeshi hypertrophic cardiomyopathy patients (thirty-one male, three female). The study was

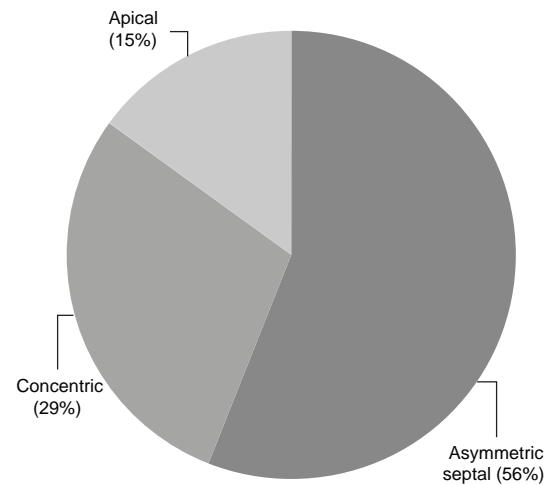
carried out in the Department of Anatomy, Bangabandhu Sheikh Mujib Medical University (BSMMU), Dhaka, Bangladesh. Study patients were collected from Bangabandhu Sheikh Mujib Medical University (BSMMU) and Ibrahim Cardiac Hospital and Research Institute (ICHRI) from March 2017 to February 2018. The Institutional Review Board of BSMMU approved this research. Preliminary selection of the patients was made if the patients have already been diagnosed as a case of HCM by a registered cardiologist. The patients were selected using a patient selection checklist according to the inclusion and exclusion criteria.

Transthoracic echocardiography was done. Analysing the echocardiographic thickness of the cardiac walls the HCM patients were classified into three types according to the cardiac phenotypes of HCM, and a change in the cardiac functions was estimated. Type of HCM where the interventricular septum is thickened and the ratio of the thickness of the interventricular septum to that of the posterior free wall is  $\geq 1.3$  was considered as asymmetric septal HCM.<sup>9-10</sup> Concentric HCM was identified where the ventricular wall is thickened diffusely, and the ratio of the thickness of the interventricular septum to that of the posterior free wall is  $< 1.3$ .<sup>9-10</sup> When the apex is thickened more than 15mm or the ratio of the thickness of the apex to that of the basal wall is  $\geq 1.3$  was considered as apical HCM.<sup>9-10</sup> Frequencies of the different types of HCM were estimated. Systolic function was assessed by measuring by measuring left ventricular ejection fraction (LVEF). Correlation the interventricular septal thickness and left ventricular posterior wall thickness with the left ventricular ejection fraction (LVEF) was done. Mean values were determined and statistical analysis was done

in SPSS. Bivariate correlation was done in Pearson's method to determine relation between LVEF with IVS and PWT.

### Result:

Thirty-four HCM patients were included, and they were classified into three types according to the cardiac phenotype. Frequency distribution of cardiac phenotypes is shown in figure I. Among the thirty-four HCM patients, 56% patients had asymmetric septal hypertrophy, 29% had concentric hypertrophy, and 15% had the apical type of HCM.



**Fig-I:** Percentage frequencies of cardiac phenotypes of HCM.

The mean interventricular septal thickness was 19.59 mm. But in the apical type it was also considerably low (14.80 mm). The mean posterior wall thickness was 13.68 mm, and it was statistically significant higher in concentric HCM (19.20 mm), shown in table I.

**Table-I**  
*Echocardiographic characteristics of different cardiac phenotypes of HCM*

Echocardiographic characteristics	Asymmetric septal (n=19)	Concentric (n=10)	Apical (n=5)	Combined (n=34)	p value
	Mean $\pm$ SD	Mean $\pm$ SD	Mean $\pm$ SD	Mean $\pm$ SD	
IVS (mm)	20.63 $\pm$ 3.547	20.20 $\pm$ 4.917	14.80 $\pm$ 4.438	19.65 $\pm$ 4.48	*0.026
PWT (mm)	11.53 $\pm$ 2.170	19.20 $\pm$ 3.615	10.80 $\pm$ 1.789	13.68 $\pm$ 4.44	*<0.001
LVEF (%)	66.84 $\pm$ 8.235	72.30 $\pm$ 8.354	67.80 $\pm$ 3.899	68.59 $\pm$ 7.993	0.134

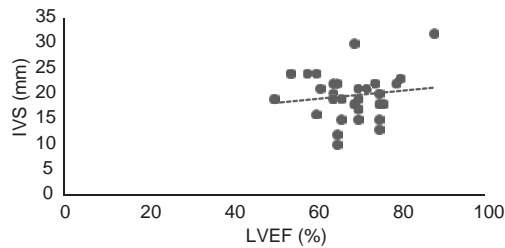
IVS= Interventricular Septal Thickness

PWT= Posterior wall thickness

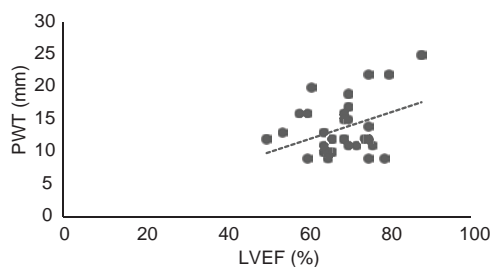
LVEF= Left ventricular ejection fraction

\*p value indicates significant correlation

The changes in the value of the left ventricular ejection fraction shows significant correlation with left ventricular posterior wall thickness, rather than the interventricular septal thickness, shown in figure II, figure III and table II.



**Fig.-2:** Correlation between LVEF and IVS where dotted line is slightly sloped and bears no significant correlation.



**Fig.-3:** Correlation between LVEF and IVS where dotted line is highly sloped and indicates a significant correlation.

**Table-II**

Correlation with LVEF with IVS and PWT

	Left Ventricular Ejection Fraction	
	Pearson Correlation	p value
Interventricular Septal Thickness	0.137	0.440
Left ventricular Posterior wall thickness	0.356	*0.039

\*p value indicates significant correlation

**Discussion:**

The interventricular septum is usually found to be the most thickened part of the ventricular wall. In this study, the mean value of the interventricular septal thickness was found 19.65 mm. Espinola-Zavaleta et al. found the interventricular septal thickness in concentric HCM was lower than asymmetric septal HCM.<sup>11</sup> However, we found that in our study population interventricular septal thickness this two group was almost similar. The overall

value observed in this study was similar to that of the other reviews.<sup>12-14</sup>

Another critical measurement of the ventricular is posterior wall thickness. The clinical diagnosis made by the physician with echocardiography is mostly based on the ratio of the interventricular septal thickness to the posterior wall thickness. The cut-off value for differentiating the type is 1.3.<sup>9-10</sup> In asymmetric septal HCM, the thickness of the interventricular septum increases in a higher amount than that of the posterior wall. So, the ratio is larger than in concentric HCM, where the cardiac wall is thickened diffusely. In the apical type, the apex is thickened, and the interventricular wall and the posterior wall may or may not be thickened. We found the posterior thickness was 13.68 mm, which relatively corresponds to the other reviews.<sup>13,15</sup>

In present study, average LVEF was 68.59% and LVEF was higher in concentric HCM than that of the other phenotype. Mandal et al. found LVEF 53%, which is slightly lower than the other studies.<sup>16</sup> LVEF in concentric HCM was higher than other types of HCM in present study (72.30%), whereas LVEF in asymmetric septal HCM was higher in a study by Espinola-Zavaleta (67%).<sup>17</sup> The values found in this study was significant among the cardiac phenotypes of HCM.

In HCM there are variable morphological changes as well as functional changes, that includes both the systolic and diastolic dysfunction. Echocardiographic pattern of the different phenotypes impacts significantly on the clinical course and prognosis of the disease.<sup>18</sup> Mild and atypical hypertrophy are associated with an increased risk of LV dysfunction and heart failure compared with the massive hypertrophy pattern.<sup>19</sup>

**Conclusion:**

We did not found any study in our country that analyzed these variables for correlation. A large cohort study could be done in Bangladeshi population.

**Acknowledgments:**

The authors would like to thank and express their gratitude to all the clinicians for their generous effort in my thesis work, especially Professor Dr. M. Nazrul Islam, Dr. SM Ahsan Habib, Associate Professor, Dr. Mohammad Faisal Ibne Kabir, Assistant Professor, Department of Cardiology, BSMMU.

**Conflict of Interests**

The authors have no financial or proprietary interest in the subjects matter to this article.

**Ethical Issues:**

The study was conducted after receiving ethical approval from the Institutional Review Board of BSMMU. The participation of the clinicians and patients in this study were voluntary. Informed written consent was taken from each patient. Anonymity and confidentiality of the information was strictly maintained.

**References:**

- Compton G, Nield L, Dragulescu A, Benson L, Grosse-Wortmann L. Echocardiography as a Screening Test for Myocardial Scarring in Children with Hypertrophic Cardiomyopathy. *International journal of pediatrics*. 2016;2016:6.
- Voilliot D, Huttin O, Hammache N, Filippetti L, Vaugrenard T, Aliot E, et al. Impact of Global and Segmental Hypertrophy on Two-Dimensional Strain Derived from Three-Dimensional Echocardiography in Hypertrophic Cardiomyopathy: Comparison with Healthy Subjects. *Journal of the American Society of Echocardiography*. 2015;28(9):1093-102.
- Bashyam MD, Purushotham G, Chaudhary AK, Rao KM, Acharya V, Mohammad TA, et al. A low prevalence of MYH7/MYBPC3 mutations among familial hypertrophic cardiomyopathy patients in India. *Molecular and cellular biochemistry*. 2012;360(1-2):373-82.
- Lind JM, Chiu C, Semsarian C. Genetic basis of hypertrophic cardiomyopathy. *Expert review of cardiovascular therapy*. 2006;4(6):927-34.
- Houston BA, Stevens GR. Hypertrophic cardiomyopathy: a review. *Clinical Medicine Insights Cardiology*. 2014;8(Suppl 1):53-65.
- Binder J, Ommen SR, Gersh BJ, Van Driest SL, Tajik AJ, Nishimura RA, et al. Echocardiography-guided genetic testing in hypertrophic cardiomyopathy: septal morphological features predict the presence of myofilament mutations. *Mayo Clinic proceedings*. 2006;81(4):459-67.
- Maron BJ, McKenna WJ, Danielson GK, Kappenberger LJ, Kuhn HJ, Seidman CE, et al. American College of Cardiology/European Society of Cardiology clinical expert consensus document on hypertrophic cardiomyopathy. A report of the American College of Cardiology Foundation Task Force on Clinical Expert Consensus Documents and the European Society of Cardiology Committee for Practice Guidelines. *Journal of the American College of Cardiology*. 2003;42(9):1687-713.
- Klues HG, Schiffrers A, Maron BJ. Phenotypic spectrum and patterns of left ventricular hypertrophy in hypertrophic cardiomyopathy: morphologic observations and significance as assessed by two-dimensional echocardiography in 600 patients. *Journal of the American College of Cardiology*. 1995;26(7):1699-708.
- De Garate E, Dastidar AG, Singhal P, Venuti G, Amadu A, Baritussio A, et al. Prevalence and CMR characteristics of apical HCM. *Heart*. 2016;102(Suppl 3):A4-A5.
- Singhal P, Dastidar AG, Giuseppe V, Amadu A, Baritussio A, Scatteia A, et al. Apical Versus Non-apical Hypertrophic Cardiomyopathy (HCM): Insight from Cardiac Magnetic Resonance Imaging. *Heart*. 2016;102(Suppl 6):A104-A105.
- Espinola-Zavaleta N, Vega A, Basto DM, Alcantar-Fernandez AC, Guarner Lans V, Soto ME. Survival and clinical behavior of hypertrophic cardiomyopathy in a latin american cohort in contrast to cohorts from the developed world. *Journal of cardiovascular ultrasound*. 2015;23(1):20-6.
- Reant P, Donal E, Schnell F, Reynaud A, Daudin M, Pillois X, et al. Clinical and imaging description of the Maron subtypes of hypertrophic cardiomyopathy. *The international journal of cardiovascular imaging*. 2015;31(1):47-55.
- Gruner C, Ivanov J, Care M, Williams L, Moravsky G, Yang H, et al. Toronto hypertrophic cardiomyopathy genotype score for prediction of a positive genotype in hypertrophic cardiomyopathy. *Circulation Cardiovascular genetics*. 2013;6(1):19-26.
- Elliott PM, Poloniecki J, Dickie S, Sharma S, Monserrat L, Varnava A, et al. Sudden death in hypertrophic cardiomyopathy: identification of high risk patients. *Journal of the American College of Cardiology*. 2000;36(7):2212-8.
- Mirza SJ, Radaideh GA. Pattern of left ventricular hypertrophy seen on transthoracic echo in patients with hypertensive cardiomyopathy when compared with idiopathic hypertrophic cardiomyopathy. *JPMA The Journal of the Pakistan Medical Association*. 2013;63(1):16-9.
- Mandal AK, Chowdhury AHK, Choudhury AK, Islam AKMM, Guha B. Echocardiographic Evaluation of Left Ventricular Diastolic Function after Percutaneous Coronary Intervention in Patients with Coronary Artery Disease. *Cardiovascular Journal*. 2012;4(3).
- Espinola-Zavaleta N, Vega A, Basto DM, Alcantar-Fernández AC, Guarner Lans V, Soto ME. Survival and Clinical Behavior of Hypertrophic Cardiomyopathy in a Latin American Cohort in Contrast to Cohorts from the Developed World. *Journal of cardiovascular ultrasound*. 2015;23(1):20-6.
- Parato VM, Antoncicchi V, Sozzi F, Marazia S, Zito A, Maiello M, et al. Echocardiographic diagnosis of the different phenotypes of hypertrophic cardiomyopathy. *Cardiovascular ultrasound*. 2016;14(1):30.
- D'Andrea A, Caso P, Severino S, Cuomo S, Capozzi G, Calabro P, et al. Prognostic value of intra-left ventricular electromechanical asynchrony in patients with hypertrophic cardiomyopathy. *European heart journal*. 2006;27(11):1311-8.