

CASE REPORT

Retrieval of a fractured instrument using File Braiding technique: A case report

* Md. Farid Uddin¹, Md. Samsul Alam², Md. Mujibur Rahman Howlader³, Ali Azgor Moral⁴

¹Assistant Professor, Department of Conservative Dentistry & Dental Radiology, Pioneer Dental College & Hospital, Dhaka.

²Professor, Chairman, Department of Conservative Dentistry & Endodontics, Dean, Faculty of Dentistry, BSM Medical University, Dhaka.

³Associate Professor, Department of Conservative Dentistry & Endodontics, BSM Medical University, Dhaka.

⁴Professor, Department of Conservative Dentistry & Endodontics, BSM Medical University, Dhaka.

ARTICLE INFO

Article history:

Received : 05 December 2011

Accepted : 25 February 2012

Keywords:

Root canal treatment,
Broken instrument, Endodontic failures,
Apical third of root.

ABSTRACT

In the present study, a conservative approach for removal of a fractured instrument located at the apical root area of maxillary left central incisor of a 35 years old male was performed and the clinical outcome was evaluated. On clinical examination, localized swelling associated with discharge of pus was seen near to the affected tooth. Furthermore, the tooth was restored with temporary filling and it was severely discolored. On radiographic examination, a radiolucent area around the apex was seen and there was a fractured instrument at the apex of the tooth. Tooth was then treated as nonsurgical endodontic technique and an attempt to remove the fractured instrument was undertaken. The results confirms that fractured instrument was successfully removed by using the File Braiding technique and after 3 months follow up, the tooth was asymptomatic and radiograph shows complete healing of the periapical lesion.

Introduction

Of all the complications that might occur while you are doing an endodontic procedure, one of the very worst is instrumentation breakage—in other words, “file separation” in the canal. The frequency of remaining fragments ranges between 2% and 6% was reported in a previous study.¹ The fracture fragment blocks the access to thorough root canal cleaning and shaping procedure. This is also significant in non vital

tooth with periapical pathosis as it affects the final outcome of the endodontic therapy. Before obturation, an attempt to retrieve the instrument should be made before obturating of the root canal or embarking upon surgery. However, orthograde retrieval is often difficult, time consuming and the success rate ranges from 55 – 79%.²

A numbers of studies have indicated that attempts to remove fractured instruments in the apical third are often unsuccessful and may lead to excessive dentine removal and weakening of the tooth, ledge formation, root perforation and apical extrusion of the fragment into the periradicular tissues.^{3, 4, 5} Therefore, ultrasonic instrumentation and microtube delivery

* Address of Correspondence:

Dr. Md. Farid Uddin

Assistant Professor, Department of Conservative Dentistry & Dental Radiology,
Pioneer Dental College & Hospital, Dhaka .
Cell – 01716291504. E-mail: faridrmc@yahoo.com

methods are said to improve the potential and safety when removing broken instruments.⁶⁻⁷ Recently, File braiding technique is one among many methods of instrument retrieval. This technique is useful in retrieving pieces of fractured instrument or silver point from the root canal system and in general a success rate of 55% has been reported.⁸ In this case report, the successful retrieval of a separated file tightly wedged in the root apex of a maxillary left central incisor using File Braiding technique was performed and clinical outcome was evaluated.

Case Report

A 35 year old male came to our Department of Conservative Dentistry and Endodontics, BSMMU with a complaint of localized swelling

& discharge of pus on the labial surface in relation to his maxillary left central incisor (Fig. – 1). He also said that he received a trauma from tube well handle a few years ago and he went to a local dentist. Following root canal treatment of maxillary left central incisor, he develops swelling and discharge of pus.

On clinical examination, the tooth was restored with temporary filling. Discoloration of tooth & intra oral sinus was also found on the labial surface of maxillary left central incisor tooth. Radiography showed a radiolucent area around the apex and a fractured instrument was wedged at the apex of the maxillary left central incisor. The affected tooth was then treated as removal of fractured instrument followed by root canal treatment.

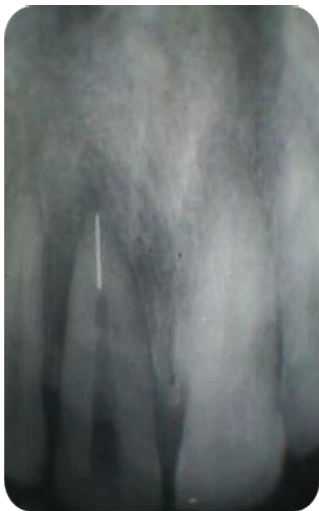

Fig.1 : Radiograph showing a fractured central incisor Instrument wedged in root apex of Maxillary left

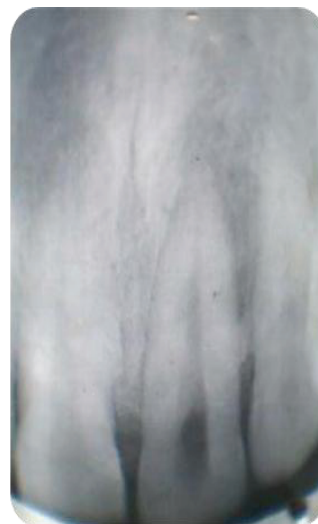


Fig.2 : Radiograph showing successful removal of the fractured instrument




Fig.3 : Radiograph showing fractured instrument. The length of fractured instrument was approximately 5 mm

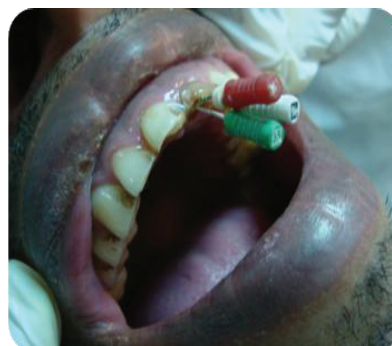

Fig.4 : File Braiding Technique

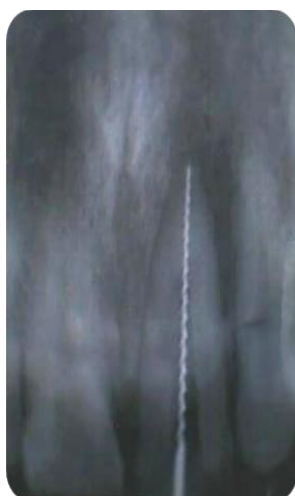

Fig.5 : Measurement of working length

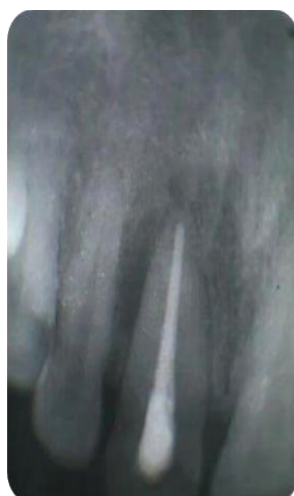

Fig. 6 : Final radiograph showing obturated canal

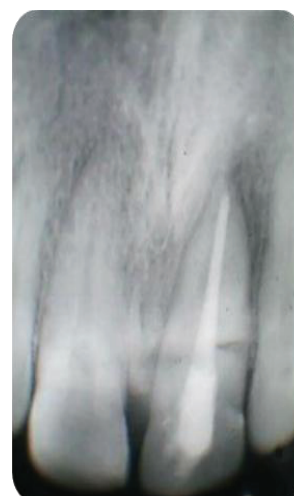

Fig. 7 : 3 months follow up

Clinical Procedure:

1st Visit:

The temporary filling was removed. An attempt was made to retrieve the fractured instrument. To retrieve the fragment, canal was irrigated with 2.5% sodium hypochlorite, and 15% EDTA was used. Initially one H-file was used to bypass the broken tip, followed by another H-file which was inserted gradually. Then under copious irrigation these files were rotated in order to grasp and pull out the fragment (Fig - 4). Repeating this procedure engaged the fragment and it was withdrawn. A radiograph was taken to confirm its complete removal (Fig - 2).

After confirmation of working length (Fig- 5), the root canal was prepared in accordance with the standardized technique .0.02 taper stainless steel instruments were used. Filing was continued in a sequential manner with copious irrigation in between two files. Recapitulation was done. Calcium hydroxide dressing was placed.

2nd Visit:

Removal of Calcium hydroxide, obturation was done using Gutta-percha with lateral condensation method and Zinc-oxide sealer. A final radiograph was taken and was kept under observation (Fig - 6).

Recall Visit:

After three months follow up, the tooth was asymptomatic with radiographic healing of periapical tissue (Fig - 7).

Discussion

Intra canal separation of instruments usually prevents access to the apex, impedes thorough cleaning and shaping of the root canal, thus may compromise the outcome of endodontic treatment and reduce the chances of successful

retreatment.^{2,9} In such cases, prognosis following an endodontic therapy depends on the condition of the root canal (vital or non vital), tooth (symptomatic or asymptomatic, with or without periapical pathology), amount of cleaning and shaping at the time of separation, the level of separation in the canal and is generally lower than the one with normal endodontic treatment.²

Although various techniques and devices for retrieving the fragment have been described, no standardized procedure for the successful removal of broken instrument in the root canal exists.^{9,10} Each individual case may require a different approach depending on various factors like tooth anatomy, size of fragment, location of fragment etc. Instrument fragment retrieval can be tried starting with the simplest and least invasive method like using endodontic files along with copious irrigation as was used in this case.

There are various factors that may contribute to the successful management of fractured instruments within root canals. The success rate in maxillary teeth is found to be higher than that in mandibular teeth.¹¹ Degree of curvature is another factor that influences the successful management of broken instruments. Stainless steel instruments are the most resistant to breakage. Studies have shown that NiTi instruments fractured mostly in canals with severe curvature. The success rate of removal was lower in severe curvatures.^{11, 12} Location of the fragment in the canal is another factor. Fragments located before the root canal curvature were removed completely.¹³ The length of fragment also tends to affect the success rate. Fragments shorter than 5 mm present the lowest success rate.¹⁰

Among the various methods used for broken instrument retrieval, one is chemical method using chemical agents like iodine trichloride, nitric acid, hydrochloric acid and sulfuric acid etc. These methods may help in achieving intentional corrosion of the metal objects, but could be irritant to the periapical tissues when extruded through the apical foramen.⁹ Although use of Masserann kit has shown successful

results for fragment removal^{14, 15}, it requires a large loss of root canal dentin, thus could result in perforation or fracture of narrow roots. In addition, it has high risk of perforation in apical part of root canal.⁹ Braiding is a simple technique that can be used to remove pieces of fractured instrument or silver point from deeper in the root canal system. The first Hedstroem file is gently screwed into the canal alongside the object, and two further Hedstroem files are then gently inserted. These files are then wound around each other and withdrawn together (Figs. 4). The object should be gripped by the files and removed.

In this case, two hedstroem files under copious irrigation with 15% EDTA and sodium hypochlorite were used. The two files were braided and the instrument fragment was grasped and pulled out which is similar to previously tried procedures.¹⁶ EDTA a chelating agent, is helpful as a lubricant.¹⁷ Studies have shown that if it is possible to bypass the instrument then there are greater chances of removal.¹⁸ In my case, the fragment could be bypassed. The removal of the broken instrument from a root canal must be performed with a minimum damage to the tooth and supporting tissues.¹⁶ Thus, this method was employed which lead to successful removal of the fragment with least amount of damage to the tooth and surrounding tissues.

Suter et al¹² found no relationship in terms of the failure rate with the location of the fractured instrument within the root canal in their study. Fors and Berg¹⁴ suggested that objects in the apical third should be left in situ because attempts to remove can result in root perforation thus reducing the prognosis of the root canal treatment. In certain clinical situations it may also be better to leave a fractured instrument in the root canal. For example, when the instrument fractures in a canal with a vital pulp towards the end of the cleaning and shaping phase or if it fractures when removing a calcium hydroxide dressing in an uncomplicated case.¹⁹

In the case described, the tooth have an obvious periapical lesion, so the instrument would not have been left in situ without attempting the

removal because the fracture occurred at few years ago and it may had been contaminated during treatment procedure . However, One should realize that the broken instrument itself is not a direct cause of treatment failure but rather an indirect one, because it may have prevented cleaning, shaping and filling of the apical portion of the root canal. Therefore, the therapeutic goal is either to retrieve the fractured instrument or to bypass it in order to get access to the uncleaned portion of the canal. Successful treatment depends on proper debridement and disinfection of the root canal system, along with removal of the fractured instrument and preventing reinfection by way of a good-quality coronal restoration.

Conclusion

Prevention of file separation is always more desirable than attempted removal. Adhering to proven concepts, integrating best strategies, and utilizing safe techniques during root canal preparation procedures will virtually eliminate the broken instrument procedural accident. This case report has described a conservative and simple technique for removal of fractured instruments from the canal. To begin with, the simplest and easily available technique must be the goal.

References

1. Kerekes K, Tronstad L: Long-term results of endodontic treatment performed with a standardized technique. *J Endod.* 1979;5(3):83-90.
2. Arcangelo CM, Varvara G, Fazio P.D. Broken instrument removal – two cases, *J Endodon* 2000 ; 26 : 568 – 70.
3. Nagai O, Tani N, Kayaba Y, Kodama S, Osada T. Ultrasonic removal of broken instruments in root canals. *International Endodontic Journal* 1986;19: 298–304.

4. Ward JR, Parashos P, Messer HH (2003a) Evaluation of an ultrasonic technique to remove fractured rotary nickel–titanium endodontic instruments from root canals: an experimental study. *Journal of Endodontics* 2003a; 29: 756–63.
5. Souter NJ, Messer HH. Complications associated with fractured file removal using an ultrasonic technique. *Journal of Endodontics* 2005;31: 450–2.
6. Ruddle CJ: Microendodontic nonsurgical retreatment, in *Microscopes in Endodontics, Dent Clin of North Am* 41:3, pp. 429-454, W.B. Saunders, Philadelphia, July 1997.
7. Ruddle CJ: Ch. 25, Nonsurgical endodontic retreatment. In Cohen S, Burns RC, editors: *Pathways of the Pulp*, 8th ed., Mosby, St. Louis, pp. 875-929, 2001.
8. Freidman S, Stabholz A, Tamse A. Endodontic retreatment : case selection and techniques part 3. Retreatment techniques. *J. Endodon* 1990 ; 16 : 543-9.
9. Hulsmann M. Methods for removing metal obstruction from the root canal. *Endod DentTraumatol*1993;9:223-37.
10. Hulsmann M, Schinkel I. Influence of several factors on the success or failure of removal of fractured instruments from the root canal. *Endod Dent Traumatol* 1999;15:252–258.
11. Shen Y, Peng B, Cheung GS: Factors associated with the removal of fractured NiTi instruments from root canal systems. *Oral Surg Oral Med Oral Pathol Oral Radiol Endod.* 2004;98(5):605-10.
12. Suter B, Lussi A, Sequeira P. Probability of removing fractured instrument from root canals. *Int Endod J* 2005;38:112-123.
13. Hulsmann M: Removal of silver cones and fractured instruments using the Canal Finder System. *J Endod.* 1990;16(12):596-600.
14. Fors UGH, Berg JO. Endodontic treatment of root canals obstructed by foreign objects. *Int Endod J* 1986;19:2-10.
15. Stock CJ, Nehammer CF: Negotiation of obstructed canals; bleaching of teeth. *Br Dent J.* 1985;158(12):457-62.
16. Gilbert BO Jr, Rice RT: Re-treatment in endodontics. *Oral Surg Oral Med Oral Pathol Oral Radiol Endod.* 1987;64(3):333-8.
17. Stewart GG: Chelation and flotation in endodontic practice: an update. *J Am Dent Assoc.* 1986;113(4):618- 22.
18. Gutmann JL, Dumsha TC, Lovdahl PE. *Problem Solving in Endodontics* 4th ed. St. Louis, Missouri: Mosby, 2006p267-72.
19. Rocke H, Guldener PHA (1993) Obstruktion des Wurzelkanals. In: Guldener PHA, Langeland K, eds. *Endodontologie*, 3rd edn. Stuttgart: Thieme, pp. 293–312.