

## CASE REPORT

### Bilateral double mandibular canal-a case report

\* Shoma Banik<sup>1</sup>, Samir Banik<sup>2</sup>, Mushfiq Hassan Shaikh<sup>3</sup>, Parimol Chandra Mallick<sup>4</sup>, Abdul Gofur<sup>5</sup>, Manjur - E- Mahmud<sup>6</sup>

<sup>1</sup> Assistant Professor & Head, Department of Oral and Maxillofacial Surgery, Update Dental College & Hospital, Dhaka.

<sup>2</sup> Lecturer, Department of Dental Radiology and Imaging, Dhaka Dental College Hospital, Dhaka.

<sup>3</sup> Assistant Professor & Head, Department of Periodontology and Oral Pathology, Update Dental College & Hospital, Dhaka

<sup>4</sup> Assistant Professor & Head, Department of Dental Radiology and Imaging, Dhaka Dental College, Dhaka.

<sup>5</sup> Lecturer, Department of Dental Pharmacology, Dhaka Dental College, Dhaka.

<sup>6</sup> Dental Surgeon, Upazilla Health Complex, Loha Gara, Chittagong.

#### ARTICLE INFO

##### Article history:

Received: 20 January, 2011

Accepted : 08 March, 2012

##### Keywords:

Cone beam computed tomography,  
Double mandibular canal

#### ABSTRACT

**Objectives:** The objective is to draw attention to the anatomical variation of mandibular canal (double mandibular canals).

**Methods:** This case report showing clinical and radiographic findings of a patient who was presented with bilateral double mandibular canals were recorded.

**Results:** Bifid or double mandibular canals can be detected on a panoramic radiograph. More precise information about the course of the canal can be revealed on CBCT scan.

**Conclusions:** The detection of these bifid or double mandibular canals are important because of their clinical implications. Special attention has to be made in the surgical procedures, especially involving the lower jaw.

#### Introduction

The mandibular canal transmits the inferior alveolar vessels and inferior alveolar nerve, which is a branch of the 3<sup>rd</sup> division of the trigeminal nerve, extending from the mandibular foramen to the mental incisive region. Dental and incisive branches of the inferior alveolar nerve exit the canal to supply teeth and adjacent structures while a terminal branch exits the canal at the mental nerve.<sup>1</sup> Radiographically the mandibular canal appears as a dark, linear shadow with thin, radiopaque superior and

inferior borders casted by the lamella of bone that bounds. The knowledge of the course of the mandibular canal and its anatomical variations is of a great importance in certain surgical interventions involving the mandible.<sup>2,3</sup> Dental panoramic radiography and computed tomography have been used to identify the prevalence of bifid or double mandibular canal.<sup>2</sup> Failure to identify anatomical variations can complicate surgery and result in adverse consequences.<sup>4</sup>

\* Address of Correspondence:

**Dr. Shoma Banik**  
Assistant Professor & Head  
Department of Oral & Maxillofacial Surgery  
Update dental college & hospital.  
Telephone: +8801716088792  
E-mail: sbanik@yahoo.com

### Case Report

A 52 years old male was referred to the department of Dental Radiology and imaging department at Dhaka Dental College and Hospital to assess the suspected bony invasion due to oral ulceration by routine panoramic radiograph. However, a unilateral duplicated mandibular canal was suspected at the left side, where the oral ulceration was located. To confirm the suspicion, the Cone Beam Computed Tomography (CBCT) scan was performed on the both sides. It revealed that the patient having advanced generalized periodontitis. Periapical lesion and tooth erosion was also been noted in few teeth. Cortical erosion was also found in left mandibular ramus area.

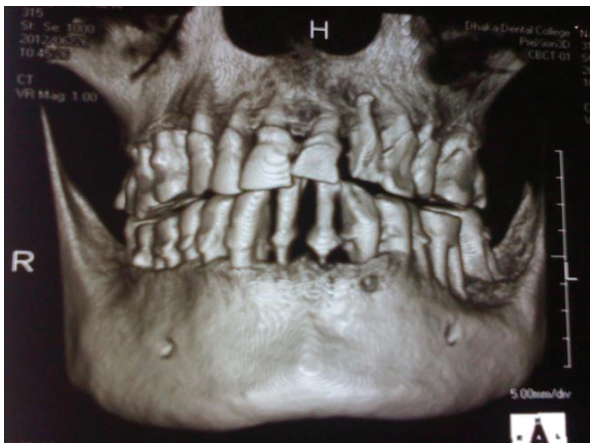

Fig.1 :- 3D, CT image, anterior view.

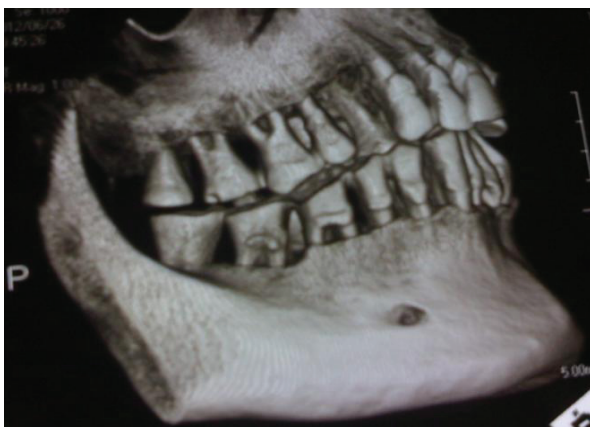

Fig.2 :- 3D, CT image, right side of mandible

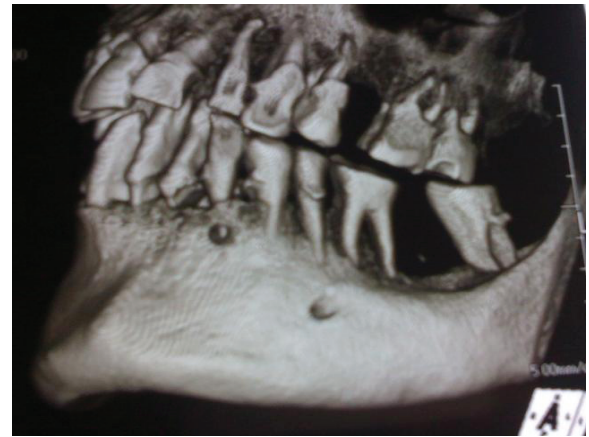

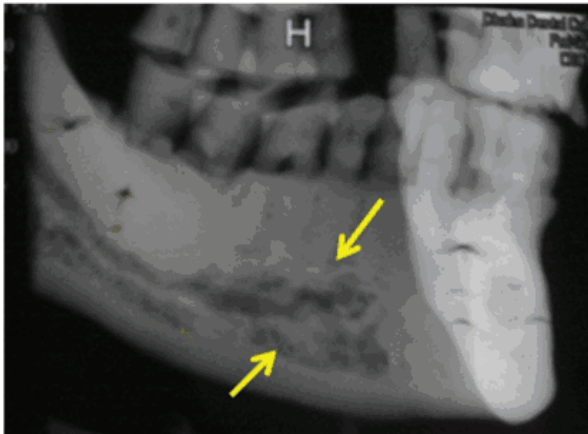
Fig.3 :- 3D, CT image of left side of mandible

Surprisingly, the CBCT scan showed bilateral double mandibular canal with single mental foramen in both sides of the mandible. After considering the panoramic radiograph and CBCT scan we concluded that the patient had bilateral double mandibular canals. Afterwards, the patient was informed of the presence of this anatomical variation.

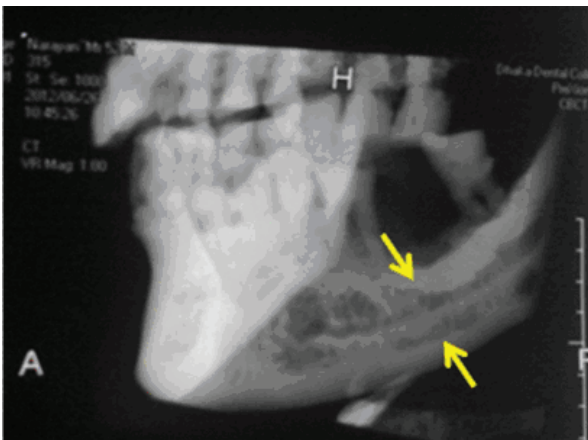
### Discussion

It is important to take extreme care, while the 3rd molar surgery has to be carried out, especially, when there are presence of bifid mandibular canals in the molar region. The tooth may infringe on or be within the canal itself. As a second neurovascular bundle may be contained within the bifid canals, as a result, complications may arise, such as traumatic neuroma, paraesthesia, and bleeding due to failure to recognize the abnormality and its implications.<sup>1</sup> Double mandibular canals may be associated with increased difficulty in obtaining inferior alveolar nerve block. Whereas anesthesia of the soft tissue around the injection site, but not the ipsilateral lip and chin, may be an indication of local anesthesia failure. Anesthesia of the lips and chin, but not the teeth, may indicate the presence of a bifid or double mandibular canals<sup>2</sup>. In cases of trauma, all mandibular fracture should be handled with care to ensure precise alignment of the neurovascular bundle to avoid impingement when the fracture is healed and

alignment of fragments becomes much more difficult in cases where a second neurovascular bundle is located in a different plane<sup>2</sup>. Bilateral double mandibular canal is less common anatomical variation. This condition may cause complications when performing mandibular anesthesia or mandibular surgery<sup>3</sup>.

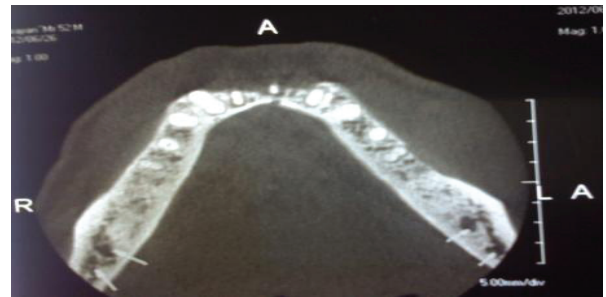


**Fig.4 :- Lingual aspect (let side) two canal.**

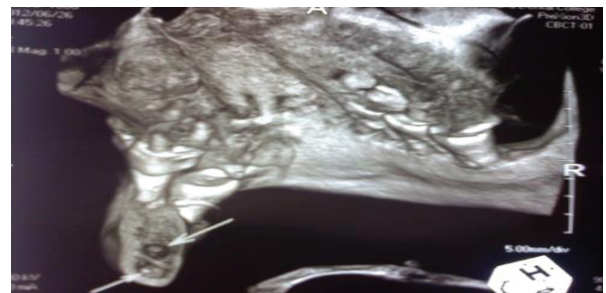


**Fig.5 :- Lingual aspect (Right side) two canal.**

Surgery of the patient with such anatomical structure abnormalities may cause haemorrhage, impair the surgeon's visibility. It may also increase the potential of fibrous tissue formation at the site of the content with the implant.<sup>4</sup>

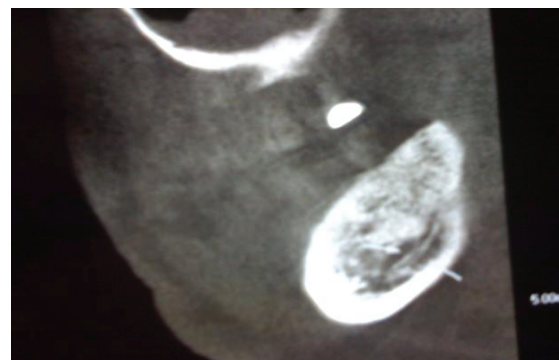


**Fig.6 :- Two canal seen in 3D image.**



**Fig.7 :- Two canal seen in axial image.**

The location and course of double mandibular canal and accessory mental and buccal foramina are also important for implant related bone grafting.



**Fig.8 :- Two canal seen in sagittal image.**

Bifid mandibular canal may cause pain and discomfort in patients with mandibular prosthesis due to additional pressure placed on the neurovascular bundle<sup>6</sup>.

### Summary

Bifid mandibular canals are less commonly present in the general population. Most of the time they remain unrecognized, even though they can be recorded in panoramic radiographs. However, the CBCT scan provides the best information regarding the mandibular canal and its precise course. The main purpose of this case report is to call attention to an apparently harmful anatomical variation with clinical importance, which can cause complications when surgery has to be performed in the lower jaw.

### References

1. V Calaeys , G Wackens : Bifid mandibular canal : literature review and case report , Dentomaxillofacial Radiology (2005) 34, 55-58
2. Kaan Orhan , Secil Aksoy, Burak Bilecenoglu, Bayram vfuk sabul , Candan semra Paksoy : Evaluation of Bifid mandibular canals with cone beam computed tomography in a turkish adult population : A retrospective study . Surg. Radiol. Anat (2001) 33 : 501 -507
3. Sura A. Rashid , Jamal Ali , Lamia Al Makib : Identification of bifid mandibular canals among Iraqi Subjects using panoramic imaging system. J Bagh College Dentistry Vol. 23(4), 2011.
4. Kaufman , N J Serman , P D Wang . Bilateral mandibular Accessory foramina and canals : A case report and review of the literature . Dentomaxillofacial Radiology (2000) 29, 170-175.
5. Munetaka Naitoh , Kino Nakahara , Yutaka Suenaga , Kenichi Gotoh , Shinataro Kondo , Eiichiro Arijii , Comparison between cone beam and multislice computed tomography depicting mandibular neuro vascular canal structures . Oral Surg, Oral Med, Oral Pathol, Oral Radio endod 2010;109
6. Wadhvani P, Mathur RM , Kohli M et al (2008) Mandibular Canal Variant : A case report. J Oral Pathol Med 37: 122-124.