

## Review Article

### Preformed crowns – A successful approach to restore primary teeth:

\* Iqbal Bahar<sup>1</sup>. S.M. Abdul Quader<sup>2</sup>. Md. Ali Afzal Khan<sup>3</sup>. K.M. Rawnak jahan<sup>4</sup>. Md.Asif Iqbal Khan<sup>5</sup>

<sup>1</sup> Senior lecturer, Dept of Paediatric Dentistry, Update Dental College and Hospital

<sup>2</sup> Assistant Professor, Dept of Conservative Dentistry, Update Dental College and Hospital

<sup>3</sup> Assistant Professor, Dept of Science of Dental Materials, Update Dental College and Hospital

<sup>4</sup> Senior lecturer, Dept of Paediatric Dentistry, Update Dental College and Hospital

<sup>5</sup> Associate Professor, Dept of Paediatric Dentistry, Sapporo Dental College and Hospital

#### ARTICLE INFO

##### *Article history:*

Received : 01 June 2011

Accepted : 30 September 2011

##### *Keywords:*

Preformed crown (P.C),  
restorations.

#### ABSTRACT

Preformed crowns are indicated for restoring severely decayed/ pulpally treated primary teeth since early 1940s. Although the composition of Preformed Crowns varies from manufacturer to manufacturer, the preparation of teeth and manipulation technique for seating of Preformed Crowns (PC) on primary teeth would not invite much disagreement among different authors and operators. Available literature readily accepts that when used with a proper cementing agent such as Resin-Modified Glass Ionomer (RMGI) luting cement, preformed crown remain a superior and durable treatment option for primary teeth. This review article supports using preformed crowns for restoring critically damaged primary teeth until a suitable alternative is available.

The literature discussing Preformed crowns of the present day comes largely involving different populations of patients, different makes of P.C's, varying clinical conditions, luting cements and a multitude of operators. Although the quality of some of the literature may not meet modern day expectations, it is still valuable data which tends to support the longevity and cost-effectiveness of a restorative technique that has been available since the 1940s. Removal of dental caries followed by placement of a preformed crowns with restoration using an adhesive material or indeed no treatment but a conclusion was reached that preformed crowns may last longer than fillings for carious deciduous teeth. All reported study results have been in agreement that P.C's outperform plastic restorations when used to restore multisurface carious lesions in primary teeth. The Cochrane review called for well controlled clinical trials to appropriately test the efficacy of the preformed crowns. It may, however, be difficult to attain ethical approval to test a restorative technique that has shown extremely favorable success rates in all studies cited. It would be very difficult to justify restoring a deciduous teeth requiring a large multisurface restoration with an alternative material, or leaving it untreated in order to compare this to primary teeth restored with preformed crowns. These should continue to be used to restore the deciduous primary teeth.

\* *Address of Correspondence:*

##### **Dr.Iqbal Bahar**

Senior lecturer, Dept of Paediatric Dentistry,

Update Dental College and hospital

Telephone: +880711577775

E-mail: iqbal\_baharos@yahoo.com

## Introduction:

The restoration of primary teeth has been challenging for decades due to the small size of the primary teeth, close proximity of the pulp to the tooth surface, relatively thin enamel for bonding, issues related to child behavior and finally cost of the treatment. It is essential to restore crowns destroyed by carious lesion to preserve the integrity of primary dentition until it's natural exfoliation and eruption of permanent teeth. The morphology of a primary teeth differs significantly from it's succeeding permanent one , in part by having it's greatest convexity at the cervical third of the crown. To match up with this morphological variation , preformed crowns design- modifications have improved the morphology of the crown so that it more accurately duplicates the anatomy of the primary teeth as well as have made the fitting procedure simple . Preformed crowns are prefabricated crown forms which can be adapted to individual primary teeth and are cemented in place to provide a definitive restoration. The preformed crown margin is flexible enough to spring into and be retained by the undercut areas made on the tooth. The purpose of this article is to review the various options available for restoring the primary teeth and enhance the clinician's ability to make the best choice of selection of preformed crowns for each individual case.

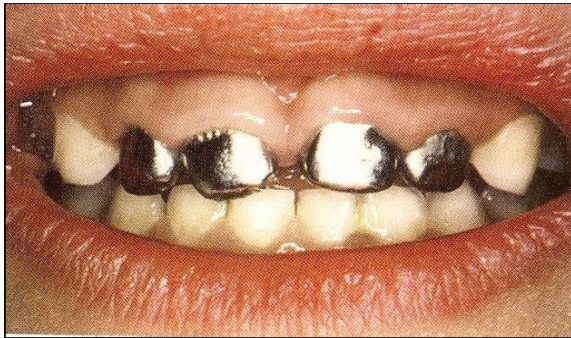
## Indications:

Preformed crowns are the restoration of choice in the following situations:

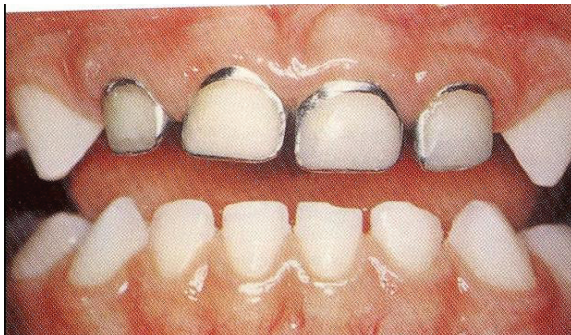- a. Restoration of carious primary teeth where more than two surfaces are affected, or where one or two surface carious lesions are extensive.
- b. Following Pulpotomy or Pulpectomy procedures.
- c. Restoration of primary teeth affected by localized or generalized developmental problems. e. g. enamel hypoplasia, amelogenesis.
- d. Restoration of fractured primary teeth.
- e. Restoration and protection of teeth exhibiting extensive tooth surface loss due to attrition, abrasion or erosion.
- f. In patients with a high caries susceptibility.
- g. As an abutment for certain appliances, such as space maintainers.
- h. In patients where routine oral hygiene measures are impaired e.g. patients with special needs, and breakdown of intra-coronal restorations is likely.
- i. In patients undergoing restorative care under general anaesthesia where more surfaces are involved.
- j. In patients with infra-occluded primary molars to maintain mesio-distal space.

## Preformed crowns commercially available to restore primary teeth :

- **Intra Coronal Restoration**
  - Direct
  - Indirect
- **Full Coronal Restoration**
  - **Luted:**
    - Stainless steel with facing
    - Cheng crowns
    - Kinder crowns
    - Nu-smile
    - Dura-crowns
    - Whiter bite
    - Pedo pearls
    - Ceromo-basemetalchilder
  - **Bonded:**
    - Polycarbonate
    - Strip crowns
    - Pedo jacket
    - New millnium
    - Glstech



**Fig. 01: Stainless Steel Crowns**



**Fig. 02: Modification of Stainless Steel**



**Fig. 03: Strip Crown**



**Fig. 04: Pado Jacket**

Appropriate local analgesia should be obtained and the tooth should be isolated, preferably with rubber dam. Caries removal and appropriate

**Clinical procedure:**

pulp treatment (i.e. indirect pulp capping, pulpotomy or pulpectomy) should be completed if necessary. Appropriate tooth preparation should be carried out, which should include sufficient occlusal or incisal reduction to avoid significant premature contact, and approximal reduction to allow the crown to be seated beyond the maximum bulbosity (Cervical Prominence) of the crown. Occlusal/incisal reduction should follow the contours of the tooth. The preparation should finish with a smooth feather edge cervically with no step or shoulder. The preparation should be rounded off with no sharp line angles. Where a primary tooth has no adjacent tooth either mesially or distally it is still important to carry out approximal reduction to avoid producing an excessive marginal overhang. This is particularly important on the distal surface of second primary molars where such overhangs can impede the eruption of the first permanent molar. Buccal and lingual preparation is not always necessary and may be detrimental to retention.

**Selection criteria & guideline:**

A crown should be selected that is a tight snap fit. Choosing the correct size is assisted by measuring the mesio-distal dimension of the tooth, or contra lateral tooth, with dividers or a graduated periodontal probe. The degree of adjustment necessary to achieve a satisfactory fit is dependant upon the make of crown used. Preformed crowns have little or no cervical contouring and hence routinely require modification. If the crown is excessively long, the crown margin may impede complete seating, in which case crown length may be adjusted by trimming with crown shears and re-smoothing and polishing the edges with an abrasive stone. Although it has been customary to recommend trimming of crowns where gingival blanching occurs, there is no evidence that this practice reduces post cementation complications<sup>1</sup>.

Manufacturers recommend the preformed crowns finishes about 1mm below the gingival margin. Over trimming of the crown margin should be avoided, as this may affect retention if it results in reduced adaptation of the crown margin into undercut areas. It is essential that the margins of the crown are well adapted into undercut areas, which is usually achieved by crimping of the crown edges. Care should be taken not to cause iatrogenic damage to adjacent teeth or unerupted teeth. Frequently, reduction in the mesio-distal dimension of the crown will be necessary, especially where mesial drift (often due to caries) has resulted in loss of arch length. Moderate reduction in mesio-distal dimension can be achieved by flattening of the mesial and distal contact areas of the crown with Adam's pattern pliers. Excessive occlusal interference should be avoided (greater than 1.0–1.5 mm), but a slightly premature or high occlusal contact up to about 1.0 mm is normally well tolerated in children. The crown should be cemented with a luting cement; Glass ionomer, zinc polycarboxylate and zinc phosphate cements are all suggested by manufacturers, although fluoride-leaching cements may have additional benefits. There is, however, some evidence suggesting that the specific choice of cement does not significantly affect retention, the most important retentive components being derived from correct contouring and crimping of the crown. Careful attention should be paid to removal of excess cement. This can usually be effectively achieved by running a pointed instrument around the margins of the cemented crown and by passing knotted dental floss bucco-lingually through the contact areas prior to the cement setting.

### **Cementation:**

P.Cs need a generous mix of cement to adequately fill the crown space prior to seating.<sup>2,3,5</sup> There may be some resistance to seating the crown, however, it is recommended that the crown be first seated over the lingual or buccal wall and rolled over onto the opposite wall,<sup>6,9,11</sup> which will also help to minimize damage to the crown margin. Once seated onto the prepared tooth, the crown should be maintained under pressure while the cement sets.

Excess cement should be seen to extrude from around the entire crown margin<sup>9</sup> and this is removed after setting. Removal of excess cement from the contact area is facilitated by means of a length of dental floss or tape with a single knot tied in it.<sup>3,5,6,8,9,10,11,12,13</sup> Croll has suggested removal of excess set resin-modified glass ionomer (RMGI) cement by means of an ultrasonic scaler.<sup>10,12</sup> Over the time period of the literature surveyed, different authors have recommended various cements, for example, zinc phosphate,<sup>4,7,8,9</sup> fast setting zinc oxide<sup>4,6,8</sup> and polycarboxylate.<sup>3,6,7,9,11,12,13,14,15</sup>

### **Complication:**

The general advice from the literature was that the use of rubber dam is preferred.<sup>3,5,6,8,9,11,13,15</sup> Difficulties may arise if the tooth being prepared for a pre.crown is the tooth to be clamped. In this instance, it is suggested that all necessary tooth preparation, except for the distal reduction, be carried out under rubber dam. The distal slice and crown fitting are then completed after rubber dam removal.<sup>3</sup> The amount of occlusal reduction obtained can be checked by comparison with neighboring teeth.<sup>9</sup> More and Pink recommended cutting the interproximal portions of the dam to prevent entanglement of the bur in these areas.

### **Risks:**

#### **Periodontal concerns:**

A number of studies have reported on the gingival health of primary teeth restored with P.Cs. Goto reported the incidence of gingivitis in primary teeth restored with nickelchromium crowns. He found the percentage of gingivitis associated with a crown to be higher in the posterior part of the mouth than the anterior and to be more strongly associated with poor fitting crowns. He did not report the incidence of gingivitis in control teeth.<sup>20</sup>

#### **Nickel allergy:**

One paper was traced regarding nickel sensitization associated with P.Cs. Feasby et al,

reported an increased nickel-positive patch test result in children

8 to 12 years of age who had received old formulation nickel-chromium crowns. A second group of children with conventional stainless steel crowns showed no statistically significant difference in patch test responses compared to a third control group with no history of nickel-containing dental appliance use.

*494 Randall Preformed metal crowns Pediatric Dentistry – 24:5, 2002*, The nickel content in the discontinued formulation nickel chromium crowns was around 70%, significantly greater than that of contemporary stainless steel crowns for posteriors, which contain 9%-12% nickel, similar to that of many orthodontic bands and wires.<sup>21</sup>

### Summery

Over the last decades, it has been found that preformed crowns are best bonded into place with resin-modified glass ionomer luting cement.<sup>16</sup> Such cements are biocompatible, form a chemical bond to tooth structure and have high physical strengths and insolubility in the mouth. Properly adapted crowns forms luted with resin-modified glass ionomer cement do not detach. One might argue that, with such high quality luting cement, precise marginal adaptation is not critical. Because children do not often show irreversible consequences from pre.crowns that is not perfectly adapted, is it worth the extra effort to adapt crown margins so carefully? It is important to remember that the methods described. The principles for adapting posterior crown forms can also be applied to fitting and finishing marginal areas of primary canine teeth and incisor crowns.<sup>17-19</sup> For the smallest of the anterior crown forms, alteration of the crimping pliers may be useful so that the tips fit internally.

### Conclusion

Over the last decades, it has been found that preformed crowns are best bonded into place with resin-modified glass ionomer luting cement.<sup>16</sup> Such cements are biocompatible, form a chemical bond to tooth structure and have high

physical strengths and insolubility in the mouth. Properly adapted crowns forms luted with resin-modified glass ionomer cement do not detach. It is important to remember that the described methods and principles for adapting posterior crown forms can also be applied to fitting and finishing marginal areas of primary canine teeth and incisor crowns<sup>17-19</sup>. For the smallest of the anterior crown forms, alteration of the crimping pliers may be useful so that the tips fit internally. Until a suitable alternative arrives in the horizon preformed crowns remain the best option for restoring a severely damaged primary tooth.

### References:

1. UK National Clinical Guidelines in Paediatric Dentistry: stainless steel preformed crowns for primary molars. S. A. KINDELAN, P. DAY, R. NICHOL, N. WILLMOTT & S. A. FAYLE Department of Paediatric Dentistry, Leeds Dental Institute, University of Leeds, Leeds UK; pp 20-23.
2. Full CA, Walker JD, Pinkham JR. Stainless steel crowns for deciduous molars. *JADA*. 1974;89:360-364.
3. Duggal MS, Curzon MEJ, Fayle SA, Pollard MA, Robertson AJ. *Restorative Techniques in Paediatric Dentistry*. 1st ed. London: Martin Dunitz; 1995.
4. Mink JR, Bennett IC. The stainless steel crown. *J Ont Dent Assoc*. 1968;45:420-430.
5. Goldberg NL. The stainless steel crown in pediatric dentistry. *Dent Digest*. 1969;75:351-355.
6. More FG, Pink TC. The stainless steel crown: A clinical guide. *J Mich State Dent Assoc*. 1973;55:237-242.
7. Page J. Stainless steel crowns for posterior teeth. *Proc Br Paedodont Soc*. 1973;3:21-24.
8. Myers DR. The restoration of primary molars with stainless steel crowns. *ASDC J Dent Child*. 1976; 43:406-409.

9. Nash DA. The nickel-chromium crown for restoring posterior primary teeth. *JADA*. 1981;102:44-49.
10. Croll TP, Riesenberger RE. Primary molar stainless steel crown restoration. *Quintessence Int*. 1986;17:221-226.
11. Duggal MS, Curzon MEJ. Restoration of the broken down primary molar: 2. Stainless steel crowns. *Dent Update*. 1989;16:71-75.
12. Croll TP. Preformed posterior stainless steel crowns: An update. *Compendium*. 1999;20:89-104.
13. Fayle SA. UK national guidelines in paediatric dentistry. *Int J Paediatr Dent*. 1999;9:311-314.
14. Fieldman BS, Cohen MM. A simple efficient method for utilizing the stainless steel crown. *ASDC J Dent Child*. 1979;46:464-469.
15. Roberts JF. The open-faced stainless steel crown for primary molars. *ASDC J Dent Child*. 1983;50:262-263.
16. Croll TP. Preformed stainless steel crowns: an update. *Compend Contin Educ Dent*. 1999;20:89-106.
17. Croll TP, Blum JR. The stainless steel crown for a primary canine tooth: a pictorial essay. *J Pedod*. 1982; 6:301-314.
18. Croll TP, Helpin ML. Preformed resin veneered stainless steel crowns for primary incisor restoration. *Quintessence Int*. 1996;27:309-313.
19. Croll TP. Primary incisor restoration using resin-veneered stainless steel crowns. *J Dent Child*. 1998;65:89-95.
20. Goto G, Imanishi T, Machida Y. Clinical evaluation of preformed crown for deciduous teeth. *Bull Tokyo Dent Coll*. 1970;11:169-176.
21. Feasby WH, Ecclestone ER, Grainger RM. Nickel sensitivity in pediatric dental patients. *Pediatr Dent*. 1988;10:127-129.