

Case Report

Orthodontic camouflage management of a class II malocclusion with excessive overjet- A case report

*Naznin Sultana¹, Md. Nazmul Hasan², Gazi Shamim Hassan³, Mir Abu Naim⁴, Nasrin Akther⁵.

¹Assistant professor, Department of Orthodontics, Udayan Dental College, Rajshahi.

²Assistant professor & Head, Department of Orthodontics & Dentofacial Orthopedics, Update Dental College & Hospital, Dhaka

³Chairman, Department of Orthodontics, faculty of dentistry, BSMMU, Dhaka.

⁴FCPS Trainee, Department of Orthodontics, faculty of dentistry, BSMMU, Dhaka.

⁵Medical Officer, Department of Orthodontics, faculty of dentistry, BSMMU, Dhaka.

ARTICLE INFO

Article history:

Received : 17 October 2012

Accepted : 11 March 2013

Keywords:

Orthodontic camouflage,
Class II div 1 malocclusion,
Extraction,
supernumerary tooth

Abstract:

In orthodontic practice various treatment modalities have been presented for the treatment for the class II, div 1 malocclusions. Recently a large number of young adults have been seeking shorter, cost effective and a non surgical correction of Class II malocclusions and they accept dental camouflage as a treatment option to mask the skeletal discrepancy. This case report presents one such case, a 15 years old growing male who has Class II div I malocclusion with severe maxillary incisor proclination, convex profile, high mandibular plane angle, incompetent lips, increased overjet & overbite, over retained upper left deciduous canine, impacted upper left canine and a supernumerary tooth in canine region. We considered the camouflage treatment by extracting the upper right first premolar, left impacted canine, deciduous canine and supernumerary tooth. Following the treatment, a satisfactory result was achieved with an ideal, static and a functional occlusion, facial profile, acceptable smile, competent lip and stable treatment results.

Introductions:

Malocclusion compromises the health of the oral tissues and it can also lead to psychological and social problems.¹ The classical features of the class II, div 1 malocclusion include a mild to severe class II skeletal base with an Angles

class- II molar relation and class II canine and incisor relations, proclined maxillary incisors and an increased overjet and it generally has a convex profile with incompetent lips.² The treatment planning of the class II, non growing patients is challenging and controversial. A class II malocclusion is commonly seen in the orthodontic practice, with a frequency of 14% among children who are between 12 and 14 years of age.³ Its management frequently involves use of myofunctional appliance in

Corresponding Authors:

Dr. Naznin Sultana

BDS, FCPS, Assistant professor,

Department of Orthodontics,

Udayan Dental College, Rajpara, Rajshahi

Phone: +88-0171514454

Email : dear.naznin7@yahoo.com

growing patient & camouflage treatment with extraction either two or all premolars. If it is severe in adults surgical treatment is recommended. Patient generally has convex profile & incompetent lip.⁴This case report illustrates an adolescent male patient with angles Class II div 1 malocclusion treated with extraction of upper right the first premolar and upper left impacted canine, upper left deciduous canine and supernumerary tooth.

Report of the cases:

A 15 year old boy came to The Department of Orthodontics, BSMMU with the complaint of proclination of upper teeth. The main concern expressed by his family was his facial appearance. Family history was positive as his father had same problem. The patient had an increased visibility of the upper anterior teeth. The profile of the patient was convex, with a posterior facial divergence. The nasolabial angle was normal, with potentially competent lip. The patient showed a good range of mandibular movements and no TMJ symptoms. Intraoral examination revealed that the patient had a full Class II molar and canine relationship, a excessively

proclined maxillary incisors with an overjet of 15mm, over bite of 9mm and associated palatal impingement of the lower incisors. There was a slight upper midline shift to right, over retained upper left deciduous canine, absent upper left canine, and a supernumerary tooth in canine region. The left lateral incisor was rotated and slight crowding in lower jaw. On model analysis tooth width discrepancy was seen in both jaw, 5mm in upper arch and 6mm in lower arch.

The panoramic radiograph showed the presence of all the third molars, the impacted upper left canine, retain deciduous canine and the supernumerary tooth. There were no pathological findings. Cephalometric tracing illustrated SNA angle of 86 degree, SNB angle of 78 degree, ANB angle of 8 degree and inter incisor angle of 104 degree, IMPA angle of 85 degree, FMIA angle of 58 degree, FMPA angle of 37 degree. Occlusal view shows horizontal impaction of upper left canine. The patient was diagnosed as a skeletal and dental class II division 1 malocclusion.




Figure 1: Extraoral photograph shows pretreatment resting lip posture (a), lip posture during smile (b), profile (e) and post treatment resting lip posture (c), lip posture during smile (d), profile (f).

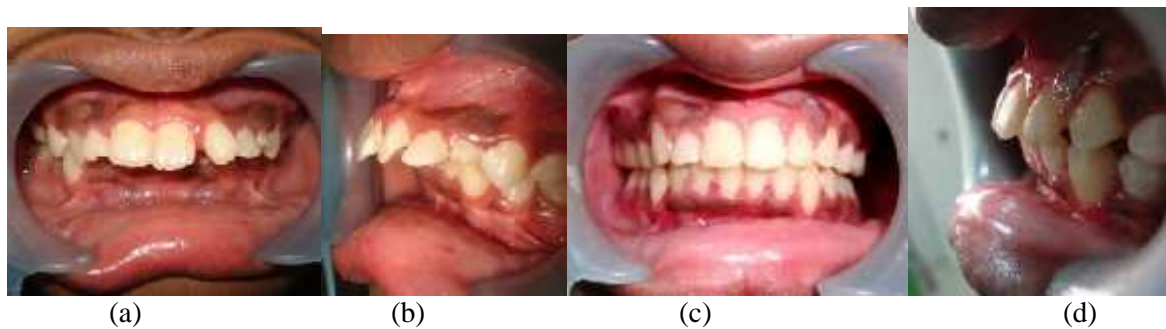


Figure 2: Intraoral photograph shows pre-treatment frontal view (a), left lateral view (b) and post-treatment frontal view (c), left lateral view (d). Marked reduction of overjet and correction of deep bite is noticed.

Treatment goal was set with an objective to improve overall hard tissue and soft tissue profile with improvement of facial aesthetics which included correction of proclined upper incisors, competent lips, flat occlusal plane, correction of midline and functional occlusion with proper intercuspation of teeth with class II molar relation and class I canine relation. The treatment plan included Extraction of the maxillary right first premolar, upper left impacted canine, upper left retain deciduous canine and supernumerary tooth, Alignment and leveling of the arches, Leveling the curve of Spee, Closing the extraction space by canine retraction followed by incisor retraction, Final consolidation of the space and Settling of the occlusion.

Treatment was started with fixed appliance (preadjusted edge wise 0.018'') in the upper and lower arches. At first, extraction of retain deciduous canine was done. Initial leveling was accomplished with the use of 0.014'' niti wire over 4 months. After initial leveling, extraction of upper right 1st premolar, left impacted canine and supernumerary tooth was done. After extraction, a compressed coil spring was applied to retract upper right canine with 0.016'' stainless steel archwire over 5 months. Then anterior retraction was done with 0.017''x 0.025'' stainless steel archwire over 5 months.

After anterior retraction, class-II elastic was given for 8 months. The remaining extraction space was closed by anchorage loss. After 24 months (from the time of placing full appliances) all teeth were aligned, the extraction space was closed and midline discrepancy corrected. After satisfactory interdigitation was achieved, following which the case was debonded and a fixed upper and lower lingual bonded retainer was given.

The overall result of the orthodontic treatment was good as the arches were well aligned. Normal overbite - 3.5 mm and overjet 2.5 mm were established and midline was corrected. The face profile was straight, lip was competent, the gummy smile was corrected with 1mm of gingival display at the end of treatment. The cephalogram showed marked improvement in the skeletal pattern. At the time of debonding both the patient and his parents were satisfied with the outcome.

DISCUSSION:

The goal of dental camouflage is to correct the skeletal relationships by orthodontically repositioning the teeth in the jaws, so that there is an acceptable dental occlusion and an aesthetic facial appearance. Considering the tooth tissue discrepancy to manage such case is an important pretreatment consideration.⁵ Age of

the patient would not be a decelerating factor for treatment success to those case.⁶The possibilities for the treatment in this patient were to displace the teeth which were relative to their supporting

bone and to compensate for the underlying jaw discrepancy.

Table I: Pre and Post treatment cephalometric findings

	Variable	Pre-treatment	Post-treatment
Skeletal	SNA	86°	83°
	SNB	78°	77°
	ANB	8°	6°
	Wits(AO-BO)	12mm	9mm
	GoGn-SN	32°	22°
Dental	U1-SN	125°	114°
	U1- NA	40°/8mm	33°/11mm
	L1 - NB	27°/9mm	37°/11mm
	IMPA	85°	115°
	Overjet	15mm	3.5 mm
Soft-tissue	Nasolabial angle	78°	110°
	U lip-S line	5 mm	0 mm (Just touching)
	L lip-S line	6 mm	3 mm



Figure 3: Lateral cephalometric tracing shows the change of skeletal pattern change from pre treatment(a) to post treatment(b).

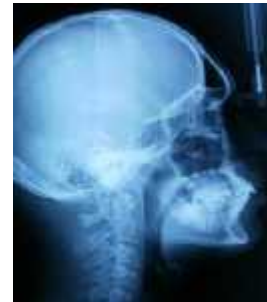
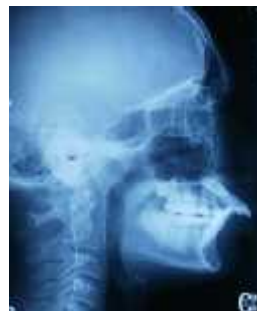
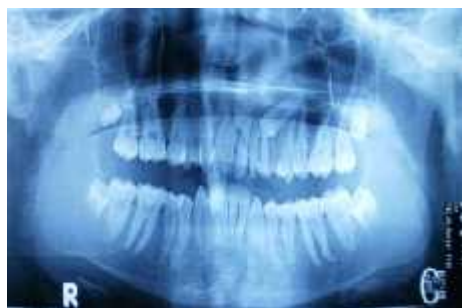Figure 4: Patients pre treatment oral panoramic radiograph (OPG), (a), lateral cephalometric radiograph (b) and post treatment lateral cephalometric radiograph shows marked improvement of occlusions.

The displacement of the teeth, as in the retraction of the protruding incisors, is often termed as camouflage.⁷ In this case, a surgical treatment was rejected by the patient and it was decided to hide the skeletal discrepancy by extracting the maxillary right premolar, left impacted and deciduous canines, supernumerary tooth and retracting the anterior teeth to improve the profile of the patient and to obtain a proper functional occlusion. This resulted in dental, skeletal and accompanying soft tissue profile changes.

Treatment time was 27 months .Patients had improved smile & Profile. Upper incisors were retracted to achieve normal incisor angulations, overjet& overbite. Lips became competent and lower lip controlled upper incisors successfully, which is very important for incisor stability in class II division 1 malocclusion .The upper and lower dental midlines coincided. After 3 months follow-up, the occlusion was still same.

CONCLUSION:

Dental camouflage orthodontic treatment could be a very important alternative method of managing malocclusion rather than through conventional way of approach. Managing such way would be a much more effective clinical way to solve complex malocclusions

Acknowledgement:

We would like to express our special thanks to Dr. MahamoodSajedeem, Assistant professor, and Dr. DigamberJha, MS Resident from the Department. of Orthodontics, BSMMU for their valuable help and co-operations.

Referances:

1. Proffit WR. The etiology of orthodontic problems. In: Proffit WR, Field HW, Sarver DM (eds). Contemporary Orthodontics. 5th ed. St Louis: Mosby, Inc., 2013, pp. 114-145.
2. Dale JG, Dale HC. Interceptive guidance of occlusion with emphasis on diagnosis. In: Graber LW, Vanarsdall RL, Vig KWL (eds). Orthodontics current principles and techniques. 5thed. Philadelphia: Mosby, Inc., 2012, pp. 429-430.
3. Naragond A, Kenganal S, Sagarkar R, Sugaradday. Orthodontic Camouflage Treatment in Adult Patient of Class II division 1 Malocclusion – Case Report, Journal of Clinical and Diagnostic Research. 2013;7(2): 395-40
4. Naik VR. Management of Class II div I malocclusion- A case report, International Journal of Clinical Dental Science, 2010; 1(1):70-72
5. Hasan MN, Chowdhury SS, Khan MAA, Taleb A, Abid MMA. “Tooth-size Discrepancy” –an important diagnostic tool to measure the outcome of Orthodontic Treatment Completion: A Review. Bangladesh Journal of Dental Research & Education, 2011; 1(1): 27-29.
6. Hasan MN, Quader SMS, Khan MAA, Hossain MM. Could ‘Age’ be a potential decelerating factor in clinical orthodontics. Update Dental College Journal, 2012;2(2):51-55.
7. Proffit WR, Sarver DM, Ackerman JL. Orthodontic Diagnosis: the problem-oriented approach. In: Proffit WR, Field HW, Sarver DM (eds). Contemporary Orthodontics. 5th ed. St Louis: Mosby, Inc., 2013, pp. 150-219