

Case Report

The Radix Entomolaris : Non-surgical Approach in Endodontics

*Shirin Sultana Chowdhury,^a S.M. Abdul Quader^a.

^aAssistant Professor, Dept of Conservative Dentistry and Endodontics, Update Dental College & Hospital, Dhaka, Bangladesh

ARTICLE INFO

Article history:

Received : 21 November 2012
Accepted : 17 March 2013

Keywords:

Anatomical variations,
Non-surgical endodontic treatment,
Mandibular molar,
Radix entomolaris.

Abstract :

Mandibular molars often have an additional root located lingually (the radix entomolaris) or buccally (the radix paramolaris). If present, an awareness and understanding of this unusual root and its root canal morphology can contribute to the successful outcome of root canal treatment. This report discusses endodontic treatment of a mandibular molar with a radix entomolaris, which is a rare macrostructure. The prevalence, the external morphological variations and internal anatomy of the radix entomolaris are described. Avoiding procedural errors during endodontic therapy demand an adapted clinical approach to diagnosis and successful non-surgical endodontic treatment.

Introduction:

The prevention or healing of endodontic pathology depends on a thorough chemo mechanical preparation of the root canals before a dense three- dimensional obturation of the canals. An awareness and understanding of the presence of unusual root canal morphology can thus contribute to the successful outcome of root canal treatment.

*Address of Coresspondence

Shirin Sultana Chowdhury

Assistant Professor, Dept of Conservative
Dentistry and Endodontics, Update Dental
College, Turag, Dhaka-1711.
Telephone: 01716435598
E-mail: shumi1177n@gmail.com

It is known that the mandibular first molar can display several anatomical variations. The majority of first molars are two-rooted with two mesial and one distal canal. ^{1,2} In most cases the mesial root has two root canals, ending in two distinct apical foramina. Or, sometimes, these merge together at the root tip to end in one foramen. The distal root typically has one kidney-shaped root canal, although if the orifice is particularly narrow and round, a second distal canal may be present. ³ A number of anatomical variations have been described in the mandibular first molar reported the presence of three mesial canals ⁴⁻⁶ and the presence of three distal canals. ⁷ Like the number of root canals, the number of roots may also vary. An additional third root, may found either lingually or buccally of the main distal root. When it lies lingually is called

the radix entomolaris(RE).^{8,9} An additional root at the mesiobuccal side is called the radix paramolaris. The identification and external morphology of these root complexes, containing a lingual or buccal supernumerary root, often create problem in non-surgical management resulting an uncertain treatment outcome.^{10, 11} Although both macrostructures are rare in our population, knowledge of their occurrence and location are important. In this report such a case is presented. The prevalence, external morphological variations and internal anatomy of the radix entomolaris are described. The clinical approach to diagnosis and endodontic treatment are also discussed and illustrated.

Case Report

A 24-year-old -male was referred for endodontic treatment of the mandibular right first molar before the replacement of a large amalgam restoration with a ceramic crown. The tooth was free of symptoms and but radiographical examination revealed a signs of

chronic apical periodontitis. The pulp chamber was opened, and one distal and two mesial canal orifices were located using an endodontic explorer. The root canals were explored with a K-file ISO 15 (Dentsply Maillefer, Ballaigues, Switzerland) and radiographical length measurement was performed with no. 20 reamers {Fig.2(b)}. Upon visual inspection a dark line was observed between the distal canal orifice and the distolingual corner of the pulp chamber floor and the distal canal orifice was also not at the middle but a little bit buccal side of the chamber. At this corner overlying dentin was removed with a diamond bur with a noncutting tip (MANI,INC.Tochigi,Japan) and a second distal canal orifice was detected .The root canals were shaped with ProTaper hand instruments (Dentsply Maillefer ,Ballaigues, Switzerland). During preparation, Glyde (Densply Maillefer ,Ballaigues, Switzerland)) was used as a lubricant and the root canals were disinfected with a sodium hypochlorite solution (2.5%).

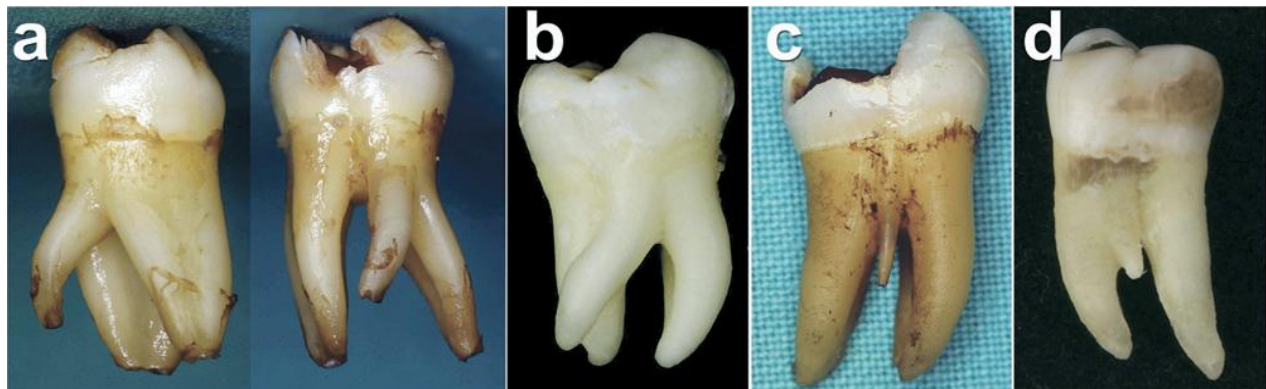


Figure 1. Clinical images of extracted mandibular molars with a radix entomolaris or paramolaris. (A) first molar with a radix entomolaris [distolingual view (left), lingual view (right)]. (B) radix entomolaris on a third molar (lingual view). (C) first molar with a separate radix paramolaris (buccal view). (D) first molar with a fused radix paramolaris (buccal view).

Initially, the distolingual root canal was thought to be a second canal in one distal root. Radiographically the outlines of the distal root(s) were unclear; however, the unusual location of

the orifice far to the disto-lingual indicated a supernumerary root, and the presence of an Radix Entomolaris was confirmed on the postoperative radiograph (Fig. 2d). The root

canals were filled with standardized gutta-percha and Zinc-oxide-eugenol sealer by lateral condensation technique. The cavity was sealed with Silver-Tin-Amalgam cement (ANA 2000,

Sweden) and the patient was referred to the Prosthodontist for restoration by permanent restoration as full veneer crown.

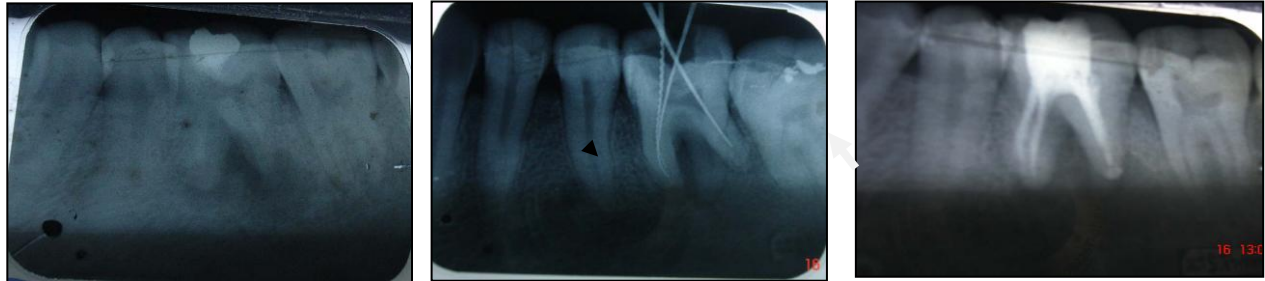

Figure 2. (A) Preoperative radiograph (b) Length determination radiograph, where the RE is visualized (Demarked).

(c) Postoperative radiograph. (d) Postoperative radiograph after 6 months with the radix entomolaris (demarcated) in the mesio-distal side can be distinguished when a radiograph is exposed 30 degrees from the mesial plane.

Discussion

The presence of a separate RE in the first mandibular molar is associated with certain ethnic groups. In African populations a maximum frequency of 3% is found¹², while in Eurasian and Indian populations the frequency is less than 5%.¹³ In populations with Mongoloid traits (such as the Chinese, Eskimo and American Indians) reports have noted that the RE occurs with a frequency that ranges from 5% to more than 30%.¹⁴⁻²⁰ Because of its high frequency in these populations, the RE is considered to be a normal morphological variant (eumorphic root morphology). In Caucasians the RE is not very common and, with a maximum frequency of 3.4 to 4.2%^{21, 22}, is considered to be an unusual or dysmorphic root morphology. In average, frequency of additional root is about 10.1%, where an extra distal root is on lingual aspect.²³ The etiology behind the formation of the RE is still unclear. In dysmorphic,

supernumerary roots, its formation could be related to external factors during odontogenesis, or to penetrance of an atavistic gene or polygenetic system (atavism is the reappearance of a trait after several generations of absence).^{19, 24} An RE can be found on the first, second and third mandibular molar, occurring least frequently on the second molar.²⁵ Some studies report a bilateral occurrence of the RE from 50 to 67%.^{18, 26} The RE is located disto-lingually, with its coronal third completely or partially fixed to the distal root. The dimensions of the RE can vary from a short conical extension to a 'mature' root with normal length and root canal. In most cases the pulpal extension is radiographically visible.

The presence of an RE or an RP has clinical implications in endodontic treatment. An accurate diagnosis of these supernumerary roots can avoid complications or a 'missed canal' during root canal treatment. Because the (separate) RE is mostly situated in the same bucco-lingual plane as the disto-buccal root, a superimposition of both roots can appear on the preoperative radiograph, resulting in an inaccurate diagnosis. A thorough inspection of the preoperative radiograph and interpretation of

particular marks or characteristics, such as an unclear view or outline of the distal root contour or the root canal, can indicate the presence of a 'hidden' RE. To reveal the RE, a second radiograph should be taken from a more mesial or distal angle (30 degrees). This way an accurate diagnosis can be made in the majority of cases.

Apart from a radiographical diagnosis, clinical inspection of the tooth crown and analysis of the cervical morphology of the roots by means of periodontal probing can facilitate identification of an additional root. An extra cusp (tuberculum paramolare) or more prominent occlusal distal or disto-lingual lobe, in combination with a cervical prominence or convexity, can indicate the presence of an additional root. The location of the orifice of the root canal of an RE has implications on the opening of the cavity. The orifice of the RE is located disto to mesio-lingually from the main canal or canals in the distal root. Visual aids such as a loupe, intra-oral camera or dental microscope can in this respect be useful. A dark line on the pulp chamber floor can indicate the precise location of the RE canal orifice. The distal and lingual pulp chamber wall can be explored with an angled probe to reveal overlying dentin or pulp roof remnants masking the root canal entrance. The calcification, which is often situated above the orifice of the RE, has to be removed for a better view and access to the RE.

However, to avoid perforation or stripping in the coronal third of a severe curved root, care should be taken not to remove an excessive amount of dentin on the lingual side of the cavity and orifice of the RE.

The use of flexible nickel-titanium rotary files allows a more centered preparation without unexpected complications as instrument separation. Therefore, after relocation and enlargement of the orifice of the RE, initial root

canal exploration with small files (size 10 or less) together with radiographical root canal length and curvature determination, and the creation of a glide path before preparation, are step-by-step actions that should be taken to avoid procedural errors.

Conclusion

Clinicians should be aware of these unusual root morphologies in the mandibular first molars. The initial diagnosis of a radix entomolaris before root canal treatment is important to facilitate the endodontic procedure, and to avoid 'missed' canals. Preoperative periapical radiographs exposed at two different horizontal angles are required to identify these additional roots. Knowledge of the location of the additional root and its root canal orifice will result in a modified opening cavity with extension to the disto-lingual. The morphological variations of the RE in terms of root inclination and root canal curvature demand a careful and adapted clinical approach to avoid or overcome procedural errors during endodontic therapy as well as in prevention of post operative complications.

References

1. Barker BC, Parson KC, Mills PR, Williams GL. Anatomy of root canals. III. Permanent mandibular molars. *Aust Dent J* 1974;19:403–13.
2. Vertucci FJ. Root canal anatomy of the human permanent teeth. *Oral Surg Oral Med Oral Pathol* 1984;58:589–99.
3. Thoden Van Velzen SK, Wesselink PR, De Cleen MJH. *Endodontologie*, 2nd ed. Bohn Stafleu Van Loghum, Houtem/Diegem, 1995:142–3.
4. Fabra-Campos H. Unusual root anatomy of mandibular first molars. *J Endod* 1985;11:568–57.
5. Fabra-Campos H. Three canals in the mesial root of mandibular first permanent molars: a clinical study. *Int Endod J* 1989;22:39–43.
6. Bond JL. Clinical management of middle mesial root canals in mandibular molars. *J Endod* 1988;14:312–4.

7. Stroner WF. Mandibular first molar with three distal canals. *Oral Surg* 1984;57:554–7.
8. Carabelli G. *Systematisches Handbuch der Zahnheilkunde*, 2nd ed. Vienna: Braumuller und Seidel, 1844:114.
9. Bolk L. Bemerkungen über Wurzelvariationen am menschlichen unteren Molaren. *Zeitung für Morphologie und Anthropologie* 1915;17:605–10.
10. Carlsen O, Alexandersen V. Radix entomolaris: identification and morphology. *Scan J Dent Res* 1990;98:363–73.
11. Carlsen O, Alexandersen V. Radix paramolaris in permanent mandibular molars: identification and morphology. *Scan J Dent Res* 1991;99:189–95.
12. Sperber GH, Moreau JL. Study of the number of roots and canals in Senegalese first permanent mandibular molars. *Int Endod J* 1998;31:112–6.
13. Tratman EK. Three-rooted lower molars in man and their racial distribution. *Br Dent J* 1938;64:264–74.
14. Pedersen PO. The East Greenland Eskimo dentition. Numerical variations and anatomy. A contribution to comparative ethnic odontography. Copenhagen: Meddeleserom Gronland 1949;104:140–4.
15. Turner CG 2nd. Three-rooted mandibular first permanent molars and the question of Am Indian origins. *Am J Phys Anthropol* 1971;34:229–41.
16. Curzon MEJ, Curzon AJ. Three-rooted mandibular molars in the Keewatin Eskimo. *J Can Dent Assoc* 1971;37:71–2.
17. Yew SC, Chan K. A retrospective study of endodontically treated mandibular first molars in a Chinese population. *J Endod* 1993;19:471–3.
19. Reichart PA, Metah D. Three-rooted permanent mandibular first molars in the Thai. *Community Dent Oral Epidemiol* 1981;9:191–2.
20. Walker T, Quakenbush LE. Three rooted lower first permanent molars in Hong Kong Chinese. *Br Dent J* 1985;159:298–9.
21. Curzon ME. Three-rooted mandibular permanent molars in English Caucasians. *J Dent Res* 1973;52:181.
22. Ferraz JA, Pecora JD. Three-rooted mandibular molars in patients of Mongolian, Caucasian and Negro origin. *Braz Dent J* 1993;3:113–7.
23. Gulabivala K, Aung TH, Alavi A, Ng YL. Root and canal morphology of Burmese mandibular molars. *Int Endod J* 2001;34:359.
24. Ribeiro FC, Consolaro A. Importancia clinica y antropologica de la raiz distolingual en los molars inferiores permanentes. *Endodoncia* 1997;15:72–8.
25. Visser JB. Beitrag zur Kenntnis der menschlichen Zahnwurzelformen. *Hilversum: Rotting* 1948;49–72.
26. Steelman R. Incidence of an accessory distal root on mandibular first permanent molars in Hispanic children. *J Dent Child* 1986;53:122–3.