

Case Report

Cone-Beam Computed Tomography for managing impacted canine in orthodontics.

*Md. Nazmul Hasan,^a Shirin Sultana Chowdhury,^b S. M. Abdul Quader.^b

^aAssistant Professor & Head, Department of Orthodontics & Dentofacial Orthodontics, Update Dental College & Hospital, Dhaka

^bAssistant Professor, Department of Conservative Dentistry & Endodontics, Update Dental College & Hospital, Dhaka

ARTICLE INFO

Article History:

Received : 1 August 2013

Accepted : 17 September 2013

Key Words:

Cone beam computed tomography,
Impacted canine

Abstracts:

Radiographic interpretation and diagnosis of dental impactions have always posed a great challenge to the orthodontist to manage such case. This could largely be attributed to the limitations posed by the conventional two-dimensional (2D) imaging modalities. Dental impactions, which can position into various underlying locations, can be evaluated accurately using cone beam computed tomography (CBCT) three-dimensional (3D) imaging, rather than conventional 2D radio-imaging. This article report a case of orthodontic management of impacted canine of a 13 years old boy where conventional 2D radio-imaging diagnosis are modified by cone beam computed tomography (CBCT).

Introductions:

The maxillary canine is one of the most frequently impacted teeth, second only to the third molar.¹The mandibular canine is 10 times less likely to be impacted compared with the maxillary canine. Upper canine traveled a long path before eruptions, which makes it more venerable for impactions. The prevalence of impacted maxillary canine has been reported with palatal locations 85% of the time and a labial location of 15% of the time.² Management of impacted canine is one of the most challenging problems for orthodontist,

because of its long treatment duration through orthodontic approach, that often require increase number of patient's visits, patients co-operations, and orthodontist proper pre-treatment evaluation and management approach. Decision of pulling of such impacted teeth and placing them into the arch could be taken by proper pretreatment occlusion and tooth discrepancy evaluation.³ However decision of approaching such impacted teeth either by palatally or labially totally depends on pretreatment clinical diagnosis. Conventionally this decision is taken by evaluating the case clinically then radiologically by lateral cephalometry, panoramic radiograph (OPG), and by occlusal radiograph. All those radiograph are two dimensional representation of a three dimensional objects. Distortion of image may occur due to superimposition of surrounding structure,⁵ resulting wrong clinical interpretation. At present the most popular 3D radio imaging used in orthodontics and other branches of dentistry is Cone-Beam Computed Tomography (CBCT). The first dedicated CBCT

*Address of Corresponding

Md. Nazmul Hasan

Assistant Professor & Head, Department of Orthodontics & Dentofacial Orthodontics, Update Dental College & Hospital, Dhaka.

Telephone: +880 18 17 09 77 48

E-mail: nazmul2246@yahoo.com

scanner for oral and maxillofacial region was described in 1998.⁵ However in our country the first use of CBCT for maxillofacial imaging has been incorporating since last year.

In this article we are going to describe a case of impacted canine required to manage orthodontic approach the decision of which was greatly modified by the CBCT imaging.

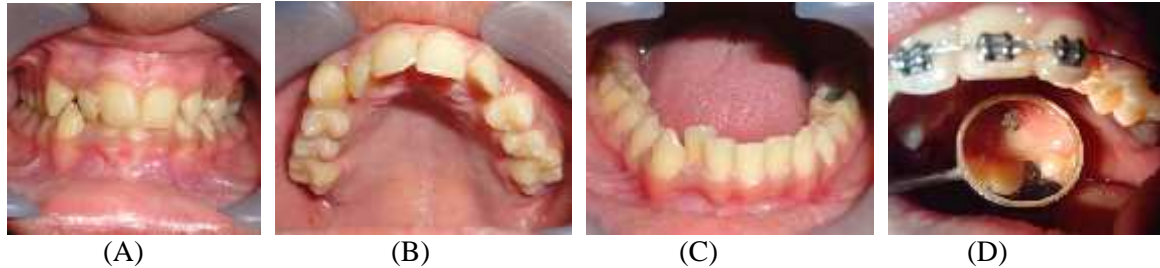

Figure 1: Intraoral pre-treatment photograph of the patients, frontal view(A), upper occlusal view (B), lower occlusal view (C) and post surgical bonded bracket canine crown (D).

Report of the Case:

A 13-years-old boy has been reported in a private dental office of Dhaka; with complain of irregularities in his teeth. On clinical examinations concave face profile without any history of medical illness has been revealed. On intraoral examinations class I molar relations with crowding on lower anterior segment and anterior deep bite with increased overbite was recorded. Upper left canine was missing resulting spacing on upper left side without shifting the dental midline. [Figure 1(A),(B),(C)] On radiological examination with routine panoramic radiograph (OPG) and lateral cephalometry [Figure 2(A)&(B)] upper left canine were diagnosed as impacted. Comparing with intraoral bony bulging on left vestibule on the mouth over the edentulous area and the radiological finding comparing the crown of impacted canine that pose labial direction compare to adjacent lateral incisor, the crown of that impacted canine were suspected to located on labial direction. The treatment planning was formulated initial leveling of incisor that will crates room for the canine, then surgical exposure of canine and orthodontic pull out of canine to occlusion.

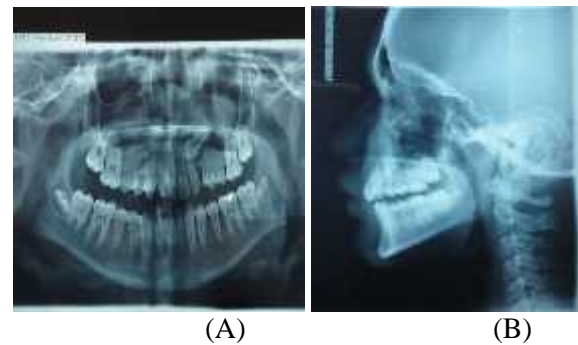


Figure 2: Pretreatment radiograph OPG (A), Lateral Cephalometry (B).

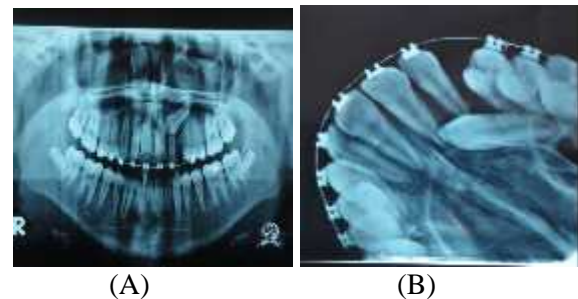


Figure 3: Pre-surgical position evaluations by OPG(A), and occlusal view of maxilla (B).

After the initial stage of leveling with stander edge-wise technique 0.018×0.025 bracket, the room for canine was created and up-righting of upper left incisor was done. It was suspected that the up-righted root of lateral incisor will push the crown of that impacted canine more labial position, which will make an easy access for surgical exposure of canine. However after initial leveling of teeth another panoramic radiograph with an occlusal view of maxilla

radiograph [Figure 3(A)&(B)] were advised to formulate the canine's position. Then comparing those extraoral and intraoral radiographs the canine crown was suspected to be located in labial direction that became opposite to the initial assessment. Then before approaching surgically the impacted canine's crown, it was required to be confirmed by more accurate radio-imaging. Meanwhile the radiology department of Dhaka Dental College & Hospital, (the only public funded full dental hospital in Bangladesh) has integrated with a new CBCT machine. Then we refer our patients to that department to have a CBCT imaging for confirming the canine crown position.

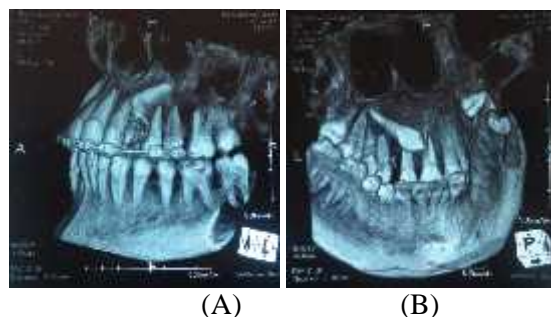


Figure 4: CBCT evaluations of impacted tooth left buccal view (A), inferior palatal view (B). After confirming the canine crown position palatally by CBCT [Figure:4(A)&(B)] then we access to that crown with surgical exposure by retracting palatal flap. Bracket was then bonded on the canine's crown. Canine was pull to occlusion with regular gentle orthodontic force.

Discussions:

Traditionally, the position of the impacted canine has been assessed in two dimensions: mesial/distal and buccal/palatal. A studie have shown that 2-D imaging using panoramic x-rays is not a reliable method for localization of impacted canines, nor is it reliable in determining the extent of possible root resorption of adjacent teeth.⁶ For more accurate localization, the position of the canine should be determined in three dimensions. CT scan can also record the hard tissue pathology like impacted tooth locations more accurately rather than conventional 2D radiograph. However the amount of radiations dose received by the conventional 2D radio-imaging is much less

than the amount received by conventional medical CT scan. CBCT is a widely accepted tool in orthodontics and numerous studies have reported the accuracy, reliability, and repeatability of CBCT images.⁷ However, the use of CBCT and patient exposure to radiation has raised a concern, especially with adolescents. Several studies have determined that effective radiation exposure with CBCT technology is significantly lower than conventional multi-slice CT scans used in medicine. In comparison to conventional dental imaging, effective CBCT doses are much higher; however, new technology has allowed CBCT exposure to be adjusted.

In our present study we have tried the every possible conventional method of radio imaging to locate the actual position of canine crown. However more invasive technique like conventional medical CT scan also locates the actual position however will result in excessive radiations exposure. Compare to that one CBCT remain the best possible options to manage such case more accurately.

Conclusions:

The three dimensional CBCT based hard and soft tissue simulations, photographic intrigrations, superimpositions of lateral cephalometry will more accurately investigate the patents data for orthodontic assessment, comparing to conventional two dimensional radio-imaging techniques.

References:

1. Grover PS, Lorton L. The incidence of unerupted permanentteeth and related clinical cases. *Oral Surg OralMed Oral Pathol.* 1985; 59:420-425.
2. Ericson S, Kurol J. Resorption of maxillary lateral incisors caused by ectopic eruption of the canines. *Am J Orthod Dentofac Orthop.* 1988; 94:503-513.
3. Hasan MN, Chowdhury SS, Khan MAA, Taleb A, Abid MMA. "Tooth-size Discrepancy" –an important diagnostic tool to measure the outcome of Orthodontic Treatment Completion: A Review. *Bangladesh Journal of Dental Research & Education,* 2011; 1(1): 27-29.
4. Bodner L, Bar-Ziv J, Becker A. Image accuracy of plainfilm radiography and computerized tomography in assessingmorphological

- abnormality of impacted teeth. *Am J Orthod Dentofac Orthop.* 2001;128:623-628.
5. Mozzo P, Procacci C, Tacconi A, Martini PT, Andreis IA. A new volumetric CT machine for dental imaging based on the cone-beam technique: preliminary results. *Eur Radiol.* 1998; 8:1558-1564.
 6. Farronato G, Bellincioni F, Colombo M, Falzone D, Sara S, Passaler G, et al. CBCT in orthodontics. *CAD/CAM.* 2012; 2: 26-29
 7. Grauer D, Cevidanes LSH, Styner MA, Heulfe I, Harmon ET, Zhu H, et al. Accuracy and landmark error calculation using cone-beam computed tomography-generated cephalograms. *Angle Orthod.* 2010; 80: 286-94.